

Dual (type IV) left anterior descending artery

O Baskan, MD; E Cengiz, MD; P Yahya, MD

Department of Radiology, Istanbul Medipol University, Istanbul, Turkey

Corresponding author: O Baskan (obaskan@medipol.edu.tr)

Congenital coronary artery anomalies are uncommon. Dual left anterior descending coronary artery (LAD) is defined as the presence of two LADs within the anterior interventricular sulcus (AIVS), and is classified into four types. Type IV is a rarely reported subtype and differs from the others, with a long LAD originating from the right coronary artery (RCA). Dual LAD is a benign coronary artery anomaly, but should be recognised especially before interventional procedures. With the increasing use of multidetector computed tomography (MDCT), it is essential for radiologists to be aware of this entity and the cross-sectional findings.

S Afr J Rad 2013;17(4):145-146. DOI:10.7196/SAJR.959



Dual left anterior descending coronary artery (LAD) is defined as the presence of two LADs within the anterior interventricular sulcus (AIVS): a short LAD that courses and terminates high in the AIVS, and a long LAD that originates from either the LAD proper or from the right coronary artery (RCA), then enters the distal AIVS and courses to the apex.^[1] Type IV can be differentiated from the other types by the long LAD originating from the RCA.

Case report

A 52-year-old man was referred to our hospital for chest pain during exercise. The physical examination and laboratory findings were unremarkable. The patient underwent coronary CT angiography (CTA) for evaluation of coronary artery disease. The CTA showed a short LAD ending high in the AIVS, arising from the left main coronary artery. The major septal perforators and the diagonal branches originated from the short LAD. The long LAD arose from the RCA, after travelling anterior to the pulmonary artery and right ventricle, re-entering the AIVS at the distal part (Fig. 1).

Discussion

Coronary artery anomalies associated with their origin, course and distribution are frequently asymptomatic and have been diagnosed during conventional coronary angiography.^[2] With advances in MDCT technology, it is possible to examine the coronary arteries and heart structures with high spatial and temporal resolution.^[3] The precise course of the coronary arteries may be easier to appreciate with CTA than with conventional angiography because of the omniplanar capability of CT.

The dual LAD is classified as a congenital course anomaly of the coronary artery. Dual LAD has been classified into four types by Spindola-Franko *et al.* (Fig 2).^[1] The incidence of dual LAD in otherwise normal hearts has been reported to range from 0.13%^[2] to about 1.38%.^[1,3] This anomaly is seen relatively often with congenital malformations such as complete transposition of the great arteries and tetralogy of Fallot.^[2]

When a short or hypoplastic LAD is detected, a differential diagnosis should be sought. There may be a long dominant posterior descending branch of the RCA, terminating in the AIVS beyond the apex; a long parallel diagonal branch; or a dual LAD.^[4] Short LAD should not be misdiagnosed as total occlusion and a long LAD should not be misdiagnosed as a conus branch.

In conclusion, coronary CTA is a non-invasive imaging technique using multiplanar reformat and volume rendering images to show complex anatomy and variations of the coronary arteries. The radiologist should be familiar with, and looking for, these conditions during interpretation of coronary CTA imaging.

1. Spindola-Franco H, Grose R, Solomon N. Dual left anterior descending coronary artery: Angiographic description of important variants and surgical implications. *Am Heart J* 1983;105:445-455. [[http://dx.doi.org/10.1016/0002-8703\(83\)90363-0](http://dx.doi.org/10.1016/0002-8703(83)90363-0)]
2. Sajja LR, Farooqi A, Shaik MS, Yarlagadda RB, Baruah DK, Pothineni RB. Dual left anterior descending coronary artery: Surgical revascularization in 4 patients. *Tex Heart Inst J* 2000;27(3):292-296.
3. Erol C, Seker M. The prevalence of coronary artery variations on coronary computed tomography angiography. *Acta Radiologica* 2012;53:278-284. [<http://dx.doi.org/10.1097/RCT.0b013e31822aef59>]
4. Yoshikai M, Kamohara K, Fumoto H, Kawasaki H. Dual left anterior descending coronary artery: Report of a case. *Surg Today* 2004;34(5):453-455. [<http://doi:10.1007/s00595-003-2733-x>]

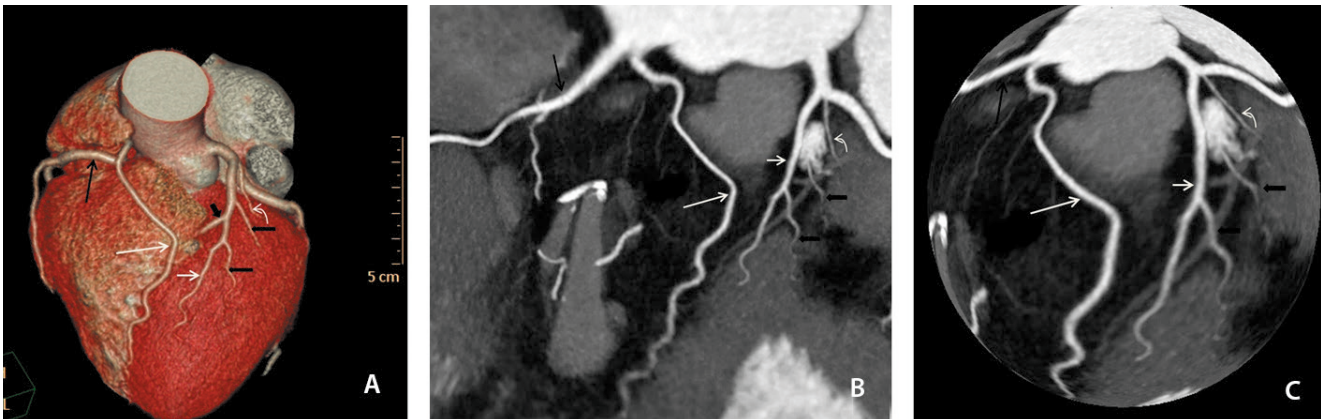


Fig. 1. (A) Three-dimensional volume-rendered (3D-VR) image. (B) Two-dimensional map of the coronary tree. (C) Maximum intensity projection 3D-globe view. Long LAD (long white arrow) has anomalous origin from the right coronary artery (long black arrow) and after travelling anterior to the pulmonary artery and right ventricle, enters the AIVS at the distal part. Short LAD (short white arrow), which terminates high in the AIVS arising from the left main coronary artery. The major septal perforator (short thick black arrow) as well as the diagonal branches (short thin black arrows) originate from this short LAD. Ramus intermedius identified by curved arrow.

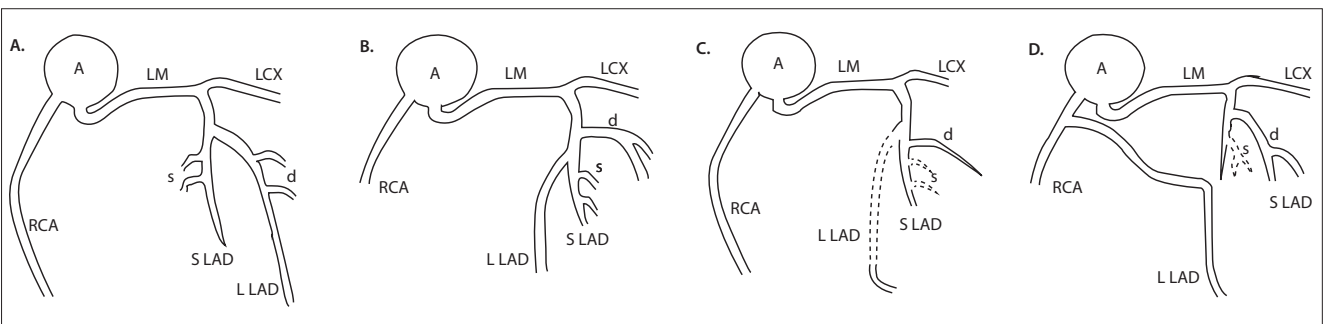


Fig. 2. (A) Type I. The L LAD descends on the left ventricular side of the S LAD then enters the distal AIVS. (B) Type II. The L LAD descends on the right ventricular side of the S LAD and enters the distal AIVS. (C) Type III. The L LAD courses deep within the interventricular septum proximally and appears on the epicardial surface in the distal part of the AIVS. (D) Type IV is characterised by a L LAD originating from the RCA that traverses the right ventricular infundibulum and enters the AIVS. (A = aorta; LAD = left anterior descending coronary artery; L LAD = long LAD; RCA = right coronary artery; S LAD = short LAD; LM = left main coronary artery; s = septal perforator; d = diagonal branches; LCX = left circumflex artery).