

# The Effects of Topical Carvacrol Application on Wound Healing Process in Male Rats

Mehmet Y. Gunal<sup>1</sup>, Aylin O. Heper<sup>2</sup> and Nezahat Zaloglu<sup>3</sup>

<sup>1</sup>Department of Physiology, Faculty of Medicine, Istanbul Medipol University 34810 Istanbul; Turkey

<sup>2</sup>Department of Pathology, Faculty of Medicine, Ankara University 06100 Ankara; Turkey

<sup>3</sup>Department of Physiology, Faculty of Medicine, Ankara University 06100 Ankara; Turkey

## ABSTRACT

Carvacrol containing products such as *Origanum onites* have been used as phytotherapeutic agents in the treatment of serious skin injury. It has been suggested that carvacrol is the active component of these herbs because of its anti-microbial property. With the anti-microbial activity and as an ingredient of these herbs, carvacrol is a promising molecule for the treatment of skin injury. In the present study, we have evaluated the efficacy of carvacrol on healing progress after excisional skin injury. Here, Wistar-Albino rats were divided into two groups and treated with carvacrol and vehicle. Carvacrol was administrated topically at a concentration of %12.5 for the 5 consecutive days after excisional skin injury. Tissue samples were harvested on days 3<sup>rd</sup>, 8<sup>th</sup> and 12<sup>th</sup> after injury. Significant beneficial effect of carvacrol was observed at the end of the experiment. In the acute phase of the injury, carvacrol treatment increased tissue granulation and decreased wound depth moderately. These effect of carvacrol was associated with increased TNF- $\alpha$ . However, at the second half of the experiment the elevated level of TGF- $B_1$  was observed as compared with control animals. The level of IL-1 $\beta$  was increased in carvacrol treated animals only on day 8. Here, we provide evidence that carvacrol improves wound healing by regulating pro-inflammatory molecules TNF- $\alpha$ , IL-1 $\beta$  and TGF- $\beta_1$ .

Keywords: carvacrol; wound healing; TNF- $\alpha$ ; IL-1 $\beta$ ; TGF- $\beta_1$ ; aromatic herbs.

## INTRODUCTION

Carvacrol is an essential oil component of aromatic herbs such as *Origanum onites*.<sup>[1-4]</sup> In-vitro and in-vivo studies performed with carvacrol showed that it has diverse effects, including antimicrobial,<sup>[5,6]</sup> antiviral,<sup>[7]</sup> antifungal,<sup>[8-10]</sup> antioxidant,<sup>[11,12]</sup> and antispasmodic.<sup>[13-15]</sup> In this context, carvacrol is a promising molecule for the treatment of local skin injury.

Wound healing is defined as the completion of closure at the clinically wounded skin area. Wound healing processes develops from some pathophysiological events including haemostasis, inflammation, cellular proliferation, matrix

synthesis and remodeling. It has been also shown that IL-1, TNF- $\alpha$  and TGF- $\beta$  stimulate neutrophile migration, fibroblast activation and reepithelization.<sup>[16,17]</sup>

In this context, we have investigated the effects of carvacrol on wound healing induced by excisional skin injury model in rats. We have evaluated wound surface area, wound depth, and granulation of the skin in a time dependent manner. In addition, we have studied the effects of carvacrol on the expressions of pro-inflammatory- IL-1 $\beta$ , TGF- $\beta$  and TNF- $\alpha$ .

## MATERIAL AND METHOD

### Animal experiments

Experiments were performed in accordance with National Institutes of Health Guidelines for the Care and Use of Laboratory Animals, and the study was approved by the local ethics committee (Ankara University, Medical Faculty). In this study, 350 $\pm$ 27 gr, male Wistar-albino rats were used in this study. Rats were equally divided into two set of experimental groups and treated with either

### \*Corresponding author.

Assist. Prof. Dr. Mehmet Y. Gunal, M.D.  
Istanbul Medipol University Medical Faculty  
Department of Physiology  
Phone: +90 216 681 51 00

E-mail: drmygunal@gmail.com

DOI: 10.5530/pj.2014.3.2

vehicle or carvacrol. Carvacrol was purchased by Sigma (Sigma-Aldrich; Istanbul, Turkey) and dissolved in sunflower oil in a concentration of 12,5%. Two-hundreds microliter carvacrol containing sunflower oil was applied topically on the injured skin just after excision of the skin and repeated for 5 consecutive days. Tissue samples were collected 3 (n=10), 8 (n= 10) and 12 (n= 10) days after induction of wound injury.

The animals were anesthetized with ketamine (60 mg/kg) and xylazine (6 mg/kg). Back, starting from the neck (2 × 3cm), of rats were completely cleaned of hair and wiped with 70% alcohol. Full-thickness skin wounds were formed on the cleaned part, as 1cm away from each of the middle line and each other, through the use of 4 mm punch biopsy tool.

Half of the tissues taken out were fixed with 10% formal solution for histological examination and the other half of the injured tissues collected were immediately frozen within liquid nitrogen for the examination of TNF- $\alpha$ , TGF- $\beta_1$ , IL-1 $\beta$  levels with enzyme linked immunosorbent assay (ELISA) method.

### Pathological and histological evaluation

Photographs of scar tissues were taken by using a Canon Power shot A410 model digital camera, and surface areas of scar tissues were calculated by using the program AutoCAD (2006). For the histological examination, 5  $\mu$ m tissue samples were stained with Hematoxylin-Eosin (H&E). Depth of tissue damage and thickness of granulation tissue on ulcer surface were measured by using Olympus BX50 light microscope and microscopic grid. During the evaluations, the depth between healthy epidermis on the side and the deepest area of ulcer surface was measured for determination of the depth of tissue damage. The distance between lower part of ulcer exudates on the surface and the lowest part of fibroblast was measured. In addition, the vascular proliferation and thickness of granulation tissue were evaluated.

### Evaluation of TNF- $\alpha$ , TGF- $\beta_1$ , IL-1 $\beta$ levels by ELISA

Glas-Col homogenizing system with Teflon top (Glas-Col, U.S.A.) was used for homogenization of the tissue samples. 4 ml buffer solution, 200  $\mu$ l PMSF and 2  $\mu$ l leupeptin were respectively put into homogenization glass tube. Each two pieces of four each tissues taken out according to days were added into this mixture. Glass tube was put into another container filled with ice. Tissue was ensured to be disintegrated by means of homogenizing system with Teflon top at 3200 rpm for ten minutes. The extract

obtained at the end of ten minutes was transferred into a glass centrifuge tube and centrifuged for 10 minutes at 3000xg within a centrifuge device with its ambient temperature adjusted as 4 degrees. The supernatant obtained after the centrifuge operation was transferred into polypropylene tubes and kept at -80 degrees until the time they will be used in ELISA operation.

BIOSOURCE Immunoassay Kit Rat TNF- $\alpha$  KRC3012 (Biosource International, Inc. USA) for TNF- $\alpha$ , BIOSOURCE Immunoassay Kit Rat Multispecies TGF- $\beta_1$  KAC1689 (Biosource International, Inc. USA) for TGF- $\beta_1$  and BIOSOURCE Immunoassay Kit Rat IL-1 $\beta$  KRC0012 (Biosource International, Inc. USA) for IL-1 $\beta$  were used throughout the study. In the preliminary study conducted for TNF- $\alpha$  and IL-1 $\beta$ , solutions at different dilution rates were obtained from tissue homogenate solutions by using "standard dilution buffer". For TNF- $\alpha$  and IL-1 $\beta$ , the homogenate was not diluted; for TGF- $\beta_1$ , the supernatant was 10-times diluted with "standard dilution buffer".

### Statistical evaluations

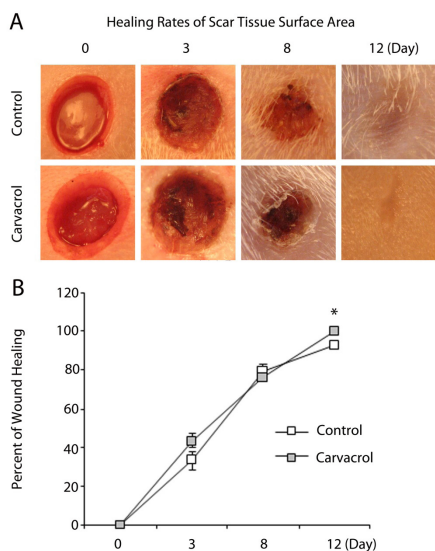
Variance analysis was applied in repetitive measurements for the purpose of comparing groups with regard to time. Due to the fact that main effects of group and time were found significant in consequence of variance analysis in repetitive measurements, double comparisons between group and time averages were made by examining them with Bonferroni test with confidence interval adjustment.

Parameters on the same day of carvacrol and control groups were analysed by nonparametric Mann Whitney-U test. P values <0.05 were considered statistically significant.

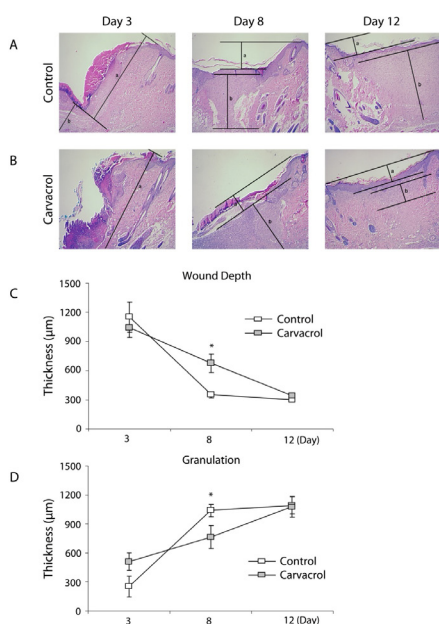
## RESULTS

### Pathological examination evaluation results

Carvacrol treatment improved wound healing processes. Scar surface measurement were conducted 3, 8 and 12 days after induction of injury. On day 12, carvacrol treatment decreased scar surface significantly (p=0.014) (Fig. 1). Histological examination showed exudate formation on day 3 in the carvacrol and vehicle treated animals (Fig. 2). Upon statistical evaluation of the data obtained from microscopic examination of scar tissue samples taken from control and carvacrol groups, wound depth on the 8<sup>th</sup> day was significantly high in carvacrol group with respect to control group (p=0.002) (Fig. 2), granulation tissue thickness on the same day was found significantly low in carvacrol group compared to control group (p=0.008) (Fig. 2).



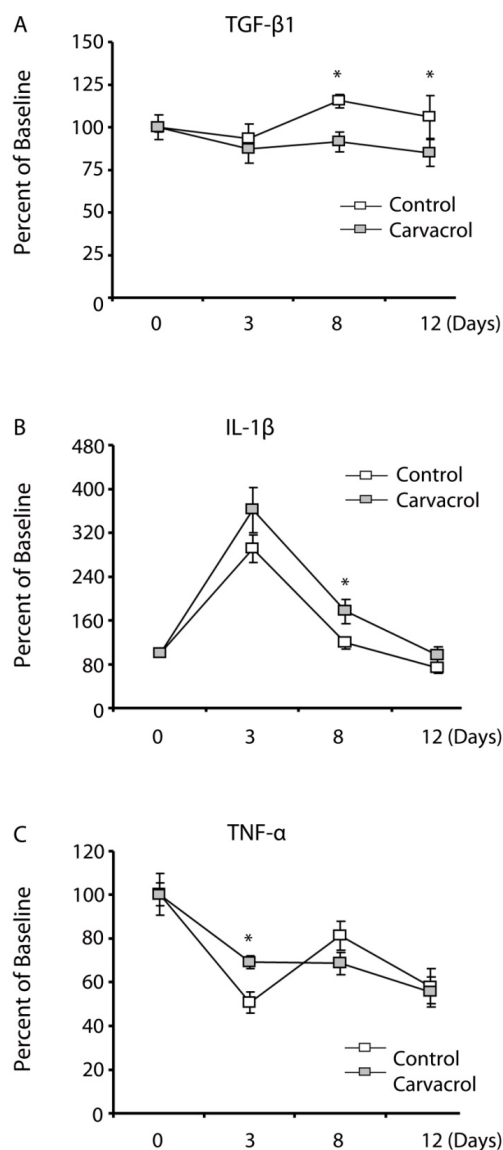
**Figure 1:** Macroscopic photographs of skin after excision in vehicle- and carvacrol- treated animals (A). Figure (B) shows that, healing rates of scar tissue surface area in control and carvacrol group. Healing rates of 12<sup>th</sup> day were found significantly high in carvacrol group compared to control group (on day 12, carvacrol treatment decreased scar tissue surface area significantly). The surface area of each wound tissue was measured as described in methods and reported at each time point as the percentage of the surface area at baseline.



**Figure 2:** Microphotographs of the section of injured tissues on 3<sup>rd</sup>, 8<sup>th</sup> and 12<sup>th</sup> day after wound exposure in vehicle (A) and carvacrol (B) treated animals. Tissue samples were stained with Hematoxylin – Eosin (H& E) as described in methods. Microscopic examination of wound depth (C) and granulation (D) tissue thickness on carvacrol and control group. Wound depth on the 8<sup>th</sup> day was significantly high in carvacrol group with respect to control group ( $p=0.002$ ), granulation tissue thickness on the same day was found significantly low in carvacrol group compared to control group ( $p=0.008$ ).

## ELISA FINDINGS

Cytokine levels of tissue homogenates obtained from scar tissues in control and carvacrol groups were measured with ELISA. TGF- $\beta_1$  levels on the 8<sup>th</sup> and 12<sup>th</sup> days were found significantly low in carvacrol group compared to control group ( $p=0.009$ ) ( $p=0.03$ ) (Fig. 3A). IL-1 $\beta$  levels on the 8<sup>th</sup> day were found significantly high in carvacrol group compared to control group ( $p=0.034$ ) (Fig. 3B).



**Figure 3:** Level of TGF- $\beta_1$  (A), IL-1 $\beta$  (B) and TNF- $\alpha$  (C) in vehicle and carvacrol treated animals. TGF- $\beta_1$  level was lower on the 8<sup>th</sup> and 12<sup>th</sup> days in carvacrol group compared to control group ( $p=0.008$ ). IL-1 $\beta$  level was significantly higher in carvacrol group compared to vehicle treated control group on the 8<sup>th</sup> day. TNF- $\alpha$  level was found significantly higher in carvacrol group compared to control group on day 3. Results are expressed in percent of baseline. Statistical analysis was performed using Mann Whitney-U test. P values  $<0.05$  were considered statistically significant.

TNF- $\alpha$  levels of 3<sup>rd</sup> day were found significantly high in carvacrol group compared to control group ( $p=0.000$ ) (Fig. 3C).

## DISCUSSION

Carvacrol is an essential oil which is present in compounds of many herbs. Apart from its known effects, its anti-microbial effects have been studied.<sup>[5,6]</sup> It inhibits prostaglandin synthesis, which plays roles in decreasing postoperative pain.<sup>[18]</sup> In this context, we have studied the roles of carvacrol in the pathophysiological events induced by excisional skin injury. First of all, we have defined the effective concentration of carvacrol. Following, we have treated animals with carvacrol at the concentration of 12.5%. Our results revealed that carvacrol-treatment improves healing rates of scar tissue surface area on the 12<sup>th</sup> day after surgery as compared with control. In contrast to increased tissue granulation, the wound depth is consonant with the condition in normal wound healing.<sup>[19]</sup> That granulation tissue thickness went up to approximately same levels on the 12<sup>th</sup> day while it was lower in carvacrol group compared to control group on the 8<sup>th</sup> day makes one think that carvacrol may affect wound healing between 8<sup>th</sup>-12<sup>th</sup> days. As a matter of fact, difference between groups in wound depth measurements on the 8<sup>th</sup> day changed in favour of carvacrol group on the 12<sup>th</sup> day, that is to say that wound depth in carvacrol group reached the same values in control group between 8<sup>th</sup>-12<sup>th</sup> days. This findings support that carvacrol may affect wound restoration process between 8<sup>th</sup>-12<sup>th</sup> days.

Different soluble factors play role in arranging and controlling phases of wound healing.<sup>[19]</sup> These factors are cytokines, growth factors, proteases, eicosanoids, quinines and cellular metabolites.<sup>[16]</sup> For this reason, it is not possible to affix events in the course of restoration process on effect of a single cytokine or growth factor.

IL-1 is a cytokine that plays a key role in inflammatory phase. It mediates synthesis and secretion of IL-1 and other proinflammatory cytokines (IL-6, G-CSF, GM-CSF) by inducing fibroblast and endothelial cells. It also leads to synthesis and secretion of more interleukin and PDGF by stimulating monocytes on wound area.<sup>[20]</sup> Leukocyte chemoattraction affects reepithelialization and fibroplasia phases.<sup>[21]</sup> IL-1 level reaches to measurable levels in the first 24 hours in experimental wounds, peaks between the 1<sup>st</sup> and 3<sup>rd</sup> days and rapidly decreases through the first week.<sup>[22,23]</sup> In the study, IL-1 $\beta$

in both of control group and carvacrol group were at measurable levels in the first day and showed a tendency to increase until the 3<sup>rd</sup> day. IL-1 $\beta$  levels on the 8<sup>th</sup> day were significantly high in carvacrol group. This study showed that carvacrol may contribute to inflammation during the early period and reepithelialization and fibroplasia processes during late period by means of increasing IL-1 $\beta$  levels.

Besides leukocyte chemoattraction, TNF- $\alpha$  increases vascular proliferation and permeability.<sup>[24]</sup> TNF- $\alpha$  also contributes to great number of cellular metabolic events such as procurement of nutrients and acute phase protein synthesis which are essential for wound healing.<sup>[25]</sup> On the other hand, TNF- $\alpha$  may have negative effects on wound healing. These effects occur as inhibition in collagen synthesis depending upon decrease in productions of collagen hydroxyproline and proalpha-1 chain.<sup>[26,27]</sup> Rapala et al. has shown that TNF- $\alpha$ , depending on dose in acute experimental wounds, decreases granulation tissue growth on the 7<sup>th</sup> day. However, this effect was not observed on the 14<sup>th</sup> and 21<sup>st</sup> days.<sup>[28]</sup> TNF- $\alpha$  can be locally detected within 12 hours and, peaks after 72 hours in clinically formed wound.<sup>[29]</sup> However, our findings showed that TNF- $\alpha$  levels in homogenates obtained from scar tissue have a tendency to decrease until the 3<sup>rd</sup> day in control group, peaked on the 8<sup>th</sup> day and gradually decreased later on. On the contrary, TNF- $\alpha$  levels in carvacrol group showed a continuous tendency to decrease.

TGF- $\beta$  is one of the most significant mediators in wound healing. It is secreted by T lymphocytes, endothelial cells, keratinocytes, thrombocytes in scar tissue, macrophages, smooth muscle cells and fibroblasts.<sup>[30,31]</sup> TGF- $\beta_1$ , TGF- $\beta_2$  and TGF- $\beta_3$  are 3 isoforms of TGF- $\beta$  found in mammals. TGF- $\beta_1$  and TGF- $\beta_2$  stimulates scar tissue formation by causing extracellular matrix deposition<sup>[32,33]</sup> via increasing extracellular matrix production and suppressing proteolysis and catabolism of extracellular matrix. On the other hand, some studies showed that TGF- $\beta_3$ , unlike the other two isoforms, has activities intended to decrease scar tissue formation.<sup>[32-35]</sup> However, our results showed that TGF- $\beta_1$  expression was significantly higher in carvacrol treated animals as compared with control animals.

## CONCLUSION

Here, we have evaluated the effects of carvacrol on tissue repair and time dependent expression patterns of IL-1 $\beta$ , TGF- $\beta_1$  and TNF- $\alpha$  after skin injury. Our result indicated beneficial effects of carvacrol on skin injury treatment

and it was associated with a moderately increased tissue granulation in the subacute phase of injury and increased expression of TGF- $\beta_1$ .

### DECLARATION OF INTEREST SECTION

The authors have any financial, consulting, and personal relationships with other people or organizations that could influence (bias) the author's work.

### REFERENCES

1. Baser K.H.C. Biological and Pharmacological Activities of Carvacrol and Carvacrol Bearing Essential Oils, *Current Pharmaceutical Design*, 2008; 14, 3106–3120
2. De Vicenzi M, Stamatii A, De Vicenzi A, Silano M. Constituents of aromatic plants: carvacrol. *Fitoterapia*. 2004; 75: 801–804.
3. Kırımer N, Başer KHC, and Tümen G. Carvacrol Rich Plants in Turkey. *Chem. Nat. Comp.* 1995; 31: 37–41.
4. Zeytinoğlu M, Aydın S, Öztürk Y, Başer KHC. Inhibitory effects of carvacrol on DMBA induced pulmonary tumorigenesis in rats. *Acta Pharmaceutica Turcica* 1998; 50: 93–98.
5. Ross SA, El-Keltawi NE, and Megalla SE, Antimicrobial Activity of Some Egyptian Aromatic Plants. *Fitoterapia* 1980; 51: 201–205
6. Thompson DP, Fungitoxic Activity Of Essential Oil Components On Food Storage Fungi. *Mycologia* 1989; 81: 151–153.
7. Didry N, Dubreuil L, and Pinkas M. Antimicrobial Activity of Thymol, Carvacrol and Cinnamaldehyde Alone or in Combination, *Pharmazie* 1993; 48: 301–304.
8. Akgül A, Kivanç M. Inhibitory Effects Of Selected Turkish Spices and Oregano Components on Some Foodborne Fungi. *Int. J. Food Microbiol* 1988; 6: 263–268.
9. Ali-Shtayeh MS, Al-Nuri MA, Yaghmour RMR, and Faidi YR. Antimicrobial Activity of *Micromeria Nervosa* From The Palestinian Area. *J. Ethnopharmacol.* 1997; 58: 1436–147.
10. Crippa A, and Bruno E. Antifungal Activity In Vitro of Phenols and other Natural Substances, *Eco. Nat. Ecol.* 1989; 7: 29–32.
11. Haraguchi H, Ishikawa H, Sanchez Y, et al. Antioxidative Constituents in *Heterotheca Inuloides*, *Bioorg. Med. Chem.* 1997; 5: 865–871
12. Lagouri V, Boskou D. Nutrient antioxidants in oregano. *Int. J. Food Sci. Nutr.*, 1996; 47: 493–497.
13. Cabo J, Crespo ME, Jimenez J, and Zarzuelo A. The Spasmodic Activity of Various Aromatic Plants From The Province of Granada. I.—The Activity of The Major Components of Their Essential Oils, *Plant Med. Phytother.* 1986; 20: 213–218.
14. Van Den Broucke CO, and Lemli JA. Antispasmodic Activity of *Origanum compactum*. *Planta Med.* 1980; 38: 317–331.
15. Van Den Broucke CO, and Lemli JA. Antispasmodic Activity of *Origanum compactum*, Part 2, Antagonistic Effect of Thymol and Carvacrol, *Planta Med.* 1982; 45: 188–190.
16. Henry G, Garner WL. Inflammatory mediators in wound healing. *Surg Clin N Am* 2003; 83: 483–507.
17. Kondo T, and Ishida Y. Molecular pathology of wound healing. *Forensic Science International* 2010; 203: 93–98
18. Wagner H, Wierer M, and Bauer R. In Vitro Inhibition of Prostaglandin Biosynthesis by Essential Oils and Phenolic Compounds, *Planta Med.* 1986; 52: 184–187.
19. Christine L. Theoret. DMV, PhD. Diplomate ACVS; update on wound repair. *Clin Tech Equine Pract.* 2004; 3: 110–112.
20. Herlyn M, Malkowitz S. Regulatory pathways in tumor growth and invasion. *Lab Invest.* 1991; 65: 262–271.
21. Sauder DN, Kilian PL, McLane JA, et al. Interleukin-1 enhances epidermal wound healing. *Lymphokine Res.* 1990; 9: 465.
22. Fahey TJ III, Sherry B, Tracey KJ, et al. Cytokine production in a model of wound healing: The appearance of MIP-1, MIP-2, cachectin/TNF and IL-1. *Cytokine* 1990; 2: 92.
23. Goretsky MJ, Harriger MD, Supp AP, Greenhalgh DG, and Boyce ST. Expression of interleukin-1 alpha, interleukin-6, and basic fibroblast growth factor by cultured skin substitutes before and after grafting to full-thickness wounds in athymic mice. *J. Trauma* 1996; 40: 894.
24. LJ Greenfield, MW Mulholland, KT Oldham, GB Zelenock, and KD Lillemore, eds. *Surgery: Scientific Principles and Practice*. pp. 124–147. Lippincott-Raven: Philadelphia, 1997.
25. Wilmore DW, LY Cheung, AH Harken, JW Holcroft, and JL Meakins, eds. *Cytokines and the cellular response to injury and infection*. Scientific American, Vol. 1: Care in the ICU. New York: Scientific American, 1996.
26. Rapala K. The effect of tumor necrosis factor alpha on wound healing: An experimental study. *Ann. Chir. Gynaecol. Suppl.* 1996; 211: 1.
27. Rapala K, Peltonen J, Heino J, et al. Tumor necrosis factor-alpha selectivity modulates expression of collagen genes in rat granulation tissue. *Eur. J. Surg.* 1997; 163: 207.
28. Rapala K, Laato M, Niinikoski J, et al. Tumor necrosis factor alpha inhibits wound healing in the rat. *Eur. Surg. Res.* 1991; 23: 261.
29. Feiken E, Romer J, Eriksen J, and Lund LR. Neutrophils express tumor necrosis factor-alpha during mouse skin wound healing. *T.* 1995; 105: 120.
30. Buckmire MA, Parquet G, Greenway S, and Rolandelli RH. Temporal expression of TGF-beta 1, EGF, and PDGF-BB in a model of colonic wound healing. *J. Surg. Res.* 1998; 80: 52.
31. Schultz J, Rotatori DS, and Clark W. EGF and TGF alpha in wound healing and repair. *J. Cell. Biochem.* 1991; 45: 346.
32. Shah M, Foreman DM, and Ferguson MWJ. Neutralising antibody to TGF- $\beta_{1,2}$  reduces cutaneous scarring in adult rodents. *Journal of Cell Science* 1994; 107: 1137–1157.
33. Shah M, Foreman DM, and Ferguson MWJ. Neutralisation of TGF- $\beta_1$  and TGF- $\beta_2$  or exogenous addition of TGF- $\beta_3$  to cutaneous rat wounds reduces scarring. *Journal of Cell Science* 1995; 108: 985–1002.
34. Ferguson MWJ and O'Kane S. Scar-free healing: from embryonic mechanisms to adult therapeutic intervention. *Phil. Trans. R. Soc. Lond. B* 2004; 359: 839–850.
35. Li W, Huang EY, Dudas M, et al. Transforming growth factor- $\beta_3$  affects plasminogen activator inhibitor-1 expression in fetal mice and modulates fibroblast mediated collagen gel contraction. *Wound Rep Reg* 2006; 14: 516–525.