

Combined Therapy with Probiotic VSL#3 and Omega-3 Fatty Acids Attenuates Colonic Injury and Inflammation in Chronic DNBS-induced Colitis in Mice

Havvanur Yoldas ILKTAC^{ID}, Gul KIZILTAN^{ID}, Asli Devrim LANPIR^{ID}, Mehmet OZANSOY^{ID},
Mehmet Y. GUNAL^{ID}, Sine Ozmen TOGAY^{ID}, Ilknur KESKIN^{ID}, Ekrem M. OZDEMIR^{ID}, and Ulkan KILIC^{ID}

Accepted September 13, 2021

Published online October 06, 2021

Issue online October 13, 2021

Original article

ILKTAC H.Y., KIZILTAN G., LANPIR A.D., OZANSOY M., GUNAL M.Y., TOGAY S.O., KESKIN I., OZDEMIR E.M., KILIC U. 2021. Combined therapy with probiotic VSL#3 and omega-3 fatty acids attenuates colonic injury and inflammation in chronic DNBS-induced colitis in mice. *Folia Biologica (Kraków)* **69**: 135-146.

Inflammatory bowel disease (IBD) is a progressive chronic inflammatory disease affecting the gastrointestinal tract with a chronic relapsing and remitting disease course. While there are a number of therapeutic strategies available to treat IBD, a definitive treatment still hasn't been defined, leading to alternative treatment options including nutritional support. Herein, we planned to investigate the combined impact of probiotics and omega-3 (ω -3) fatty acids on inflammatory response and intestinal epithelium in chronic colitis induced by 2,4-Dinitrobenzenesulfonic acid (DNBS). Fifty BALB/c mice were randomly divided into five groups: non-colitis control, colitis with no treatment applied (control colitis), colitis treated with probiotics (VSL#3), colitis treated with ω -3, and colitis treated with both VSL#3 and ω -3. Colitis was induced by intrarectal administration of 2,4-Dinitrobenzenesulfonic acid (DNBS) in all groups but the non-colitis control group. Ten days after the DNBS period, phosphate-buffered saline (for both the non-colitis control and colitis control groups), VSL#3, ω -3, or VSL#3 + ω -3 treatments were administered intragastrically to their respective groups for 10 days. By analyzing the colonic expression of interleukin IL-6, IL-10, and IL-17A, and interferon gamma (IFN- γ) and tumor necrosis factor alpha (TNF- α) levels, results revealed that levels of IFN- γ , IL-17, and TNF- α were significantly higher in the control colitis group when compared with the other groups. The control colitis, colitis + VSL#3, and colitis + ω -3 groups exhibited higher scores of microscopic damage compared to the non-colitis control and colitis + VSL#3 + ω -3 groups. The closest histological image to the non-colitis control group was presented in the colitis + VSL#3 + ω -3 group. The findings indicate that the combined effect of probiotics and ω -3 fatty acids might have a protective effect against colon injury and inflammation by creating synergistic effects. However, more research is needed to understand the exact mechanism of this synergistic effect and to examine how this therapeutic approach can be used in inflammatory bowel diseases.

Key words: Cytokines, strains, essential fatty acids, inflammatory bowel diseases, colonic tissue.

Havvanur Yoldas ILKTAC[✉], Asli Devrim LANPIR, Department of Nutrition and Dietetics, Faculty of Health Sciences, Istanbul Medeniyet University, Istanbul.

E-mail: havvanur.yoldas@medeniyet.edu.tr

Gul KIZILTAN, Department of Nutrition and Dietetics, Faculty of Health Sciences, Baskent University, Ankara.

E-mail: gkizilta@baskent.edu.tr

Mehmet OZANSOY, Department of Physiology, Faculty of Medicine, Bahcesehir University, Istanbul.

E-mail: mehmet.ozansoy@med.bau.edu.tr

Mehmet Yalcin GUNAL, Department of Physiology, Faculty of Medicine, Alanya Alaaddin Keykubat University, Antalya.

E-mail: yalcin.gunal@alanya.edu.tr

Sine Ozmen TOGAY, Department of Food Engineering, Faculty of Agriculture, Uludag University, Bursa.

E-mail: sineozmen@gmail.com

Ilknur KESKIN, Department of Histology and Embryology, Faculty of Medicine, Istanbul Medipol University, Istanbul.

E-mail: ilknurkeskin@medipol.edu.tr

Ekrem Musa OZDEMIR, Medical Research Center, Istanbul Medipol University, Istanbul.

E-mail: emozdemir@medipol.edu.tr

Ulkan KILIC, Department of Medical Biology, Faculty of Medicine, University of Health Sciences, Istanbul.

E-mail: uckilic@yahoo.com.tr

Inflammation begins when the body perceives an undesirable challenge in the body and acts as an important part of innate immunity, which helps to regulate host defense (BENNETT *et al.* 2018). The inflammatory process in the body stimulates the activation of various inflammatory signaling pathways, including the NF- κ B, AP1, MAPK, CREB, c/EBP, JAK-STAT, and IRF pathways, thereby triggering the production of adhesion molecules, enzymes, and cytokines to fight against inflammation (LIU *et al.* 2017; PLATANITIS & DECKER 2018). However, when inflammation becomes chronic, it causes serious damage to the GI tract, especially rectal bleeding, persistent diarrhea, bloody stool, fatigue, and weight loss (BAUMGART & SANDBORN 2007). Inflammatory bowel diseases (IBD), mainly Ulcerative Colitis (UC) and Crohn's disease, are chronic systematic disorders of the gastrointestinal tract characterized by uncontrolled mucosal immunity and recurrent inflammatory attacks (BAUMGART & SANDBORN 2007; DIDUCH 2017). Although the prevalence of IBD has increased worldwide over the past few decades (ALATAB *et al.* 2020), its etiology is still not fully understood (BAUMGART & SANDBORN 2007; GHOURI *et al.* 2014). Various medications are recommended in IBD patients to prevent disease progression and control inflammatory reactions, including aminosalicylates, corticosteroids, immunosuppressants, and biologic agents (TRIPATHI & FEUERSTEIN 2019). However, there is no agent that provides a complete cure in clinical practice (MATSUOKA *et al.* 2018). In addition, these drugs have critical side effects such as GI toxicity, pancreatitis, and immunosuppression (BAUMGART & SANDBORN 2007; KLEIN & ELIAKIM 2010; TRIPATHI & FEUERSTEIN 2019). Therefore, researchers have been trying for years to find a safer alternative therapeutic approach, such as nutritional therapies and nutritional supplements, to overcome these challenges (GHOURI *et al.* 2014; SINGH *et al.* 2019). Studies on IBD suggest that genetic, immune, and environmental factors may contribute to the occurrence of these chronic inflammatory disorders (ABEGUNDE *et al.* 2016). In addition, an elevated inflammatory state can cause damage to the GI tract, causing intestinal epithelial leakage and disruption of intestinal barrier integrity (LECHUGA & IVANOV 2017). Therefore, several probiotic treatments have been developed to provide beneficial microbial support to improve gut health (GHOURI *et al.* 2014; PENNER *et al.* 2005). Probiotics act directly on the epithelial barrier by increasing the production of mucin, antimicrobial peptides, and β -defensin in goblet cells, thereby reducing epithelial permeability to intraluminal pathogens and toxins (CAMILLERI 2021). This is why probiotic therapy is commonly applied to provide beneficial microbial support to maintain intestinal epithelial barrier integrity and mucosal homeostasis in IBD patients (GHOURI *et al.* 2014; PARKER *et al.* 2018; ZUO & NG 2018). Although pro-

biotics are known to have various beneficial effects on health, their benefits vary depending on the type and stage of the disease to be treated and the strain and dose of the probiotics administered (MARCASON 2013). A systematic review of randomized controlled trials (RCTs) determining the effect of probiotics, prebiotics, and symbiotics on IBD noted that a VSL#3 probiotic mixture was administered in five of the nine RCTs conducted on patients with UC (GHOURI *et al.* 2014). All studies investigating VSL#3 supplementation and UC demonstrated that the probiotic blend had significant beneficial effects, including an improvement in clinical activity and an increase in beneficial dendritic cell cytokines in UC patients. However, these RCTs had some limitations, including a high placebo response rate and short administration period (GHOURI *et al.* 2014). Therefore, more studies are needed to clarify the precise efficacy of these probiotics on IBD patients. Omega-3 (ω -3) fatty acids are long-chain fatty acids well-known for their strong anti-inflammatory properties due to the anti-inflammatory activity of ω -3 derived eicosanoids (HUSSEIN *et al.* 2019). Studies on IBD show that ω -3 can play a protective role during the inflammatory process of IBD by providing substrates for the production of protectins, resolvins, and maresins that regulate and attenuate inflammatory conditions in IBD and lead to remission of IBD (DURKIN *et al.* 2021; MARTON *et al.* 2019). However, there are still many unknowns about the efficacy of ω -3 fatty acids on IBD (BARBALHO *et al.* 2016). Therefore, the effect of ω -3 fatty acids on IBD needs further clarification. To our knowledge, no studies have investigated the application of probiotics supplemented with ω -3 fatty acids on the intestinal epithelium and inflammatory response in IBD patients/animal models. Therefore, we aimed to determine the combined effect of probiotics and 3 fatty acids on the inflammatory response and intestinal epithelium in mice with chemically induced chronic colitis.

Material and Methods

The study received ethical approval from the Istanbul Medipol University Experimental Animals Research Committee (12/2014, no. 38328770/83). All procedures involved in animal experiments were performed in accordance with the 'Guide for the Care and Use of Laboratory Animals' prepared by the National Institute of Health (NATIONAL RESEARCH COUNCIL (US) COMMITTEE 2011). The sample size was calculated based on the tissue TNF- α values of colitis-induced mice in a previous experimental study (SOYTURK *et al.* 2012). The power analysis showed that a sample size of 6 mice/group has an 80% power to detect an ES of 1.98 pg/ml or an 8% change, assuming a 5% significance level and a two-sided test. The attrition rate is expected to be around 10-20% in ani-

mal studies involving acute treatments (CHARAN & KANTHARIA 2013). However, this rate may be higher in long-term studies in which chronic disease is triggered (HOLMAN *et al.* 2016). Therefore, we included 10 mice per group based on an expectation of 40% attrition from the experimental treatment.

Animals

Fifty male BALB/c mice weighing 20-30 g (6-8 weeks old) were obtained from the Istanbul Medipol University Medical Research Center (MEDITAM). The mice were housed in standard polypropylene cages at $20 \pm 1^\circ\text{C}$ with $50\% \pm 5\%$ humidity on a 12-hour light/dark cycle at the Istanbul Medipol University Regenerative and Restorative Medicine Research Center (REMER) Animal Laboratory, fed with standard chow and water ad libitum, and weighed daily throughout the experiments. After a one-week acclimatization period, the mice were randomly assigned to five groups (n= 10/group): control non-colitis, control colitis, treated with probiotics, treated with ω -3 fatty acids, and treated with both probiotics and ω -3 fatty acids. During the study period, four mice each from the control non-colitis, control colitis, ω -3, and probiotics plus ω -3 groups, and five mice from the probiotic group died due to aspiration or both aspiration and colitis, leading to the continuation of the experiment with fewer mice planned for inclusion for the probiotic group at the beginning of the study.

Induction of colitis using Dinitrobenzene Sulfonic Acid and experimental design

Chronic moderate colitis was induced using a method previously described (MARTÍN *et al.* 2014). The experimental protocol implemented in the study included acute colitis induction with Dinitrobenzene

sulfonic acid (DNBS), a recovery period, reactivation of colitis with DNBS, and therapeutic treatment with gavage. Before starting the protocol, a 10 cm long piece of PE tubing (ClayAdam, Parsippany, NJ, USA) attached to a tuberculin syringe was inserted 3.5 cm into the colon after the mice were anesthetized with enflurane (Abbott, Abbott Park, IL, USA). The mice in the colitis groups were treated intercolonially with 200 mg/kg DNBS dissolved in 30 % ethanol via the PE tube for three days, while the non-colitis control group was administered phosphate-buffered saline (PBS) only (Sigma-Aldrich, USA). A 6% sucrose solution was administered to the mice through their drinking water for the first three days to prevent dehydration. A 10-day recovery period (no treatment, fed and allowed to drink water ad libitum) was provided for all groups after the 3-day DNBS administration. The treatment groups were administered probiotics, ω -3, or both together for ten days from day 14 following the recovery period while the non-colitis control and control colitis groups received PBS. During the treatment period, the colitis was reactivated on days 21 to 24 by administering 100 mg/kg DNBS solution through the PE-tube. Mice were killed by cervical dislocation on day 24. The study protocol is detailed in Figure 1.

Disease activity index

Calculation of Disease Activity Index (DAI) is presented in Table 1 (MURTHY *et al.* 1993). The DAI scores were calculated daily for each mouse throughout the study period.

Probiotic and omega-3 administration

Ten days after colitis induction, the groups received probiotics, ω -3, probiotic plus ω -3, or PBS alone (control non-colitis and control colitis groups) for ten days (day 14-23). The VSL#3 probiotic mixture was

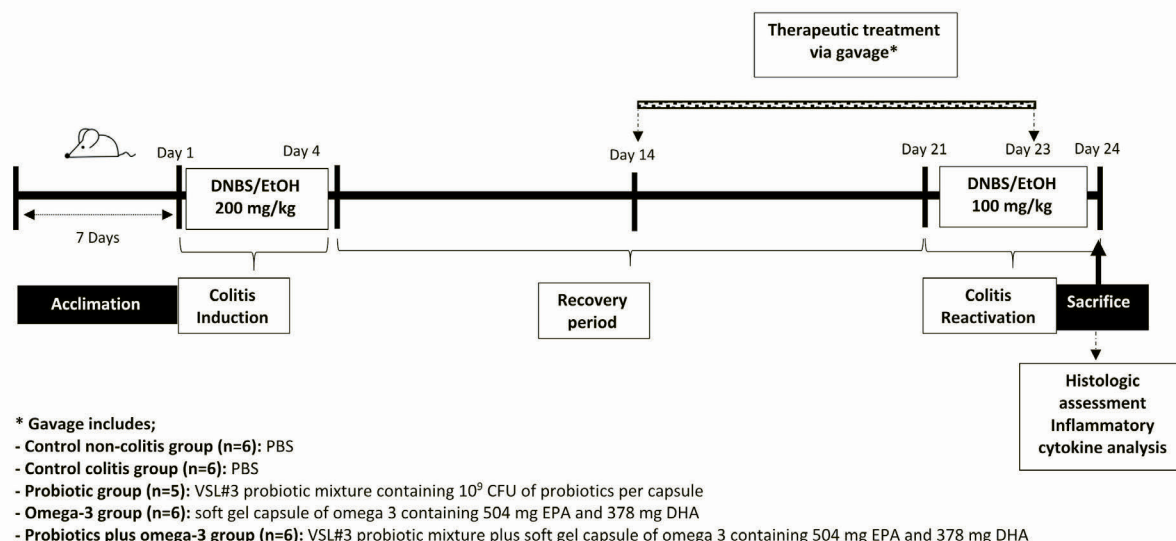


Fig. 1. Experimental protocol.

Table 1
Calculation of disease activity index^a

Score	Weight loss (%)	Stool Consistency	Occult blood or gross bleeding
0	None	Normal	None
1	1-5		
2	5-10	Pasty/semi-formed stool	Occult bleeding ^b
3	10-15		
4	15	Liquid stool	Gross bleeding

^a The average daily disease activity index (DAI) was calculated by summing the results of these parameters and dividing the results by three (MURTHY *et al.* 1993).

^b The presence of occult blood in the stool was detected using the Hemocult II; Beckman Coulter Inc., Fullerton, CA, USA.

prepared daily for ten days, dissolved in 200 ml drinking water, and administered intragastrically to the probiotic and probiotic plus ω -3 groups. VSL#3 is a mixture of one billion CFU of freeze-dried probiotics in one capsule, consisting of eight bacterial strains including three strains of bifidobacteria (*B. longum*, *B. infantis*, and *B. breve*), four strains of lactobacilli (*L. acidophilus*, *L. paracasei*, *L. delbrueckii* subsp. *bulgaricus*, and *L. plantarum*), and *Streptococcus salivarius* subsp. *thermophilus* (Sigma-Tau Pharmaceuticals Gaithersburg, MD, USA).

Additionally, mice in the ω -3 and probiotic plus ω -3 groups received a 300 mg/kg dose of ω -3 fatty acids intragastrically for ten days. The ω -3 administered was the soft gel form of ω -3 containing 504 mg of EPA and 378 mg of DHA per capsule (Omega 950, Solgar, Turkey). The ω -3 dose was determined according to the Health Canada Draft Guidelines, which states that it is the therapeutically effective dose to achieve a human equivalent dose of 3.0 g/day (REGAN-SHAW *et al.* 2008).

Colonic tissue collection

The entire colon was cleaned after exposing the abdominal cavity with a midline laparotomy. The colon was opened longitudinally and half was immediately placed in a formalin solution for histopathological examination, while the remainder was snap-frozen in liquid nitrogen and stored at -80°C for analysis of inflammatory cytokines.

Tissue homogenization and determination of inflammatory cytokines in tissue homogenates

To prepare tissue homogenates, the colon tissue was homogenized in 400 ml of Tris-HCl buffer containing protease inhibitors (Sigma, Aldrich) in a Tissue Lyser at pH 7.4 at 0-4°C. The homogenates were then centrifuged at 14,000 x g for 30 minutes and the super-

natants were collected for inflammatory cytokine analysis. Five pro-inflammatory cytokines, including interferon-gamma (IFN- γ), interleukin IL-6, IL-10, and IL-17, and tumor necrosis factor-alpha (TNF- α) in tissue homogenates were quantified using the Mouse ELISA Kit (BioLegend, San Diego, USA) according to the manufacturer's instructions. Cytokines were analyzed using a Magpix Luminex System (Austin, Texas, USA) according to the manufacturer's instructions. Briefly, primary antibodies for each cytokine were immobilized on magnetic beads and after overnight incubation at +4°C, samples were incubated with a streptavidin-phycoerythrin solution at room temperature in the dark. The samples were then measured luminometrically. The data obtained were evaluated using XPONENT software.

Histological evaluation

The colon was fixed in 10% formaldehyde and then processed for paraffin embedding and cut into 5 μ m thick sections. Paraffin blocks were stained with hematoxylin and eosin (H&E; Merck, Darmstadt, Germany) for histological scoring using light microscopy (Axio V 16) by a pathologist blinded to the study. The colon was examined under a light microscope at x16 magnification by the same pathologist. Microscopic colitis was assessed using normal morphological structure, density of goblet cells, presence of crypts, and lymphoid tissue and scored according to epithelial and infiltration status as described (OBERMEIER *et al.* 1999) (Table 2). A numerical score was calculated for each mouse by summing the epithelium and infiltration scores.

Statistical analysis

Statistical analysis was performed using SPSS (version 22.0). A one-way ANOVA was performed to compare the differences between the experimental

Table 2
Criteria for scoring microscopic colitis¹

Factors	Score
Epithelium	
Normal morphology	0
Loss of goblet cells	1
Loss of goblet cells in large areas	2
Loss of crypts	3
Loss of crypts in large areas	4
Infiltration	
No infiltration	0
Infiltration around crypt basis	1
Infiltration reaching to Lamina muscularis mucosa	2
Extensive infiltration reaching the Lamina muscularis mucosae and thickening of the mucosa with abundant edema	3
Infiltration of the Lamina submucosa	4

¹Criteria for scoring microscopic colitis was reported by OBERMEIER *et al.* 1999.

groups. Levene's test was used to determine the homogeneity of variances. A p-value of <0.05 was considered significant. When an overall significance was observed, pairwise posthoc analyses were run using Tukey's test to test the probability of where the differences actually came from. Results were expressed as mean \pm standard error of the mean (SEM) and presented as bar graphs.

Results

Changes in body weight and food and water intake before the experimental period

No differences were observed in changes in body weight, or food and water intake over the 1-week acclimatization period (data not shown).

Characterization of DNBS-induced colitis

While the decrease in body weight percentage was higher in the control colitis group than in the other groups, there was no significant difference between the other groups (Figure 2). The total microscopic damage scores were also significantly greater in the control colitis group compared to the other groups (Figure 3). Furthermore, a significant difference was detected in histological changes between the control

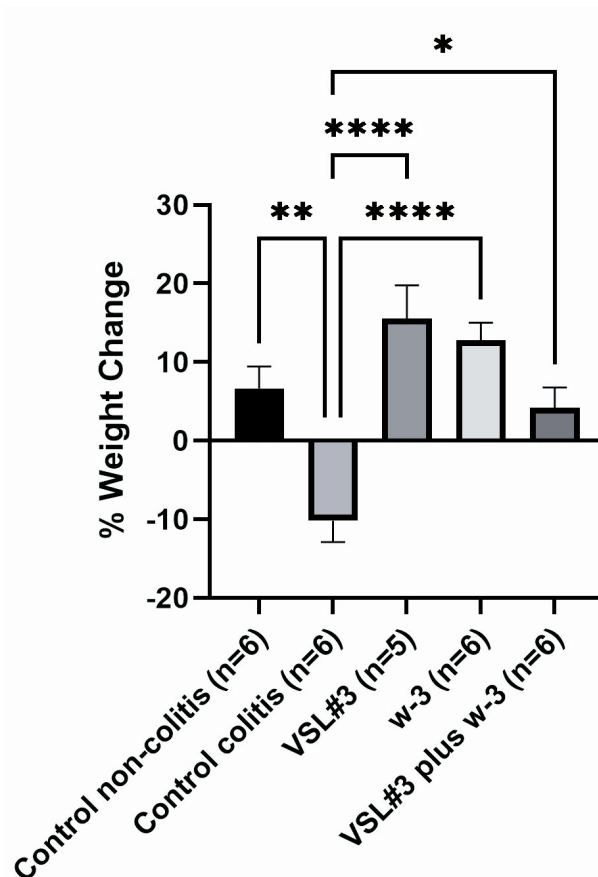


Fig. 2. Changes in body weight after the experimental trials. All findings are presented as the mean \pm SEM; w-3 – omega 3 fatty acids.

*p<0.05; **p<0.01; ****p<0.0001.

colitis and non-colitis control groups (Figure 4). The control colitis group had higher goblet cell depletion, morphologic derangements, and loss of crypt structures compared to the non-colitis control group. For daily DAI index scores, a significant increase in DAI index was observed in the DNBS-treated mouse groups compared to the non-colitis control group (p<0.05), indicating the presence and activation of colitis as a result of DNBS administration.

Alterations in disease activity index scores monitored daily

We monitored colitis-related clinical symptoms (weight change %, stool consistency, and presence of blood in the stool) on a daily basis to determine the severity of colitis (Figure 5). After the second day of acute colitis induction, a significant increase in DAI scores was detected in all DNBS-treated groups, with a significant difference compared to the non-colitis control group. The DAI scores of the VSL#3 plus ω -3 group were significantly lower than the control colitis groups. A significant reduction in colitis severity was

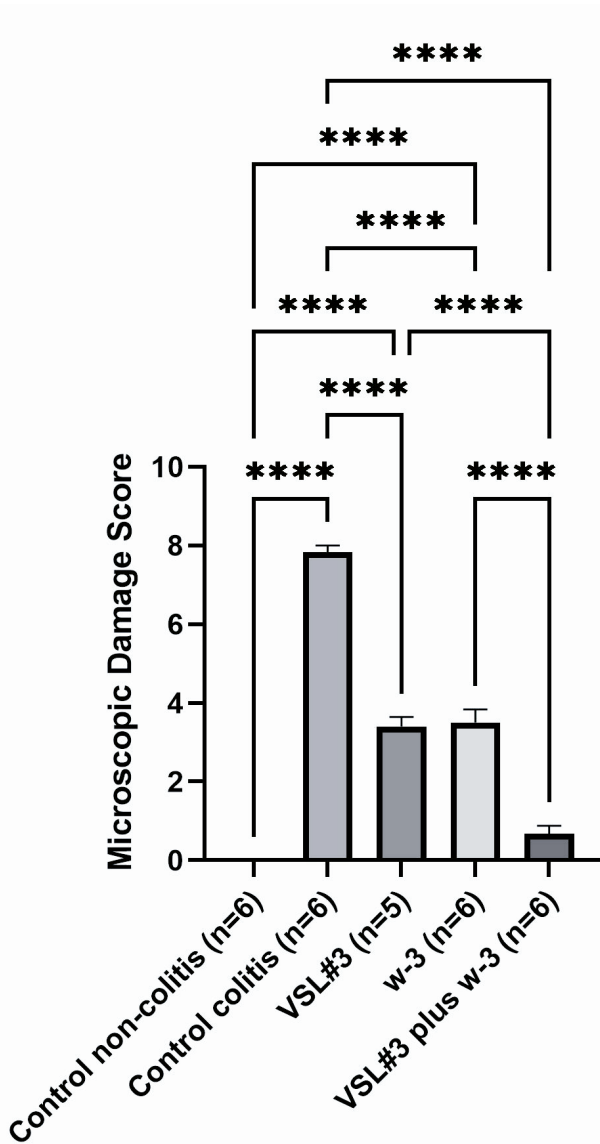


Fig. 3. Microscopic damage score calculated after colitis. All findings are presented as the mean \pm SEM; w-3 – omega 3. **** p <0.0001.

observed in mice treated with VSL#3 plus ω -3, including little or no blood in the stool and an increase in stool consistency.

Effects of therapeutic treatment on pro-inflammatory cytokines in colonic tissues

Figure 6 presents the concentrations of proinflammatory cytokines in colonic tissue after the experimental period. Tissue concentrations of IFN- γ were found to be significantly higher in the control colitis group (63.6 ± 10.3 pg/mg protein) compared to the non-colitis control group (27.0 ± 7.8 pg/mg protein) (p <0.05). Lower levels of IFN- γ were also observed in the VSL#3 (26.2 ± 3.1 pg/mg protein) and VSL#3

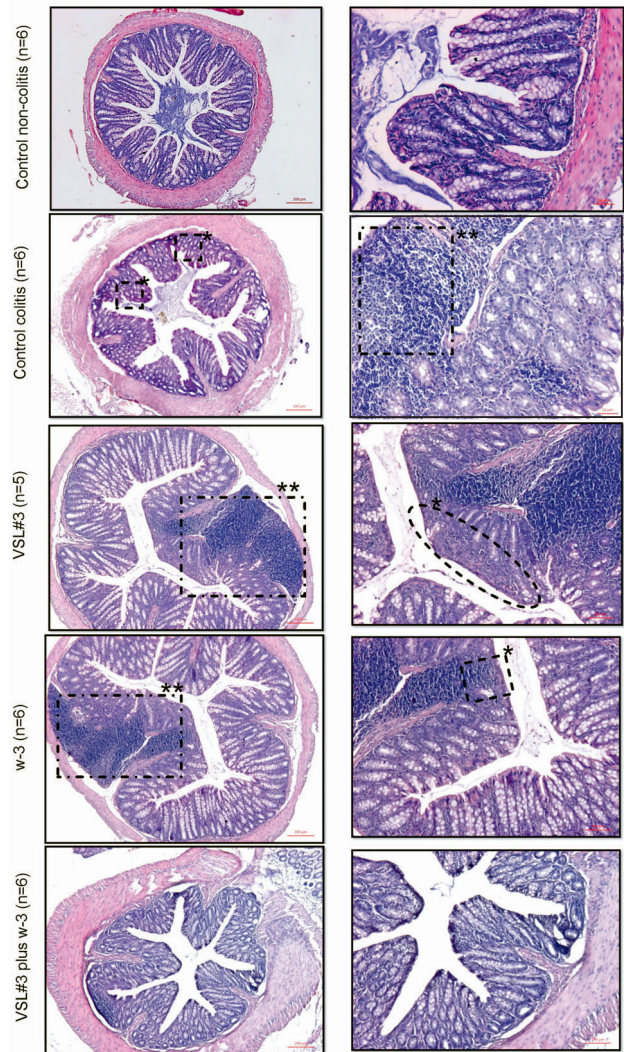


Fig. 4. Representative colonic histopathological images of experimental groups. Hematoxylin/eosin staining of representative cross-sections of distal colon (H&E \times 100). Control non-colitis group (n=6): Normal appearance of the mice colon; Control colitis group (n=6): Diffuse lymphoid tissue in the submucosa, complete epithelial eradication, diffuse goblet cell loss; VSL#3 group (n=5): Diffuse lymphoid tissue in the submucosa, epithelial erosion and goblet cell loss; omega-3 (w-3) group (n=6): Diffuse lymphoid tissue in the submucosa, partial epithelial erosion and goblet cell loss; VSL#3+omega group (n=6): Very similar morphology with the normal group and goblet cells rich single-prismatic epithelium. *represents the absence of goblet cells. **shows diffuse lymphoid tissue in the submucosa and epithelial erosion.

plus -3 (31.4 ± 6.8 pg/mg protein) groups compared to the control colitis group.

As shown in Figure 6, higher IL-6 concentrations and lower IL-10 levels were observed in the control colitis group compared to the other groups; however, the differences were not statistically significant.

IL-17A expression was significantly increased in the control colitis group (257.8 ± 34.7 pg/mg protein) compared to the other groups (p <0.05) (Figure 3).

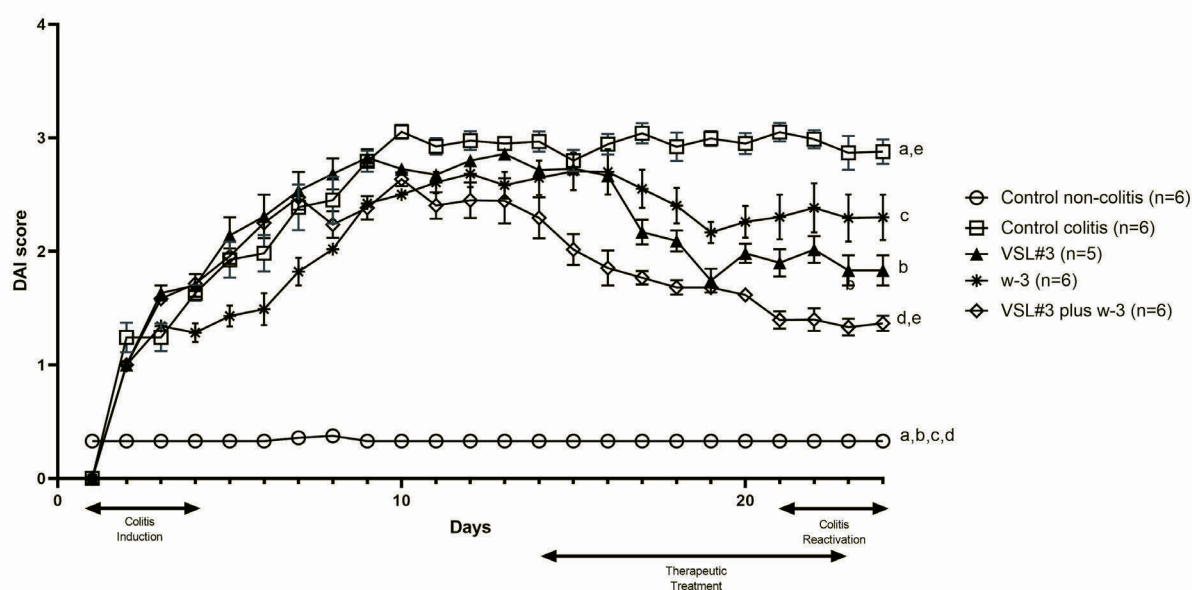


Fig. 5. Time course of changes in Disease Activity Index (DAI) scores.

^a $p < 0.05$ between the control non-colitis and control-colitis groups; ^b $p < 0.05$ between the control non-colitis and VSL#3 groups; ^c $p < 0.05$ between the control non-colitis and omega 3 fatty acids (w-3) groups. ^d $p < 0.05$ between the control non-colitis and VSL#3 and w-3 groups. ^e $p < 0.05$ between the control colitis and VSL#3 and w-3 groups. ^f $p < 0.05$ between the w-3 and VSL#3 and w-3 groups.

However, no meaningful difference was detected between the treatment groups.

Lower TNF- α concentrations were observed in the VSL#3 (36.4 ± 7.7 pg/mg protein), ω -3 (67.0 ± 13.5 pg/mg protein), and VSL#3 plus ω -3 (52.6 ± 13.5 pg/mg protein) groups compared to the control colitis group (128.0 ± 15.2 pg/mg protein) ($p < 0.05$) (Figure 6).

Microscopic damage scores

The microscopic damage score of the experimental groups is presented in Figure 3. The highest microscopic colitis score (7.8 ± 0.1) was found in the control colitis group compared to the other groups ($p < 0.0001$). Comparing the therapeutic treatment groups, the VSL#3 plus ω -3 group showed a lower damage score than that observed in the VSL#3 and ω -3 groups. In addition, the score observed in the VSL#3 + ω -3 group (0.6 ± 0.2) was similar to the non-colitis control group ($p > 0.05$).

Histopathological results

The histopathological appearance of representative H&E stained sections of colonic tissue is shown in Figure 4. No histopathological abnormalities and disordered morphology were detected in the non-colitis control group. In contrast, the control colitis group showed significant differences compared to the non-colitis control group, such as an alteration of crypt pa-

thology, a significant reduction in goblet cells, and a diffusion of lymphoid tissue extending from the submucosa to the lumen. In the VSL#3-treated group, normal morphology was generally preserved; however, a disappearance in crypt structure in a limited area and a reduction in goblet cells was observed. The histological images of the ω -3 group were quite similar to the VSL#3 group, except that crypt structures disappeared in a more limited area. The morphology of the VSL#3 + ω -3 group including the regular, single-layer prismatic epithelium rich in crypt and goblet cells was quite similar to that of the non-colitis control group. In addition, lymphoid tissue was observed in a limited area in the VSL#3 + ω -3 group.

Discussion

The current study evaluated the effect of VSL#3 or ω -3 alone or the combination of the two supplements on chronic DNBS-induced colitis in mice. Our main findings confirmed our hypothesis by showing that the administration of probiotics in combination with ω -3 is more effective in managing chronic DNBS-induced colitis by preserving intestinal mucosal morphology, and alleviating microscopic damage and disease activity. Administration of VSL#3 alone and in combination with ω -3 reduced the concentrations of IFN- γ and TNF- α , the well-known proinflammatory cytokines that are elevated by colitis induction.

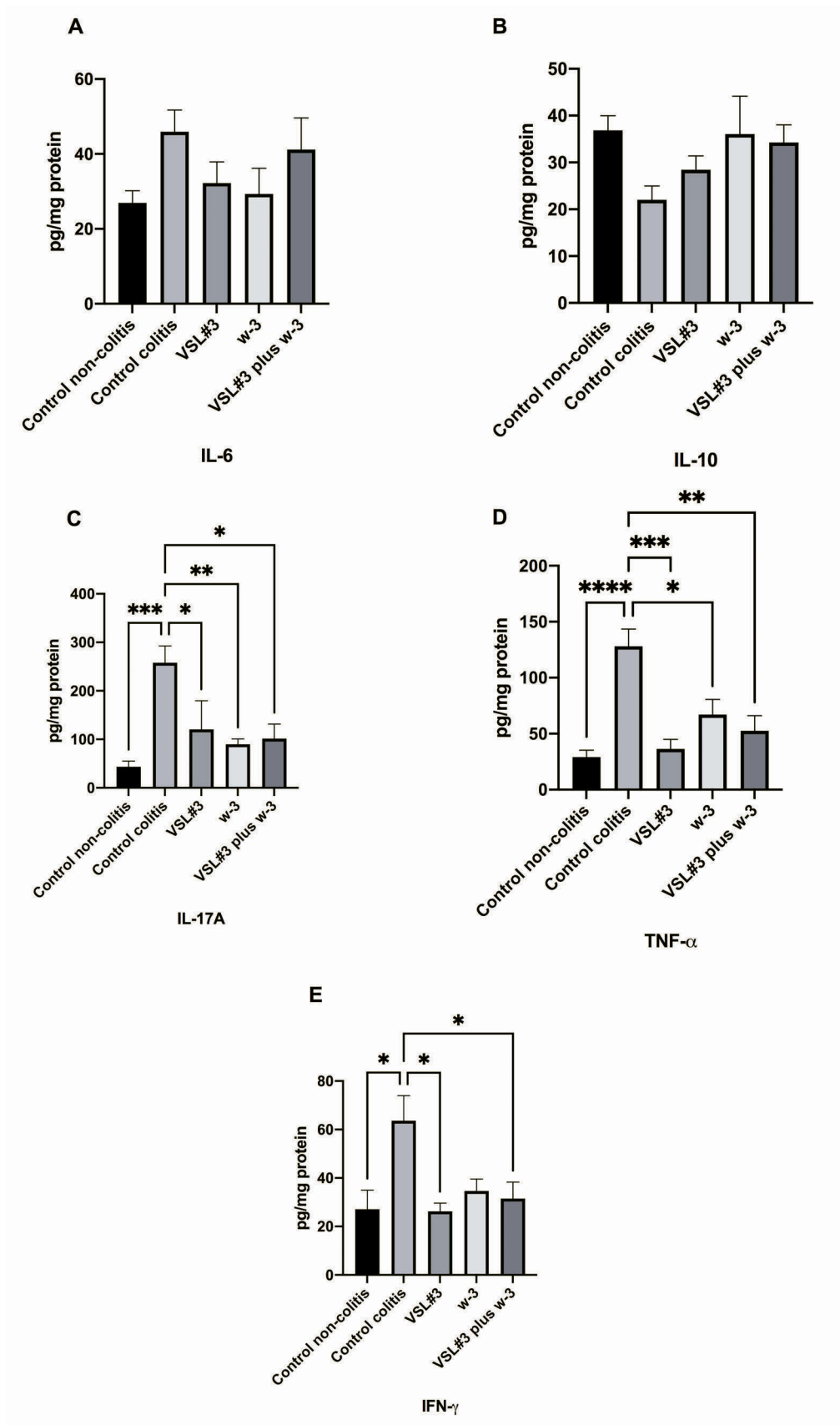


Fig. 6. Tissue inflammatory cytokine levels of the experimental groups. A: Tissue interleukin-6 levels; B: Tissue interleukin-10 levels. C: Tissue interleukin-17 levels. D: Tissue tumor necrosis factor alpha (TNF- α) levels. E: Tissue interferon-gamma (IFN- γ) levels. The results are presented as the mean \pm SEM. * p <0.05; ** p <0.01; *** p <0.001; **** p <0.0001. Control non-colitis group (n=6); Control colitis group (n=6); VSL#3 group (n=5); omega-3 (w-3) group (n=6); VSL#3+omega group (n=6).

Before evaluating the efficacy of the therapeutic treatment applied in this study, we checked whether colitis occurred with DNBS induction. DNBS-induced colitis is a well-defined experimental model of UC that exhibits various morphological and pathophysiological features similar to human UC (MORAMPUDI *et al.* 2014). The specific mechanism of colitis induction is still not well defined (RANDHAWA *et al.* 2014). However, it has been reported that DNBS administration changes the histopathological morphology of colon tissue, disrupts the intestinal mucosal barrier, triggers proinflammatory response, and worsens gastrointestinal symptoms such as diarrhea and bloody stool (MARTÍN *et al.* 2014; MORAMPUDI *et al.* 2014; RANDHAWA *et al.* 2014). Our findings demonstrate that the DNBS-treated groups exhibited disordered colonic morphology, including a loss of goblet cells and crypt structures compared to the non-colitis control group. In addition, greater weight loss was observed in the DNBS-induced colitis groups. This may be attributed to the severe diarrhea that progressively increased from the second day of DNBS administration and sharp decrease in food intake (data not shown). Furthermore, higher DAI and microscopic colitis scores were observed in the control colitis group. Considering all these data, it is well-confirmed that colitis was induced by DNBS in the mice.

Studies have revealed that treatment with probiotics (CHEN *et al.* 2019; DUARY *et al.* 2012; ISIDRO *et al.* 2017; ŠTOFILOVÁ *et al.* 2017) or ω -3 (CAMUESCO *et al.* 2005; REIFEN *et al.* 2015; TYAGI *et al.* 2012) affect the pro/anti-inflammatory cytokine balance by reducing the production of proinflammatory cytokines and by reducing mucosal inflammation during IBD. Although treatment with ω -3 appears to be beneficial for reducing inflammation in patients with IBD (CAMUESCO *et al.* 2005; REIFEN *et al.* 2015), several studies have demonstrated it fails to achieve its beneficial effects during IBD relapse (HAWTHORNE *et al.* 1992; TURNER *et al.* 2007). Therefore, we aimed to determine whether treatment of ω -3 in combination with VSL#3 could provoke its beneficial effects on reducing inflammation and upregulating cytokine balance, particularly during the relapse of IBD. A number of proinflammatory cytokines, including TNF- α , IL-6, IL-17A, and IFN- γ , are well-known for their roles in inducing inflammation-related gene expressions, thus triggering the inflammatory cascade and damaging colon tissue during the pathological progression of UC (BAUMGART & SANDBORN 2007; MUZES *et al.* 2012). Studies on UC patients have revealed that the colonic tissue concentrations of TNF- α and IL-6 are higher during the active phase compared to that in patients in remission (ATREYA & NEURATH 2005; BENTO *et al.* 2012). In this study, we observed that TNF- α concentrations were lower in all therapeutic groups than in the control colitis and non-colitis control groups. However, no meaningful difference

was detected in IL-6 levels among all experimental groups. The exact reason why tissue IL-6 expressions did not differ between groups is unclear. One explanation could be that it is related to the chronic experimental model applied in the study. IL-6 is a multifunctional cytokine that is of great importance on both pro- and anti-inflammatory responses (ATREYA & NEURATH 2005). While it is well-known that IL-6 expression by monocytes and macrophages increases sharply in response to any inflammatory condition to initiate mucosal immunity, its overexpression is often associated with uncontrolled inflammatory processes (ATREYA & NEURATH 2005; MUZES *et al.* 2012; TANAKA *et al.* 2014). In the present study, reactivation of DNBS-induced colitis may have caused a dysregulation of the IL-6 expression levels in the studied mice colon tissue.

In addition, IL-17A and IFN- γ are other proinflammatory cytokines characterized by their involvement in the pathogenesis of IBD (GÁLVEZ 2014; MUZES *et al.* 2012). It is known that T helper (Th) cells are responsible for the stimulation and release of these proinflammatory cytokines during IBD processes (GÁLVEZ 2014). We found that IL-17A and IFN- γ expression rates were higher in the control colitis group than in the control group without colitis. While IL-17A concentration did not differ between therapeutic support groups, IFN- γ levels were found to be lower in groups supplemented with VSL#3 alone and in combination with ω -3. One explanation for the similar results of IL-17A levels between treatment groups is that all therapeutic approaches may have similar favorable effects on the treatment of DNBS-induced colitis. However, the concentration of IL-10, an anti-inflammatory cytokine known for its therapeutic role in controlling inflammatory processes during IBD, was similar in all groups, inconsistent with other animal studies supplementing VSL#3. With all the results in mind, treatment with VSL#3, a probiotic supplement well characterized for its beneficial effect on regulating gut barrier function, anti-inflammatory cytokine expression, and gut microbial composition (CHENG *et al.* 2020; ISIDRO *et al.* 2017; SOOD *et al.* 2009), supplemented with ω -3 may provide beneficial results, including a significant decrease in TNF- α and IFN- γ . More work is required to elucidate the cytokine response during induction of chronic colitis.

Our results on histological examination, DAI, and microscopic scores shed light on determining mucosal barrier function and histopathological changes during chronic DNBS-induced colitis in mice. Mucosal damage characterized by infiltration of proinflammatory cells is one of the most common characteristics of UC. We found that co-administration of VSL#3 and ω -3 resulted in better morphologic outcomes, including the higher presence of crypt and goblet cells, indicating a lessening of tissue damage. These results are consistent with previous animal

studies suggesting a preservative role of VSL#3 (CHEN *et al.* 2019; ISIDRO *et al.* 2017; SOOD *et al.* 2009) or ω -3 (CAMUESCO *et al.* 2005; REIFEN *et al.* 2015; TYAGI *et al.* 2012) alone on decreasing macroscopic score and inflammation, and improving histopathology in IBD.

The protection of goblet cells during colitis prevents DNBS-induced colonic mucosal damage and increased inflammation, and increases their secretion, providing an intact mucosal membrane (GRONDIN *et al.* 2020). Goblet cell depletion and damaged cryptic structures are considered indicators of chronic inflammation during colitis (HENDRICKSON *et al.* 2002). In this study, all groups except VSL#3 plus ω -3 treatment showed a depletion of goblet cells and loss of cryptic structure, suggesting that co-administration of VSL#3 with ω -3 in mice with chronic colitis reduced the severity of mucosal damage and provided colonic maintenance.

Our findings need to be evaluated in light of potential limitations. Initially, although we started this study with fifty mice, we completed the study with five mice in the probiotic group and six in each of the other groups. It is important to note that the main cause of death was aspiration or both aspiration and colitis, not the treatment administered. Furthermore, the deaths did not affect the power analysis of the study, as we included 10 mice per group based on the expectation of 40% attrition from the experimental treatment in which chronic colitis was induced. Second, we did not analyze the gut microbiome composition. Further studies should include microbiome analysis using high-throughput sequencing technologies to better identify the gut microbiome and potential interactions between microbes and metabolic pathways while investigating the combined effect of ω -3 and probiotic supplementation during chronic colitis. Our study has many strengths. The inclusion of both a non-colitis control and control colitis group provided a better understanding of both the severity of colitis and the potential impact of therapeutic treatments. We administered both supplements at doses indicated as suitable for compliance in human studies. We applied a chronic colitis model involving reactivation of colitis. Since we know that chronic inflammation is common in IBD patients, the application of the chronic colitis model allowed us to obtain more realistic results.

Conclusion

Our findings showed that treatment with VSL#3 in combination with ω -3 significantly reduced mucosal damage, gastrointestinal disturbances, and histopathological change, thus significantly suppressing the severity of chronic DNBS-induced colitis. To our knowledge, this is the first study to include the appli-

cation of VSL#3 combined with ω -3 in a chronic colitis model. These findings suggest that this combined therapy may contribute as a complementary therapy in chronic colitis. However, further studies involving detailed analyses of cytokine response and microbiome samples are needed before they can be applied to human studies.

Funding

This project was supported by The Scientific and Technological Research Council of Turkey (TUBITAK) (Grand Number: 115S679, 2015).

Author Contributions

Research concept and design: H.Y.I., G.K., S.O.T.; Collection and/or assembly of data: H.Y.I., M.Y.G., I.K., E.M.O., U.K.; Data analysis and interpretation: H.Y.I., A.D.L., M.O., M.Y.G., I.K., E.M.O., U.K.; Writing the article: H.Y.I., G.K., A.D.L., M.O.; Critical revision of the article: H.Y.I., A.D.L., S.O.T.; Final approval of article: H.Y.I., G.K., A.D.L., M.O., M.Y.G., S.O.T., I.K., E.M.O., U.K.

Conflict of Interest

All authors read and approved the final version of the manuscript. The authors have no financial or personal conflicts of interest to declare.

References

- ABEGUNDE A.T., MUHAMMAD B.H., BHATTI O., ALI T. 2016. Environmental risk factors for inflammatory bowel diseases: Evidence based literature review. *World J Gastroenterology*. **22**: 6296-6317. <https://doi.org/10.3748/wjg.v22.i27.6296>
- ALATAB S., SEPANLOU S.G., IKUTA K., VAHEDI H., BISIGNANO C., SAFIRI S., GBD 2017 INFLAMMATORY BOWEL DISEASES COLLABORATORS. 2020. The global, regional, and national burden of inflammatory bowel disease in 195 countries and territories, 1990-2017: a systematic analysis for the Global Burden of Disease Study 2017. *The Lancet Gastroenterol. Hepatol*. **5**: 17-30. [https://doi.org/10.1016/S2468-1253\(19\)30333-4](https://doi.org/10.1016/S2468-1253(19)30333-4)
- ATREYA R., NEURATH M.F. 2005. Involvement of IL-6 in the pathogenesis of inflammatory bowel disease and colon cancer. *Clin. Rev. Allergy. Immunol*. **28**: 187-196. <https://doi.org/10.1385/CRIAI:28:3:187>
- BARBALHO S.M., GOULART R.D.A., QUESADA K., BECHARA M.D., DE CARVALHO A.D.C.A. 2016. Inflammatory bowel disease: Can omega-3 fatty acids really help? *Ann. Gastroenterol*. **29**: 37-43.
- BAUMGART D.C., SANDBORN W.J. 2007. Inflammatory bowel disease: clinical aspects and established and evolving therapies. *Lancet*. **12**: 1641-1657. [https://doi.org/10.1016/S0140-6736\(07\)60751-X](https://doi.org/10.1016/S0140-6736(07)60751-X)
- BENNETT J.M., REEVES G., BILLMAN G.E., STURMBERG J.P. 2018. Inflammation-nature's way to efficiently respond to all types of challenges: Implications for understanding and manag-

- ing “the epidemic” of chronic diseases. *Front. Med. (Lausanne)* **5**: 316. <https://doi.org/10.3389/fmed.2018.00316>
- BENTO A.F., LEITE D.F.P., MARCON R., CLAUDINO R.F., DUTRA R.C., COLA M., MARTINI A. C., CALIXTO J.B. 2012. Evaluation of chemical mediators and cellular response during acute and chronic gut inflammatory response induced by dextran sodium sulfate in mice. *Biochem. Pharmacol.* **84**: 1459-1469. <https://doi.org/10.1016/j.bcp.2012.09.007>
- CAMILLERI M. 2021. Human Intestinal Barrier: Effects of Stressors, Diet, Prebiotics, and Probiotics. *Clin. Transl. Gastroenterol.* **12**: e00308. <https://doi.org/10.14309/ctg.0000000000000308>
- CAMUESCO D., GÁLVEZ J., NIETO A., COMALADA M., RODRÍGUEZ-CABEZAS M.E., CONCHA A., XAUS J., ZARZUELO A. 2005. Dietary olive oil supplemented with fish oil, rich in EPA and DHA (n-3) polyunsaturated fatty acids, attenuates colonic inflammation in rats with DSS-induced colitis. *J. Nutr.* **135**: 687-694. <https://doi.org/10.1093/jn/135.4.687>
- CHARAN J., KANTHARIA N.D. 2013. How to calculate sample size in animal studies? *J. Pharmacol. Pharmacother.* **4**: 303-306. <https://doi.org/10.4103/0976-500X.119726>
- CHEN X., FU Y., WANG L., QIAN W., ZHENG F., HOU X. 2019. Bifidobacterium longum and VSL#3® amelioration of TNBS-induced colitis associated with reduced HMGB1 and epithelial barrier impairment. *Dev. Comp. Immunol.* **92**: 77-86. <https://doi.org/10.1016/j.dci.2018.09.006>
- CHENG F.S., PAN D., CHANG B., JIANG M., SANG L.X. 2020. Probiotic mixture VSL#3: An overview of basic and clinical studies in chronic diseases. *World J. Clin. Cases.* **8**: 1361-1384. <https://doi.org/10.12998/WJCC.V8.I8.1361>
- DIDUCH B.K. 2017. Gastrointestinal Conditions in the Female Athlete. *Clin. Sports Med.* **36**: 655-669. <https://doi.org/10.1016/j.csm.2017.06.001>
- DUARY R.K., BHAUSAHEB M.A., BATISH V.K., GROVER S. 2012. Anti-inflammatory and immunomodulatory efficacy of indigenous probiotic *Lactobacillus plantarum* Lp91 in colitis mouse model. *Mol. Biol. Rep.* **39**: 4765-4775. <https://doi.org/10.1007/s11033-011-1269-1>
- DURKIN L.A., CHILDS C.E., CALDER P.C. 2021. Omega-3 Polyunsaturated Fatty Acids and the Intestinal Epithelium – A Review. *Foods* **10**: 199. <https://doi.org/10.3390/foods10010199>
- GÁLVEZ J. 2014. Role of Th17 Cells in the Pathogenesis of Human IBD. *ISRN Inflamm.* **2014**: 928461. <https://doi.org/10.1155/2014/928461>
- GHOURI Y.A., RICHARDS D.M., RAHIMI E.F., KRILL J.T., JELINEK K.A., DUPONT A.W. 2014. Systematic review of randomized controlled trials of probiotics, prebiotics, and synbiotics in inflammatory bowel disease. *Clin. Exp. Gastroenterol.* **7**: 473-487. <https://doi.org/10.2147/CEG.S27530>
- GRONDIN J.A., KWON Y.H., FAR P.M., HAQ S., KHAN W.I. 2020. Mucins in Intestinal Mucosal Defense and Inflammation: Learning From Clinical and Experimental Studies. *Front. Immunol.* **11**: 2054. <https://doi.org/10.3389/fimmu.2020.02054>
- HAWTHORNE A.B., DANESHMEND T.K., HAWKEY C.J., BELLUZZI A., EVERITT S.J., HOLMES G.K.T., MALKINSON C., SHAHEEN M. Z., WILLIAMS J.E. 1992. Treatment of ulcerative colitis with fish oil supplementation: A prospective 12 month randomised controlled trial. *Gut.* **33**: 922-928. <https://doi.org/10.1136/gut.33.7.922>
- HENDRICKSON B.A., GOKHALE R., CHO J.H. 2002. Clinical aspects and pathophysiology of inflammatory bowel disease. *Clin. Microbiol. Rev.* **15**: 79-94. <https://doi.org/10.1128/CMR.15.1.79-94.2002>
- HOLMAN C., PIPER S.K., GRITTNER U., DIAMANTARAS A.A., KIMMELMAN J., SIEGERINK B., DIRNAGL U. 2016. Where Have All the Rodents Gone? The Effects of Attrition in Experimental Research on Cancer and Stroke. *PLoS Biol.* **14**: e1002331. <https://doi.org/10.1371/journal.pbio.1002331>
- HUSSEIN S.A., ABD ELAZEM M.B., MOSTAFA H.A. 2019. The potential anti-inflammatory effect of Omega-3 polyunsaturated fatty acids on experimentally induced ulcerative colitis in rats. *Benha Veterinary Medical Journal* **37**: 237-244.
- ISIDRO R.A., LOPEZ A., CRUZ M.L., GONZALEZ TORRES M.I., CHOMPRES G., ISIDRO A.A., APPELYARD C.B. 2017. The Probiotic VSL#3 Modulates Colonic Macrophages, Inflammation, and Microflora in Acute Trinitrobenzene Sulfonic Acid Colitis. *J. Histochem. Cytochem.* **65**: 445-461. <https://doi.org/10.1369/0022155417718542>
- KLEIN A., ELIAKIM R. 2010. Non steroidal anti-inflammatory drugs and inflammatory bowel disease. *Pharmaceuticals (Basel)*. **3**: 1084-1092. <https://doi.org/10.3390/ph3041084>
- LECHUGA S., IVANOV A.I. 2017. Disruption of the epithelial barrier during intestinal inflammation: Quest for new molecules and mechanisms. *Biochim. Biophys. Acta. Mol. Cell. Res.* **1864**: 1183-1194. <https://doi.org/10.1016/j.bbamcr.2017.03.007>
- LIU T., ZHANG L., JOO D., SUN S.C. 2017. NF- κ B signaling in inflammation. *Signal. Transduct Target. Ther.* **2**: 17023. <https://doi.org/10.1038/sigtrans.2017.23>
- MARCASON W. 2013. Probiotics: Where Do We Stand? *J. Acad. Nutr. Diet.* **113**: 1424. <https://doi.org/10.1016/j.jand.2013.08.010>
- MARTÍN R., CHAIN F., MIQUEL S., LU J., GRATADOUX J.-J., SOKOL H., VERDU E.F., BERCIK P., BERMUDEZ-HUMARAN L.G., LANGELLA P. 2014. The commensal bacterium *Faecalibacterium prausnitzii* is protective in DNBS-induced chronic moderate and severe colitis models. *Inflamm. Bowel Dis.* **20**: 417-430. <https://doi.org/10.1097/01.MIB.0000440815.76627.64>
- MARTON L.T., GOULART R. DE A., CARVALHO A.C.A. DE, BARBALHO S.M. 2019. Omega fatty acids and inflammatory bowel diseases: An overview. *Int. J. Mol. Sci.* **20**: 4851. <https://doi.org/10.3390/ijms20194851>
- MATSUOKA K., KOBAYASHI T., UENO F., MATSUI T., HIRAI F., INOUE N., KATO J., KOBAYASHI K., KOBAYASHI K., KOGANEI K., KUNISAKI R., MOTOYA S., NAGAHORI M., NAKASE H., OMATA F., SARUTA M., WATANABE T., TANAKA T., KANAI T., NOGUCHI Y., TAKAHASHI K.I., WATANABE K., HIBI T., SUZUKI Y., WATANABE M., SUGANO K., SHIMOSEGAWA T. 2018. Evidence-based clinical practice guidelines for inflammatory bowel disease. *J. Gastroenterol.* **53**: 305-353. <https://doi.org/10.1007/s00535-018-1439-1>
- MORAMPUDI V., BHINDER G., WU X., DAI C., SHAM H.P., VALANCE B.A., JACOBSON K. 2014. DNBS/TNBS colitis models: providing insights into inflammatory bowel disease and effects of dietary fat. *J. Vis. Exp.* **27**: e51297. <https://doi.org/10.3791/51297>
- MURTHY S.N.S., COOPER H.S., SHIM H., SHAH R.S., IBRAHIM S.A., SEDERGRAN D.J. 1993. Treatment of dextran sulfate sodium-induced murine colitis by intracolonic cyclosporin. *Dig. Dis. Sci.* **38**: 1722-1734. <https://doi.org/10.1007/BF01303184>
- MUZES G., MOLNÁR B., TULASSAY Z., SIPOS F. 2012. Changes of the cytokine profile in inflammatory bowel diseases. *World J. Gastroenterol.* **18**: 5848-5861. <https://doi.org/10.3748/wjg.v18.i41.5848>
- NATIONAL RESEARCH COUNCIL (US) COMMITTEE. 2011. Guide for the Care and Use of Laboratory Animals. National Academies Press, USA. <https://doi.org/10.17226/12910>
- OBERMEIER F., KOJOUHAROFF G., HANS W., SCHÖLMEIER J., GROSS V., FALK W. 1999. Interferon-gamma (IFN- γ)- and tumour necrosis factor (TNF)-induced nitric oxide as toxic effector molecule in chronic dextran sulphate sodium (DSS)-induced colitis in mice. *Clin. Exp. Immunol.* **116**: 238-245. <https://doi.org/10.1046/j.1365-2249.1999.00878.x>
- PARKER E.A., ROY T., D'ADAMO C.R., WIELAND L.S. 2018. Probiotics and gastrointestinal conditions: An overview of evidence from the Cochrane Collaboration. *Nutrition.* **45**: 125-134.e11. <https://doi.org/https://doi.org/10.1016/j.nut.2017.06.024>
- PENNER R., FEDORAK R.N., MADSEN K.L. 2005. Probiotics and nutraceuticals: non-medicinal treatments of gastrointestinal diseases. *Curr. Opin. in Pharmacol.* **5**: 596-603. <https://doi.org/10.1016/J.COPH.2005.06.009>
- PLATANITIS E., DECKER T. 2018. Regulatory networks involving STATs, IRFs, and NF κ B in inflammation. *Front. Immunol.* **9**: 2542. <https://doi.org/10.3389/fimmu.2018.02542>

- RANDHAWA P.K., SINGH K., SINGH N., JAGGI A.S. 2014. A review on chemical-induced inflammatory bowel disease models in rodents. *Korean J. Physiol Pharmacol.* **18**: 279-288. <https://doi.org/10.4196/kjpp.2014.18.4.279>
- REAGAN-SHAW S., NIHAL M., AHMAD N. 2008. Dose translation from animal to human studies revisited. *FASEB. J.* **22**: 659-661. <https://doi.org/10.1096/fj.07-9574lsf>
- REIFEN R., KARLINSKY A., STARK A.H., BERKOVICH Z., NYSKA A. 2015. α -Linolenic acid (ALA) is an anti-inflammatory agent in inflammatory bowel disease. *J. Nutr. Biochem.* **26**: 1632-1640. <https://doi.org/10.1016/j.jnutbio.2015.08.006>
- SINGH R., CHANDRASHEKHARAPPA S., BODDULURI S.R., BABY B.V., HEGDE B., KOTLA N.G., HIWALE A.A., SAIYED T., PATEL P., VIJAY-KUMAR M., LANGILLE M.G.I., DOUGLAS G.M., CHENG X., ROUCHKA E.C., WAIGEL S.J., DRYDEN G.W., ALATASSI H., ZHANG H.G., HARIBABU B., VEMULA P.K., JALA V.R. 2019. Enhancement of the gut barrier integrity by a microbial metabolite through the Nrf2 pathway. *Nature Communications* **10**: 1-18. <https://doi.org/10.1038/s41467-018-07859-7>
- SOOD A., MIDHA V., MAKHARIA G.K., AHUJA V., SINGAL D., GOSWAMI P., TANDON R.K. 2009. The Probiotic Preparation, VSL#3 Induces Remission in Patients With Mild-to-Moderately Active Ulcerative Colitis. *Clin. Gastroenterol. Hepatol.* **7**: 1202-1209. <https://doi.org/10.1016/j.cgh.2009.07.016>
- SOYTURK M., SAYGILI S.M., BASKIN H., SAGOL O., YILMAZ O., SAYGILI F., AKPINAR H. 2012. Effectiveness of Saccharomyces boulardii in a rat model of colitis. *World. J. Gastroenterol.* **18**: 6452-6460. <https://doi.org/10.3748/wjg.v18.i44.6452>
- ŠTOFILOVÁ J., LANGERHOLC T., BOTTA C., TREVEN P., GRADIŠNIK L., SALAJ R., SOLTESOVA A., BERTKOVA I., HERTELYOVA Z., BOMBA A. 2017. Cytokine production in vitro and in rat model of colitis in response to *Lactobacillus plantarum* LS/07. *Biomed. Pharmacother.* **94**: 1176-1185. <https://doi.org/10.1016/j.biopha.2017.07.138>
- TANAKA T., NARAZAKI M., KISHIMOTO T. 2014. IL-6 in inflammation, immunity, and disease. *Cold. Spring. Harb. Perspect. Biol.* **6**: 16295-16296. <https://doi.org/10.1101/cshperspect.a016295>
- TRIPATHI K., FEUERSTEIN J.D. 2019. New developments in ulcerative colitis: Latest evidence on management, treatment, and maintenance. *Drugs. Context.* **8**: 212572. <https://doi.org/10.7573/dic.212572>
- TURNER D., STEINHART A.H., GRIFFITHS A.M. 2007. Omega 3 fatty acids (fish oil) for maintenance of remission in ulcerative colitis. *Cochrane Database of Systematic Reviews. Inflamm. Bowel. Dis.* **17**: 336-345. <https://doi.org/10.1002/14651858.CD006443.pub2>
- TYAGIA A., KUMAR U., REDDY S., SANTOSH V.S., MOHAMMED S.B., EHTESHAM N.Z., IBRAHIM A. 2012. Attenuation of colonic inflammation by partial replacement of dietary linoleic acid with α -linolenic acid in a rat model of inflammatory bowel disease. *Br. J. Nutr.* **108**: 1612-1622. <https://doi.org/10.1017/S0007114511007197>
- ZUO T., NG S.C. 2018. The Gut Microbiota in the Pathogenesis and Therapeutics of Inflammatory bowel disease. *Front. Microbiol.* **9**: 2247. <https://doi.org/10.3389/fmicb.2018.02247>

Copyright of *Folia Biologica* is the property of Polish Academy of Sciences, Institute of Systematics & Evolution of Animals and its content may not be copied or emailed to multiple sites or posted to a listserv without the copyright holder's express written permission. However, users may print, download, or email articles for individual use.