

A brief report: Cerebrospinal fluid rhinorrhea after repetitive nasal swab testing for coronavirus disease 2019(COVID-19)

Mesut Yılmaz^a, Zeynep Bahadır^{b,*}, Berk Madendere^b, Rıza Taha Yüksel^b, Hasan Gökay^b, Ahmet Alperen Yiğitbaşı^b

^a Istanbul Medipol University, Faculty of Medicine, Department of Infectious Diseases and Clinical Microbiology, Turkey

^b Istanbul Medipol University, Faculty of Medicine, Turkey

ARTICLE INFO

Keywords:

Cerebrospinal Fluid Rhinorrhea
RT-PCR
SARS-COV-2
COVID-19
nasal swab test
Rhinorrhea

ABSTRACT

For the past year, COVID-19 Pandemic has been the biggest focal point of medicine. Due to its novelty and its highly infectious nature, the impact of Sars-Cov-2 on society has been growing rapidly. The primary route for prevention of this highly infectious virus is detection. The detection methods for Sars-Cov-2 include nasal swab tests, saliva samplings and antibody tests. The main preferred method has been the RT-PCR with Nasal Swab sampling which is performed on the nasopharyngeal region. However, the nasal swab testing may come with its own iatrogenic outcomes due to its invasiveness. In this report, we describe a rare case of iatrogenic unilateral cerebrospinal fluid rhinorrhea which occurred due to repetitive nasal swab testing for COVID-19.

Introduction

Sars-Cov-2 is an enveloped, positive-stranded RNA virus that is responsible for the global outbreak of Coronavirus disease (COVID-19) which was declared as a pandemic on March 11, 2020 by World Health Organization (WHO) [1]. Diagnostic tests such as RT-PCR are used to detect active cases and therefore to prevent the spread of the infection [2]. The U.S Centers for Disease Control and Prevention recommends a nasal swab test, however, a throat swab test or a saliva sample is also acceptable for the RT-PCR test [3]. To date, only one case has been reported with cerebrospinal fluid (CSF) rhinorrhea due to nasal swab testing for COVID-19⁴. We present a 47-year-old male patient with CSF rhinorrhea due to repetitive nasal swab testing for COVID-19. The aim of this report is to inform the medical community about the potential risks of frequent nasal swabbing and raise awareness on the importance of using other sampling methods for befitting cases.

Case report

A 47-year-old male was admitted with a right-sided rhinorrhea and headache. The patient had been tested for COVID-19 four times within the span of the previous month. Following the first swab test, the patient

reported some minor fluid leak from his right nasal cavity. Three days after the last nasal swab test, the dripping developed into massive fluid leak following a sneeze. The patient had a medical history of a minor head trauma which occurred 4 years ago, however, the patient did not seek any medical assistance and did not suffer from any symptoms. The physical examination showed leakage of a clear fluid from the right nasal cavity. We have suspected a CSF leak due to the fluid's characteristics and amount. The CT scan detected normal neural parenchyma along with pneumocephalus (Figures A and B). The paranasal sinus CT (Figure A) showed intracranial air passage which was directly related to right superior nasal meatus and proved the physician's suspicions of a CSF Leak (Figure C). Only a paranasal and cerebral CT scan could be performed for screening since performing a prone positioned MRI resulted in an increase in pneumocephalus and rhinorrhea. The patient was admitted to the hospital for an endoscopic transnasal surgery. During the surgery, a bone defect was identified at the right fovea ethmoidalis. The defect was repaired with synthetic dura mater and was supported with a nasoseptal flap. The operation was conducted without any complications and the patient was admitted for post-operative care. The patient did not report any complaints or discomfort and is doing fine 2 months after the procedure.

* Corresponding author.

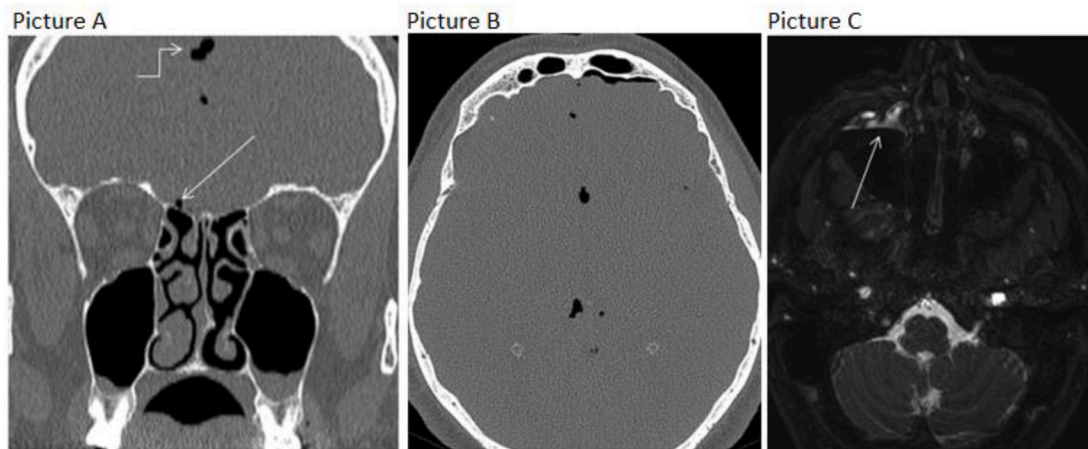
E-mail address: zbahadir@icloud.com (Z. Bahadır).

<https://doi.org/10.1016/j.xocr.2021.100313>

Received 5 April 2021; Accepted 11 May 2021

Available online 18 June 2021

2468-5488/© 2021 Published by Elsevier Inc. This is an open access article under the CC BY-NC-ND license (<http://creativecommons.org/licenses/by-nc-nd/4.0/>).



Paranasal sinuses CT: a) coronal bone window, showing intracranial air passage from small bony defect in right foveal ethmoidalis (thin arrow) b) axial bone window, diffuse pneumocephalus c) axial B-FFE sequence, CSF collection in prone position leveling in the right maxillary sinus (thin arrow).

Discussion

CSF leaks are usually divided into non-traumatic and traumatic. Traumatic leaks are more commonly encountered and can be iatrogenic following anterior skull base and endoscopic sinus surgery (ESS) or non-iatrogenic due to skull base trauma [5]. CSF rhinorrhea stays a rare complication of ESS with a less than 1% occurrence-rate [6].

To our knowledge, there has been only one case of an iatrogenic unilateral CSF rhinorrhea due to RT-PCR sampling method which was used for COVID-19 diagnosis and the patient was a 40-year-old woman with a nasal operation history, encephalocele and pseudomeningocele [4]. Our case had repetitive and frequent nasopharyngeal swab sampling and had a history of minor head trauma 4 years prior to his first RT-PCR testing. We speculate that the unilateral right-sided CSF leak was primarily caused by repetitive nasal swab testing, unlike the previously reported case who had predisposing factors such as undiagnosed congenital skull base defect [7]. The certainty of our speculation stays limited since no medical report or radiological imagery of the minor head trauma which occurred 4 years ago was available for further inspection. However, the fact that the patient was never diagnosed with a congenital skull base defect and did not require any medical assistance or show any symptoms following the past trauma strengthen our position on the case. Even though nasal swab sampling has become a reliable source of a diagnostic tool during COVID-19 pandemic, this case of CSF leak shows that nasopharyngeal swab testing can lead to iatrogenic outcomes due to its invasiveness. As it is inevitable for this adverse event to recur in the future, nasal swab sampling should be reconsidered to be performed on patients with prior surgical intervention such as sinus or skull base surgery, conditions that distorts normal nasal anatomy, prior skull base defects, or predisposing conditions to skull base erosion. A less

invasive approach such as saliva or throat swab samplings could be safer and preferable in such cases. A recent study from Yale School of Medicine comparing nasal swab samples to saliva specimens suggested that more SARS-CoV-2 RNA copies in the saliva specimens are detected than in the nasopharyngeal swab specimens and they have at least similar sensitivity in the detection of SARS-CoV-2 during the course of hospitalization, thus making the saliva sampling method more viable in susceptible cases [8]. This report aims to encourage the medical community to question the patients' pre-existing conditions and medical history in order to assess the risk of adverse effects of nasal swab sampling prior to the procedure and use another sampling method if such risks are present.

Declaration of competing interest

The authors declare that they have no known competing financial interests or personal relationships that could have appeared to influence the work reported in this paper.

References

- [1] Cucinotta D, Vanelli M. WHO declares COVID-19 a pandemic. *Acta Biomed* 2020;91(1):157–60.
- [2] Organization WH. COVID-19 strategic preparedness and response plan. *World Health Organization*; 12 February 2020 2020.
- [3] Interim guidelines for collecting, handling, and testing clinical specimens for COVID-19. Centers for Disease Control and Prevention (CDC) 2020. Accessed, <https://www.cdc.gov/coronavirus/2019-ncov/lab/guidelines-clinical-specimens.html>. [Accessed October 2020].
- [4] Sullivan CB, Schwalje AT, Jensen M, et al. Cerebrospinal fluid leak after nasal swab testing for Coronavirus disease 2019. *JAMA Otolaryngol Head Neck Surg* 2020;146(12):1179–81.
- [5] Prosser JD, Vender JR, Solares CA. Traumatic cerebrospinal fluid leaks. *Otolaryngol Clin* 2011;44(4):857–73.
- [6] Sharma SD, Kumar G, Bal J, Eweiss A. Endoscopic repair of cerebrospinal fluid rhinorrhoea. *Eur Ann Otorhinolaryngol Head Neck Dis* 2016;133(3):187–90.
- [7] Sullivan CB, Schwalje AT, Jensen M, et al. Cerebrospinal fluid leak after nasal swab testing for Coronavirus disease 2019. *JAMA Otolaryngol Head Neck Surg* 2020;146(12):1179–81.
- [8] Wyllie AL, Fournier J, Casanovas-Massana A, et al. Saliva or nasopharyngeal swab specimens for detection of SARS-CoV-2. *N Engl J Med* 2020;383(13):1283–6.