

# Fibula Allograft Sandwich Technique for the Reconstruction of Sternal Nonunion After Cardiac Surgery

Cihangir Ersoy, MD, Arda Özyüksel, MD, Melih Malkoç, MD, Bekir Kayhan, MD, Ekin Kayan, MD, Atif Akçevin, MD, and Halil Türkoğlu, MD

Department of Cardiovascular Surgery, Medipol University; and Department of Orthopedics and Traumatology, Medipol University, Istanbul, Turkey

Sternal dehiscence is an untoward complication of cardiac surgery that leads to increased morbidity as well as length of hospital stay and costs. Although many different conventional and creative techniques have been described using both synthetic and biologic materials, the ideal method of sternal reconstruction is still controversial. In this case, we describe a simple and reproducible “fibula allograft

sandwich technique” for the reconstruction of sternal nonunion in a cardiac surgery patient. This technique also facilitates the conventional wiring by creating bilateral landing zones for the wires at both sides of the sternum.

(Ann Thorac Surg 2014;98:e51–3)

© 2014 by The Society of Thoracic Surgeons

**M**echanical instability of the sternum in the postoperative period in a cardiac surgery patient is an untoward complication with significant morbidity. Although the conventional repair of the median sternotomy with 6 or more stainless-steel wires either in a simple interrupted or figure-of-eight fashion, up to 3% of the patients develop sternal nonunion [1]. The risk factors for sternal nonunion are broadly classified as preoperative, intraoperative, and postoperative. The preoperative factors include the preexisting patient factors such as diabetes mellitus, obesity, chronic obstructive pulmonary disease, osteoporosis, and radiation to the chest [2]. The intraoperative risk factors for sternal nonunion are mainly the technical errors such as paramedian (off-midline) sternotomy, harvest of bilateral internal thoracic arteries for grafting, and mechanical failure [2, 3]. Postoperatively, prolonged mechanical ventilation, impaired cardiac output, and closed chest massage for cardiopulmonary resuscitation are the important risk factors associated with increased sternal complications [1]. Different techniques and materials have been reported in literature for sternal reconstruction. We proposed a simple and reproducible technique using fibula allografts for the reconstruction of sternal nonunion after cardiac surgery. This is the first patient per our literature search (Pubmed search performed May 2014 with the keywords fibula, sternum, nonunion) with fibular allograft sandwich technique for the reconstruction of sternal dehiscence.

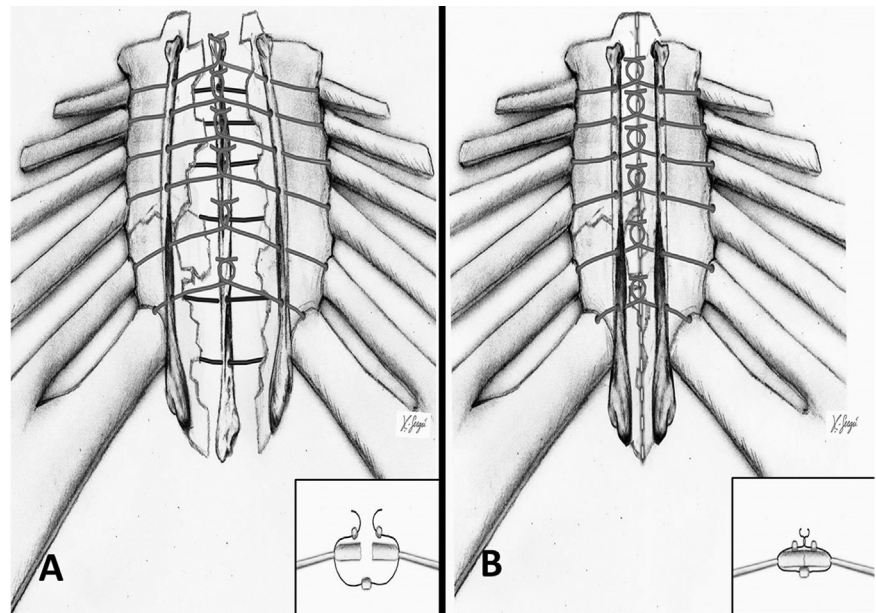
Accepted for publication May 14, 2014.

Address correspondence to Dr Özyüksel, Department of Cardiovascular Surgery, Medipol University, Medipol Mega Hospital, TEM Goztepe Cikisi No: 1, 34214, Bagcilar, Istanbul, Turkey; e-mail: [ozyukselarda@yahoo.com](mailto:ozyukselarda@yahoo.com).

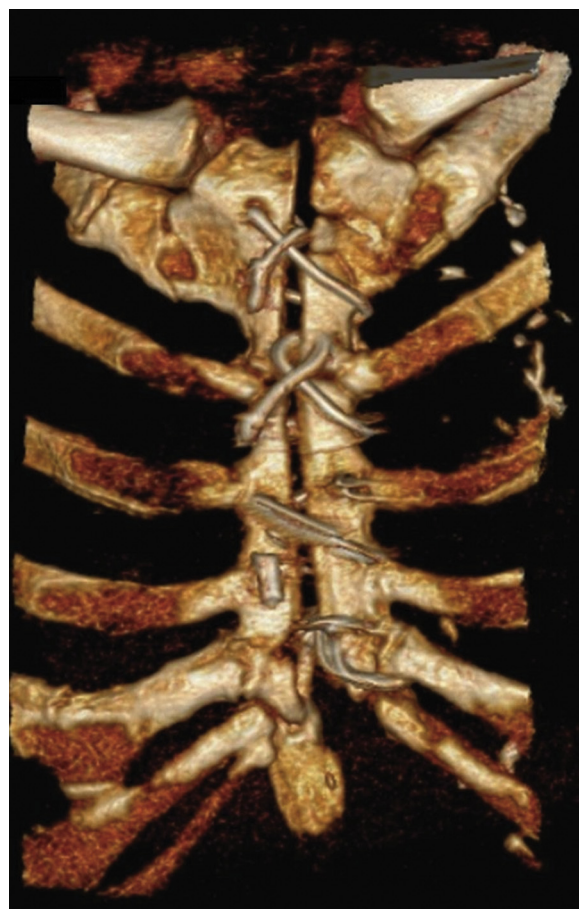

Fig 1. Three-dimensional computed tomography demonstrates the sternal nonunion with the wires cutting the bone.

Fig 2. Illustrations demonstrating the fibula allograft sandwich technique (the inlet figures demonstrate the technique cross-sectionally). (A) The allografts are located and wires are passed through the holes and sternocostal junctions. (B) Then the wires are looped and the allografts are positioned at an appropriate strength.



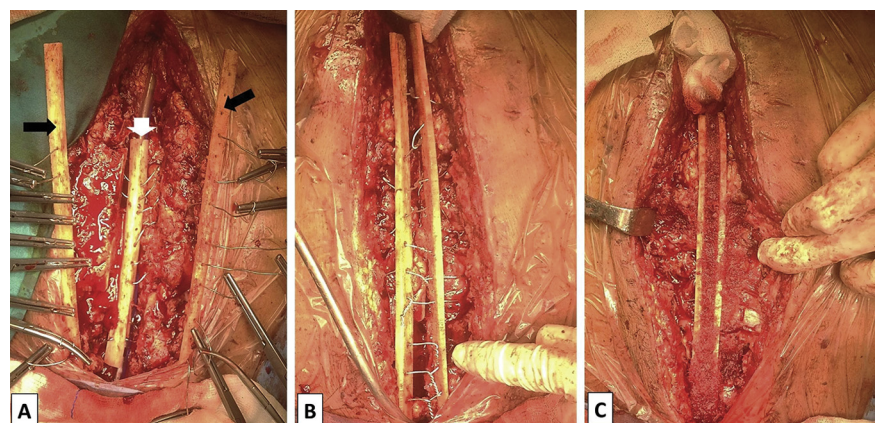
### Technique

The patient is a 77-year-old man with type 2 diabetes mellitus and chronic obstructive pulmonary disease who underwent coronary artery bypass surgery (body weight, 91 kg; body mass index, 30.5). Four saphenous vein grafts and the left internal thoracic artery graft were anastomosed to 5 target vessels. The postoperative course was complicated with respiratory insufficiency leading to prolonged mechanical ventilation. After the extubation of the patient at the fourth postoperative day, he was supported with continuous positive airway pressure. Two weeks postoperatively he began to experience sternal pain and a click. Although sternal stabilization was provided with the sternum corset, his complaints gradually increased.

The computed tomography demonstrated the complete sternal nonunion (Fig 1). There was no clinical or

laboratory evidence of mediastinal infection during this period. The patient was operated once more in order to ensure the sternal integrity with regard to his pain and its debilitating effects. The figure-of-eight no. 7 caliber stainless-steel wires were observed to cut the sternal edges, leading to multiple transverse fractures and loss of bone tissue. Cultures were taken which were later reported to be sterile. The sternum and the fractured bone fragments were trimmed until a bleeding healthy tissue was observed. Three fibula allografts with the length of 25 cm and the thickness of 0.5 cm were prepared. These grafts had been produced from organ donors under sterile conditions. After the washing procedure with antibiotics and sterile saline solutions, they were packed and stored at  $-80^{\circ}\text{C}$ . At the day of usage, they are defrosted at  $4^{\circ}\text{C}$  and immersed in saline solution until the time of implantation.

Fig 3. Operative view of the patient. (A) Two fibula allografts are placed laterally on the anterior side of the sternum (black arrows) and 1 at the posterior side (white arrow). The interrupted caliber no.7 wires are passed through (B) the allografts and (C) the sternum.



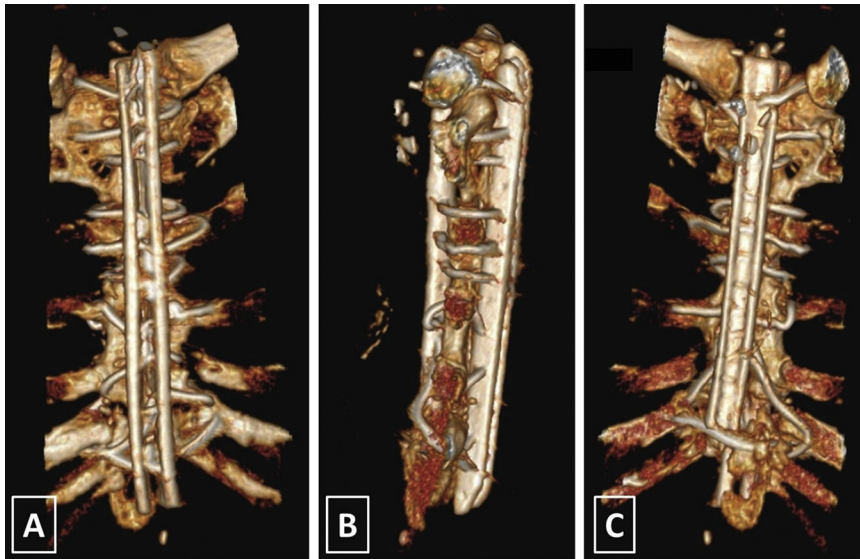


Fig 4. Three-dimensional computed tomography after the sternal reconstruction with (A) anterior, (B) lateral, and (C) posterior projections.

Multiple holes were opened on the allografts with the aid of a 2.7-mm drill. Two of the fibula allografts were positioned anteriorly and another one was placed posterior to the sternum in a parallel fashion to the long axis of the bone. Afterwards, no. 7 caliber stainless-steel wires were passed at the remnants of the sternocostal junctions and through the holes on the fibula allografts, producing a sandwich-like shape. After completing the wiring process, the loops of the wires were fixed at an appropriate strength. [Figures 2\(A;B\)](#) and [3\(A-C\)](#) demonstrate the illustration and operative view of the technique, respectively.

The patient did well postoperatively. The postoperative computed tomography demonstrated the intact sternal edges without any sign of nonunion ([Figs 4A-C](#)). He was free of symptoms 8 weeks after the second surgical intervention.

## Comment

Multiple methods and devices for sternal reconstruction have been reported in literature. The conventional Robicsek weave has been widely accepted in current clinical practice; however, in failed attempts for sternal repair more creative combinations of traditional wiring methods with some instruments and supportive materials are necessary [\[4, 5\]](#). Different techniques for chest wall reconstruction have been described using the synthetic or biologic materials. The major disadvantages of the implantation of synthetic materials are excessive rigidity with the risk of erosion of the adjacent structures, risk of infection, risk of migration, insufficient strength, immunologic reaction, and impossibility of incorporation into the host tissue [\[6\]](#). The main advantage of the bone allografts are the optimal mechanical properties and biocompatibility. Bone grafts include the osteoprogenitor cells with the possibility of new bone tissue formation [\[6\]](#). Homologous ileac and sternal allografts have been described in literature for the reconstruction of sternum mainly in

cases with malignancy [\[7, 8\]](#). In this case we preferred the bone allograft in order to achieve a reliable and durable sternal integrity with the lowest risk of infection in an obese patient with diabetes mellitus.

In conclusion, we developed the fibular allograft sandwich technique, which is simple and reproducible. We also believe that the longitudinally positioned fibula allografts provide a safe and durable landing zone for the circumferential sternal wires, which resembled the function and the manner of the long axis parasternal wires described by Robicsek [\[4\]](#). Although this technique provided excellent functional result in our patient in the early postoperative period, further studies are mandatory in order to evaluate the long-term results of this technique.

## References

1. Chepla KJ, Salgado CJ, Tang CJ, Mardini S, Evans KK. Late complications of chest wall reconstruction: management of painful sternal nonunion. *Semin Plast Surg* 2011;25:98-106.
2. El Oakley RM, Wright JE. Postoperative mediastinitis: classification and management. *Ann Thorac Surg* 1996;61:1030-6.
3. Gorlitzer M, Wagner F, Pfeiffer S, et al. A prospective randomized multicenter trial shows improvement of sternum related complications in cardiac surgery with the Posthorax support vest. *Interact Cardiovasc Thorac Surg* 2010;10:714-8.
4. Robicsek F, Daugherty HK, Cook JW. The prevention and treatment of sternum separation following open-heart surgery. *J Thorac Cardiovasc Surg* 1977;73:267-8.
5. Rocco G. Overview on current and future materials for chest wall reconstruction. *Thorac Surg Clin* 2010;20:559-62.
6. Marulli G, Hamad AM, Cogliati E, Breda C, Zuin A, Rea F. Allograft sternochondral replacement after resection of large sternal chondrosarcoma. *J Thorac Cardiovasc Surg* 2010;139:e69-70.
7. Ren P, Zhang J, Zhang X. Resection of primary sternal osteosarcoma and reconstruction with homologous iliac bone: case report. *J Formos Med Assoc* 2010;109:309-14.
8. Dell'Amore A, Cassanelli N, Dolci G, Stella F. An alternative technique for anterior chest wall reconstruction: the sternal allograft transplantation. *Interact Cardiovasc Thorac Surg* 2012;15:944-7.