



Loculated Pericardial Effusion Successfully Managed with A Right Parasternal Pericardiocentesis

Loküle Perikart Efüzyonunun Sağ Parasternal Perikardiyosentez ile Başarılı Tedavisi

Mustafa Adem Tatlısu¹, Emrah Bozbeyoğlu², Bülent Aydemir³, Zekeriya Nurkalem⁴

¹ Sivas Numune Hospital, Clinic of Cardiology, Sivas, Turkey

² Dr. Siyami Ersek Cardiovascular Surgery Center, Clinic of Cardiology, İstanbul, Turkey

³ Dr. Siyami Ersek Cardiovascular Surgery Center, Clinic of Cardiovascular Surgery, İstanbul, Turkey

⁴ Medipol University Faculty of Medicine, Department of Cardiology, İstanbul, Turkey

A 46-year-old woman with a previous diagnosis of inoperable stage IV small cell lung cancer presented to the emergency department with shortness of breath. Physical examination showed a pale woman who appeared malnourished. Her vital signs were as follows: pulse rate 115 beats/min, respiration rate 22 breaths/min, body temperature 37.5°C, and blood pressure 95/65 mm Hg. Breath sounds were diminished on the left base and widespread coarse crackles were heard over the left lung. Other system examination findings were within normal limits. A 12-lead electrocardiogram showed sinus tachycardia and lower voltage without marked ST changes. A chest X-ray showed infiltrates on the left upper zones, and a large left-sided pleural effusion (Figure 1A). Transthoracic echocardiography (TTE) showed a large loculated pericardial effusion measuring 3.2 cm in maximal width on the right side of the heart with cardiac tamponade, which was also confirmed by multislice computed tomography (Figure 1B). Due to the increased risk of general anesthesia, we preferred an echocardiography-guided pericardiocentesis using the parasternal window. As the loculated pericardial effusion was adjacent to the right atrium and ventricle, the right parasternal

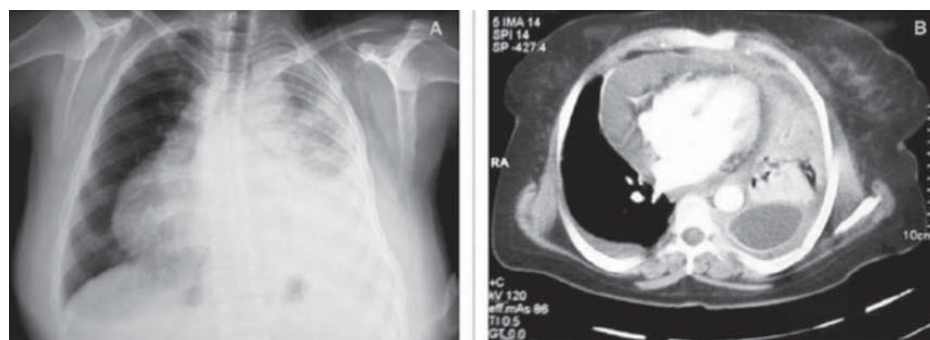


Figure 1. (A) A chest X-ray shows infiltrates on the left upper zones and a large left-sided pleural effusion. (B) Multislice computed tomography shows a large loculated pericardial effusion on the right side of the heart.

approach was chosen. Echocardiography-guided pericardiocentesis was performed under local anesthesia in the operating room owing to the increased risk for pneumothorax. A puncture needle was advanced through the sixth intercostal space at the right parasternal border, and nearly 600 mL of hemorrhagic fluid was aspirated (Figure 2). After pericardiocentesis, the patient's vital signs were as follows: pulse rate 85 beats/min, respiration rate 19 breaths/min, body temperature 37.5°C, and blood pressure 115/75 mm Hg. A very small amount of pericardial effusion was seen during TTE. The fluid cytology was compatible with metastatic disease. She died from respiratory failure three months after the procedure. Pericardiocentesis via the right parasternal approach can be used in a patient with severe comorbidity.

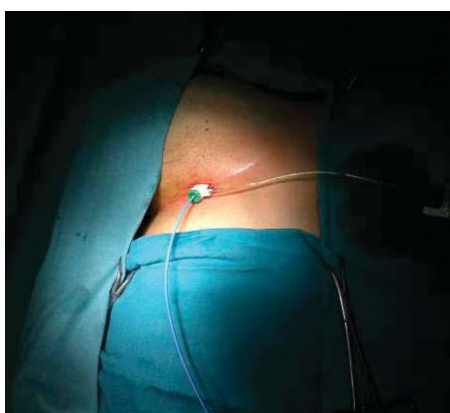

Figure 2. Pericardiocentesis via the right parasternal approach.

Correspondence

Mustafa Adem Tatlısu

E-mail: ademtatlısu@gmail.com

Submitted: 06.07.2015

Accepted: 28.09.2015

@ Copyright 2015 by Koşuyolu Heart Journal.
Available on-line at
www.kosuyoluheartjournal.com