

ORIGINAL ARTICLE

Pyogenic Granuloma of the Vermillion: Surgical Treatment of Lip Vermilion, and its Outcomes

Alpay Duran¹, Aslı Duran², Tuğba Dindar³, Hasan Dindar⁴

¹Department of Plastic Surgery, Avicenna Hospital, Istanbul, Turkey

²Department of Dermatology, Kosuyolu Medipol Hospital, Istanbul, Turkey

³Department of Plastic Surgery, Tekirdag State Hospital, Tekirdag, Turkey

⁴Department of Pathology, Namik Kemal University Faculty of Medicine, Tekirdag, Turkey

Abstract

Introduction: This study aims to retrospectively analyze the features and treatment of pyogenic granuloma of the vermilion border of the lip.

Methods: Information regarding 16 cases of pyogenic granuloma of the vermilion border of the lips that underwent biopsy was retrieved from the pathology records of patients seen at the Plastic Surgery Department of Sanliurfa Mehmet Akif Inan Training and Research Hospital and Dermatology Department of Sanliurfa Balıklıgöl State Hospital. Data were reviewed and analyzed for age, gender, lesion site and diameter, treatments, recurrence and clinical features.

Results: Sixteen patients (12 female (75%) and four (25%) male patients) were included in this study. The ages of the patients ranged from 14 to 42 years (mean age: 26.25). In nine of the cases (56%), the bleeding was the most obvious complaint. Seven cases (43%) referred to our clinics for cosmetic reasons. There were three cases under 16 years of age (18%). Fourteen lesions (87.5%) were located on the lower lip, two lesions (12.5%) on the upper lip. The duration of complaints of the patients varies between two weeks and six months (mean: five weeks). The average follow-up period was 13 months (6-17 months). Complications and recurrences did not develop in any case after the operation.

Discussion and Conclusion: The advantages of surgical excision are allowing the removal of the lesion in one session and the low recurrence rate. We recommend surgical excision for the treatment of pyogenic granulomas located on vermilion because it permits complete histopathologic examination considering that ulcerous and hemorrhagic lesions may be associated with malignancy and various diseases.

Keywords: Excision; lip; pyogenic granuloma; recurrence; vermilion.

Pyogenic granuloma (PG) appears as a fast-growing, solitary and vascular nodule that occurs on the skin or mucous membranes, often prone to ulceration or bleeding^[1–5]. Although its exact etiology is not known, there are theories that PG may be associated with factors, such as female sex hormones, minor traumas, chronic wound and viral infections^[5].

In the studies reported in previous years, various treatment methods have been reported in the treatment of PGs of the vermilion of the lips^[6–12]. Since the majority of these studies are case reports, the scarce number of relevant cases available in other studies, and the authors have advocated their own treatment options, divergence about choosing the appropriate treatment approach for PGs located in this


Correspondence (İletişim): Alpay Duran, M.D. Avicenna Hastanesi, Plastik Cerrahi Kliniği, Istanbul, Turkey

Phone (Telefon): +90 536 625 35 89 **E-mail (E-posta):** dr.alpayduran@hotmail.com

Submitted Date (Başvuru Tarihi): 20.03.2018 **Accepted Date (Kabul Tarihi):** 08.10.2018

Copyright 2020 Haydarpaşa Numune Medical Journal

OPEN ACCESS This is an open access article under the CC BY-NC license (<http://creativecommons.org/licenses/by-nc/4.0/>).



region exists. In addition, in some cases of vermilion, after the application of some treatment options, problems, such as excessive bleeding, lack of complete response, and recurrences, may develop^[10–12].

In the light of this information, this study aims to evaluate the effectiveness of the electrocauterization of the wound bed following conventional surgical excision in the treatment of PGs located on the lower and upper lip vermilions and to examine the properties of the PGs located in this region.

Materials and Methods

This retrospective study was carried out between April 2016 and July 2017 in Şanlıurfa Mehmet Akif Inan Training and Research Hospital, Plastic, and Reconstructive Surgery and Şanlıurfa Balıklığıol State Hospital Dermatology outpatient clinics and 16 cases with PG reported in the pathology reports after surgical excision were included in this study.

PG patients included in this study underwent full elliptical excision after perilesional infiltration anesthesia (2% lidocaine and 1: 100.000 epinephrine), and following excision surgical wound beds were cauterized with electrocautery (Petas-PETKOT 500s, Turkey). The defects formed in vermilion were closed with the primary repair or vermilion advancement flaps using 5/0 rapid absorbable sutures (Vicryl Rapide; Ethicon Inc) to obtain esthetically good results considering the anatomical location and the size of the defect. The data of the cases were analyzed and age, gender,

admission complaints, lesion diameter, its anatomical location, surgical treatment, treatment results and development of recurrence (if any) were evaluated. Patients were called for control in the 3rd week, 3rd and 6th months after the operation in terms of recurrence.

Results

A total of 16 cases, including 12 female (75%) and four (25%) male patients, were included in this study. Clinical and postoperative data of the patients are summarized in Table 1. The ages of the patients ranged between 14–42 years (median age: 26.25 years). One patient had a pregnancy at the 28th gestational week. In nine (56%) cases, bleeding was identified as the most obvious complaint. Seven cases (43%) applied to our clinic for cosmetic reasons. There were three cases under the age of 16. Only four (25%) cases (18%) had a history of trauma to the lip region. Twelve patients stated that the mass appeared suddenly. The duration of patients' complaints ranged between two weeks and six months (average: five weeks). The lesions were located on the upper (n=2: 12.5%) and lower lip (n=14: 87.5%) vermillions (Figs. 1–4).

The lesions in all patients with trauma history were located on the lower lip vermilions. One case was clinically diagnosed with *cornu cutaneum* and the underlying lesion was found to be PG after the histopathological examination (Fig. 3). Fourteen cases underwent primary repair of the lesion bed using 5/0 rapid absorbable sutures (Vicryl Rapide; Ethicon Inc.) after excision in two cases, PGs of lower lips

Table 1. Pre- and post-operative characteristics of the cases

Cases	Age (yrs)	Gender	Location of the lesion	Size (mm)	Treatment	Recurrence
1	28	F	Lower lip	8x8	Excision + Primary repair	No
2	33	F	Lower lip	8x9	Excision + Primary repair	No
3	19	E	Lower lip	9x10	Excision + Primary repair	No
4	23	F	Lower lip	9x9	Excision + Primary repair	No
5	15	F	Lower lip	9x14	Excision + Primary repair	No
6	15	F	Upper lip	10x10	Excision + Primary repair	No
7	14	M	Lower lip	5x9	Excision + Primary repair	No
8	42	F	Lower lip	8x10	Excision + Primary repair	No
9	37	F	Lower lip	7x7	Excision + Primary repair	No
10	29	F	Lower lip	9x13	Excision + Primary repair	No
11	21	F	Lower lip	8x12	Excision + Primary repair	No
12	32	M	Lower lip	8x9	Excision + Primary repair	No
13	M	M	Lower lip	7x10	Excision + Primary repair	No
14	28	F	Lower lip	9x11	Excision + Primary repair	No
15	19	F	Right oral commissure	8x12	Excision + VAF	No
16	36	F	Right oral commissure	9x11	Excision + VAF	No

VAF: vermilion advancement flap.

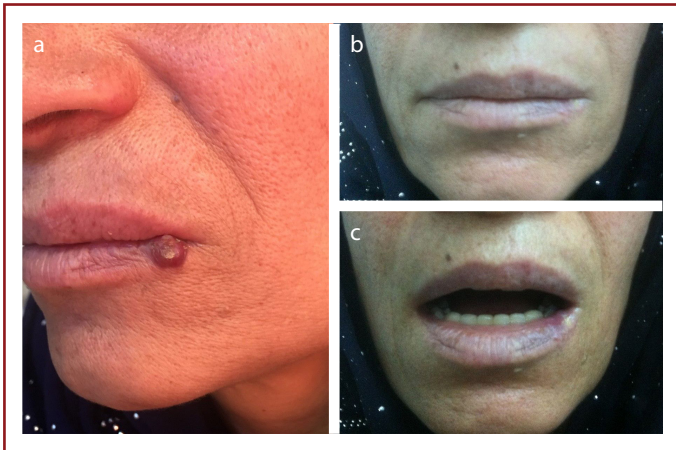


Figure 1. (a) Pyogenic granuloma located on the lower lip of the left oral commissure, (b, c) Its appearance one month after excision and placement of vermilion advancement flap.

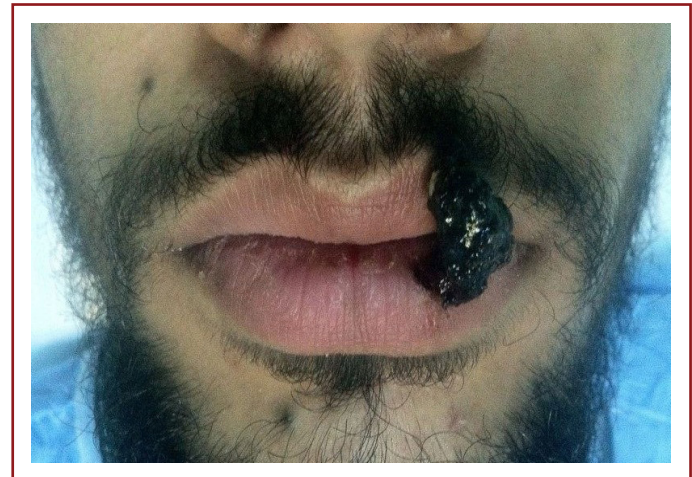


Figure 3. Pyogenic granuloma located on the upper lip in a 32-year-old patient.

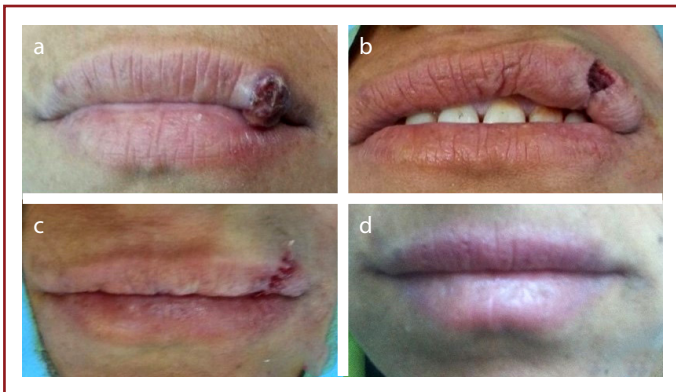


Figure 2. (a) Pyogenic granuloma located on the upper lip. (b) Its appearance following elliptic excision. (c) Perioperative appearance after the primary repair. (d) Postoperative appearance of the case at postoperative 6th month.

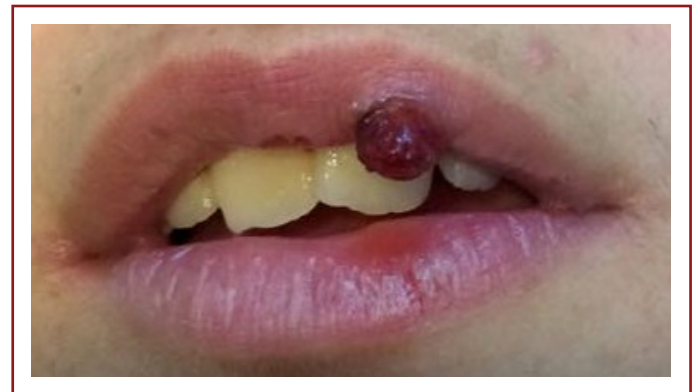

Figure 4. A lesion of *cornu cutaneum* located on the background of pyogenic granuloma of the upper lip.

were located on the oral commissure. Therefore, to obtain an esthetically good results, these two cases were repaired with vermilion advancement flap using 5/0 rapid absorbable sutures (Vicryl Rapide; Ethicon Inc.) after cauterization of the lesion bed following excision. In the postoperative period, treatment with oral cefuroxime (750 mg bid) was started, and dressing of the wound changed every day. The average follow-up period of the cases was 13 months (6-17 months). No complications and recurrence occurred in any case during the postoperative period.

Discussion

Vermillion is one of the most prominent parts of the face due to its features distinctly different from those of the face. Anatomically, the border of the lips ends distally on the vermilion-cutaneous junction, and from this point on, the lip vermilion starts without hair follicles and sweat

glands^[13]. The epithelium of vermilion is thin and nonkeratinized. Proximally, vermilion continues towards the oral cavity with a true mucous membrane^[14]. PGs occur especially and rarely on lower and upper lip vermilion and vermilion-cutaneous junction ("wet line")^[15, 16]. In the differential diagnosis of PGs located on the upper and lower lip vermillions. We should consider infantile hemangioma, squamous cell carcinoma, basal cell carcinoma, sarcoidosis, syphilis, aphthous ulcers, mycotic infections, traumatic wounds and labial tubercular ulcers^[17, 18].

Many surgical and non-surgical treatment options defined in the treatment of PG have been reported. In the recently published study of Lee et al.,^[19] it has been emphasized that there are 19 different treatment options in the literature for cutaneous PGs. Surgical treatment methods include excision, shave excision, and curettage and/or electrocautery, and non-surgical treatment methods include pulsed dye laser, CO₂ laser, suture ligation, cryotherapy, sclerotherapy, electrocauterization, imiquimod cream, phenol or bleomycin^[19].

Similar to cutaneous PGs, a wide variety of treatment options have been reported for lip vermillion. However, each treatment option has its own advantages and disadvantages. The generally accepted view is that surgical excision is applied to small lesions that heal by leaving scar tissue. However, as an important advantage, it allows histopathological examination. In addition, cryotherapy, laser applications, electrocautery, chemical cautery applications leave behind scar tissue and hyperpigmentation^[20]. Their disadvantages include the development of excessive bleeding after laser applications, lack of complete treatment response and the need for more than one treatment session^[10–12]. The most commonly used method in the treatment of pyogenic granulomas located on vermilions is surgical excision, as in cutaneous pyogenic granulomas.

Arslan et al. investigated 160 benign lip lesions, and nine (5.63%) cases were reported to be PG, and recurrence occurred after one month in a case of pyogenic granuloma located on one lip after surgical excision. In other studies, including 21 cases with PGs on lip vermilions, it has been reported that the development of recurrence was not observed after surgical excision and primary repair. However, in each of these studies, only one case with lip vermillion was treated surgically, which prevented arrival at a certain conclusion^[22–26]. In our study, 16 cases with lip vermillion were treated with surgical excision and primary repair or vermillion advancement flap, and in none of the cases, relapse developed during the mean follow-up of 13 months. Ichimiya et al.^[27] reported that they received successful results by applying ethanol injection into five PG cases in different parts of the body that recurred after cryotherapy. In this study, it was reported that PG was treated after an injection of pure ethanol into a PG on the upper lip. In their study, which included 20 PG cases that appeared in different parts of the body, Hammes et al.^[10] used Nd: YAG laser for these patients. In the study, a PG located upper lip vermillion was reported, and it was stated that excessive bleeding developed after the treatment. This case was treated by providing bleeding control after the CO₂ laser application.

In the study, it was advocated that Nd: YAG laser applications are safer to use in wide-based and high-volume PGs. Hong et al.^[11] evaluated the effectiveness of sclerotherapy application with ethanolamine oleate in 21 PG and venous lacquer cracks, and found one PG case on the upper lip. Four sessions of sclerotherapy were applied to this case with ethanolamine oleate. It was stated that a moderate shrinkage was achieved in the case, and surgical excision was performed due to the lack of complete response.

Asnaashari et al. excised a PG that developed on the upper lip after orthodontic treatment in a 15-year-old male patient. However, when the lesion recurred after five days, surgical excision was applied, and any recurrence did not occur during the 6-month follow-up period^[12]. Galeckas et al.^[28] reported that a 15-year-old male patient performed glycerine sclerotherapy following three sessions of 1.064-nm laser treatment on a PG of an upper lip and successfully treated PG on a cupid's bow.

In some studies in which different treatment options were evaluated or compared, recurrence rates and variability in treatment responses have been observed. Studies of Ghodsi and Mirshams include cases of PG located on lip vermillion. In these studies, the effectiveness of cryotherapy or application of curettage was evaluated, and very successful results were obtained^[2, 29]. However, in Ghodsi's study, the cosmetic results of the curettage method were excellent in 69%, and acceptable in the remaining cases. They stated that cryotherapy was not as successful as cosmetic curettage application, and unacceptably ugly scars formed in some patients.

In our study, very successful results were obtained, especially concerning scarring after the third month in patients who underwent primary repair or vermillion advancement flap following surgical excision. As a result of both treatments, none of the patients developed recurrence. It has been reported that thanks to more successful results concerning cosmetics, the requirement of fewer application sessions, and the possibility of histopathological examination, curettage of pyogenic granulomas was superior to cryotherapy^[2].

In their study, Lee et al. reported that the total recurrence rate of cutaneous PGs after surgery was 5.05%, and emphasized that among surgical treatment methods, the technique of surgical excision resulted in the lowest recurrence rate (2.94%). They reported that non-surgical techniques had an average recurrence rate of 3.62%, and indicated that the technique of cryotherapy had the lowest recurrence rate among these treatment options^[19]. In the same study, Lee et al. reported that there was no statistical difference between surgical excision and cryotherapy as for postprocedural recurrence rates. In our opinion, the superiority of surgical excision over other forms of treatment in the treatment of PGs located on both cutaneous and mucous membranes is that surgical excision allows histopathological examination, leaves behind cosmetically acceptable scars, and eliminates the lesion in a single session in patients with bleeding complaints if performed by experienced surgeons.

Among the cases included in this study, a pedicled, black-colored cylindrical hemorrhagic, crusted mass located on the lower lip initially diagnosed as *cornu cutaneum* (cutaneous horn) may develop on the underlying PG as revealed based on histopathological examination. *Cornu cutaneum* may develop on many underlying lesions. Cutaneous horn is a clinical term and describes the protrusions formed by the accumulation of keratin layers. In these cases, the underlying pathology is determined after histopathological examination^[30, 31]. In the literature, three cases of cutaneous horn developed on underlying PG have been reported. Finlay and Lapins reported that the underlying lesion was PG after histopathological examination in a case clinically diagnosed as a cutaneous horn. In another case report, Souza et al.^[33] found that the underlying lesion was PG in a case of cutaneous horn located on the lower lip vermilion.

Finally, in 2016, Nair et al.^[34] reported a case of *cornu cutaneum* developed on a background of the PG in an 11-year-old male patient. Our case also received the clinical diagnosis of cornu cutaneum, and the underlying lesion was pyogenic granuloma detected after histopathological examination. We believe that surgical excision should be the standard treatment option for the detection of the underlying pathological lesion, especially in cases similar to this case.

Conclusion

As a result of this study and in the light of the studies reported in previous studies, we recommend surgical excision for lip vermilions given that conventional surgical excision can remove the lesion at one attempt with very low recurrence rates. Given that ulcerated and bleeding pyogenic granulomas on lip vermilions can be associated with malignancy, and various diseases, surgical excision allows a complete histopathological examination.

Ethics Committee Approval: Retrospective study.

Peer-review: Externally peer-reviewed.

Conflict of Interest: None declared.

Financial Disclosure: The authors declared that this study received no financial support.

Authorship Contributions: Concept: A.D.; Design: A.D., A.S.D., T.D.; Data Collection or Processing: A.D., T.D., A.S.D., H.D.; Analysis or Interpretation: A.D., A.S.D., H.D.; Literature Search: A.D., A.S.D., T.D., H.D.; Writing: A.D., A.S.D.

References

1. Lin RL, Janniger CK. Pyogenic granuloma. *Cutis* 2004;74:229–33.
2. Ghodsi SZ, Raziie M, Taheri A, Karami M, Mansoori P, Farnaghi F. Comparison of cryotherapy and curettage for the treatment of pyogenic granuloma: a randomized trial. *Br J Dermatol* 2006;154:671–5.
3. Edalat Khah H, Mohebbi Pour AR, Egtedari F. Comparison of cryosurgery and electrocautery in pyogenic granuloma. *Iranian J Dermatol* 2006;9:127–31.
4. Patrice SJ, Wiss K, Mulliken JB. Pyogenic granuloma (lobular capillary hemangioma): a clinicopathologic study of 178 cases. *Pediatr Dermatol* 1991;8:267–76.
5. Kuflik EG. Cryosurgery updated. *J Am Acad Dermatol* 1994 Dec;31:925–44.
6. Fowler EB, Cuenin MF, Thompson SH, Kudryk VL, Billman MA. Pyogenic granuloma associated with guided tissue regeneration: a case report. *J Periodontol* 1996;67:1011–5.
7. Wandera A, Walker PO. Bilateral pyogenic granuloma of the tongue in graft-versus-host disease: report of case. *ASDC J Dent Child* 1994;61:401–3.
8. Lawoyin JO, Arotiba JT, Dosumu OO. Oral pyogenic granuloma: a review of 38 cases from Ibadan, Nigeria. *Br J Oral Maxillofac Surg* 1997;35:185–9.
9. Anderson WAD, Scatti MT. Skin. In *Synopsis of Pathology*. C.V. Mosby Co. 1980: 681
10. Hammes S, Kaiser K, Pohl L, Metelmann HR, Enk A, Raulin C. Pyogenic granuloma: treatment with the 1,064-nm long-pulsed neodymium-doped yttrium aluminum garnet laser in 20 patients. *Dermatol Surg* 2012;38:918–23.
11. Hong SK, Lee HJ, Seo JK, Lee D, Hwang SW, Sung HS. Reactive vascular lesions treated using ethanolamine oleate sclerotherapy. *Dermatol Surg* 2010;36:1148–52.
12. Asnaashari M, Bigom-Taheri J, Mehdipoor M, Bakhshi M, Azari-Marhabi S. Posthaste outgrowth of lip pyogenic granuloma after diode laser removal. *J Lasers Med Sci* 2014;5:92–5.
13. Ya-Xian Z, Suetake T, Tagami H. Number of cell layers of the stratum corneum in normal skin - relationship to the anatomical location on the body, age, sex and physical parameters. *Arch Dermatol Res* 1999;291:555–9.
14. Zuger C. The lips: anatomy and differential diagnosis. *Cutis* 1986;38:116–20.
15. Vilmann A, Vilmann P, Vilmann H. Pyogenic granuloma: evaluation of oral conditions. *Br J Oral Maxillofac Surg* 1986;24:376–82.
16. Graham RM. Pyogenic granuloma: an unusual presentation. *Dent Update* 1996;23:240–1.
17. Jafarzadeh H, Sanatkhan M, Mohtasham N. Oral pyogenic granuloma: a review. *J Oral Sci* 2006;48:167–75.
18. Neville BW, Damm DD, Allen CM. *Patologia oral e maxillofacial*. Rio de Janeiro: Guanabara Koogan, 1998.
19. Lee J, Sinno H, Tahiri Y, Gilardino MS. Treatment options for cutaneous pyogenic granulomas: a review. *J Plast Reconstr Aesthet Surg* 2011;64:1216–20.
20. Fishman SJ, Mulliken JB. Hemangiomas and vascular malformations of infancy and childhood. *Pediatr Clin North Am* 1993;40:1177–200.
21. Arslan S, Çobanoğlu B, Ural A, Saygın I, Işık AÜ. A 15-year retrospective study of 160 cases of benign lip lesions. *J Laryngol*

- Otol 2015;129:1224–7.
22. Mulinari-Santos G, Garcia BT, Taveira LA. Pyogenic Granuloma on the Upper Lip: A Rare Location. *J Craniofac Surg* 2017;28:577–8.
 23. de Carvalho FK, Pinheiro TN, Arid J, de Queiroz AM, de Rossi A, Nelson-Filho P. Trauma-Induced Giant Pyogenic Granuloma in the Upper Lip. *J Dent Child (Chic)* 2015;82:168–70.
 24. Ibrahim A, Asuku ME. Nodular swelling on the lower lip; pyogenic granuloma. *Eplasty* 2014;14:ic45.
 25. Gonçalves ES, Damante JH, Fischer Rubira CM, Taveira LA. Pyogenic granuloma on the upper lip: an unusual location. *J Appl Oral Sci* 2010;18:538–41.
 26. Nalin AS, George S, Kunjumon RM, Raj PR, George GB. Extra Gingival Pyogenic Granuloma: Unusual Location for the Usual Lesion. *IJSS Case Reports & Reviews* 2015;2:19–21.
 27. Ichimiya M, Yoshikawa Y, Hamamoto Y, Muto M. Successful treatment of pyogenic granuloma with injection of absolute ethanol. *J Dermatol* 2004;31:342–4.
 28. Galeckas KJ, Uebelhoefer NS. Successful treatment of pyogenic granuloma using a 1,064-nm laser followed by glycerin sclerotherapy. *Dermatol Surg* 2009;35:530–4.
 29. Mirshams M, Daneshpazhooh M, Mirshekari A, Taheri A, Mansoori P, Hekmat S. Cryotherapy in the treatment of pyogenic granuloma. *J Eur Acad Dermatol Venereol.* 2006;20:788–90.
 30. Bart RS, Andrade R, Kopf AW. Cutaneous horns. A clinical and histopathologic study. *Acta Derm Venereol* 1968;48:507–15.
 31. Yu RC, Pryce DW, Macfarlane AW, Stewart TW. A histopathological study of 643 cutaneous horns. *Br J Dermatol* 1991;124:449–52.
 32. Findlay RF, Lapins NA. Pyogenic granuloma simulating a cutaneous horn. *Cutis* 1983;31:610–2.
 33. Souza LN, Martins CR, de Paula AM. Cutaneous horn occurring on the lip of a child. *Int J Paediatr Dent* 2003;13:365–7.
 34. Nair PA, Kota RK, Pilani AP. Pyogenic granuloma underlying cutaneous horn in a young boy. *Indian Dermatol Online J* 2016;7:114–6.