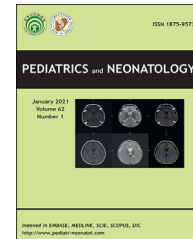


Available online at [www.sciencedirect.com](http://www.sciencedirect.com)

ScienceDirect

journal homepage: <http://www.pediatr-neonatal.com>

Letter to the Editor

# Co-occurrence of interrupted aortic arch and Apert syndrome: A case report



To the Editor,

Apert syndrome is a genetic disorder characterized by several clinical manifestations including craniosynostosis, midface hypoplasia, and symmetric syndactyly of both hands and feet. This disorder has an incidence of approximately 2 cases per 80,000 live births.<sup>1</sup> An interrupted aortic arch (IAA), which is an unusual form of congenital heart disease, has an incidence of 2 cases per 100,000 live births. The anatomical aberration of IAA comprises both luminal and anatomical disruptions between the descending and ascending aorta.<sup>2–4</sup>

## 1. Case report

A 40-year-old primigravida was referred to our clinic due to craniosynostosis and hand defects. A fetal transabdominal ultrasound at 32 gestational weeks revealed acrocephaly, frontal bossing, depressed nasal bridge, cutaneous syndactyly of both hands and total syndactyly of the toes of both feet, and severe polyhydramnios with the normal four-chamber view of the heart ([Appendix](#)). The patient's fetal echocardiography revealed that the aorta was mildly hypoplastic in three-vessel and tracheal views compared to the pulmonary artery ([Appendix](#)). When the aortic arch view was obtained, there was no continuity between the ascending and descending aorta. Moreover, the ascending aorta was the innominate artery, and it had continuity with the left carotid artery ([Appendix](#)). The patient was diagnosed with IAA type B. Genomic DNA was extracted from the umbilical cord blood. The fibroblast growth factor receptor 2 gene was analyzed by sequence analysis and next-generation sequencing method, respectively. Heterozygosity for a C-to-G transition at position c.758 was identified, leading to Pro253Arg (P253R) mutation. This missense mutation has been previously reported as "pathogenic" in Apert syndrome,<sup>5</sup> and the patient's parents were healthy. Thus, any further genetic analysis was not performed on the patient's parents. Furthermore, the mother refused to terminate the pregnancy.

A female newborn, weighing 2860 g and measuring 48 cm, with an Apgar score of 6/9 was delivered via cesarean

section at 34 + 2 weeks since the newborn was lying in transverse lie position and premature contractions were observed. The postnatal transthoracic echocardiogram (TTE) examination confirmed the prenatal sonographic findings of IAA type B. We also confirmed the diagnosis of IAA type B by three-dimensional computed tomography (3D-CTA). 3D-CTA examination of the thoracic aorta revealed an interruption between the left carotid artery and the left subclavian arteries, the pulmonary artery continuing as a descending aorta via the large ductus and the left subclavian artery originating from the pulmonary artery ([Appendix](#)). The patient was immediately admitted to the neonatal intensive care unit (NICU) to keep the ductus arteriosus patent with PGE1 infusion. Based on detailed physical examination in the NICU, acrocephaly, prominent forehead, hypertelorism, proptosis, lateral gaze of the left eye, broad nasal root, short hairline, pectus excavatum, cutaneous syndactyly of both hands, enlarged thumbs, and total syndactyly of the toes of both feet were detected ([Appendix](#)). Hence, the neonate was diagnosed with Apert syndrome based on the clinical, radiological, and genetic evaluation.

The patient underwent an operation on the 7th day of NICU admission by a pediatric heart surgeon to repair the interrupted aortic arch. The pediatric heart surgeon also confirmed our diagnosis of IAA type B. The patient was discharged from the NICU on the 20th day of admission. Recoarctation and aneurysm were not detected in the aortic arch of the patient at 6 months of control. According to the literature, IAA is grouped in three different anatomical groups depending upon the site of interruption. Type A is known as the interrupted region, which is distal to the left subclavian artery. Type B is located between the left carotid artery and left subclavian arteries, while type C is located between the left carotid artery and innominate arteries.<sup>6</sup> In this current case report, the patient was diagnosed with IAA type B.

Cohen and his colleagues have conducted the most extensive clinical study about patients with Apert syndrome who also had congenital heart diseases. Cohen et al. investigated 136 patients with Apert arch syndrome and reported a 10% incidence rate of cardiac anomaly. Septal anomalies, conotruncal anomalies, and multiple congenital

<https://doi.org/10.1016/j.pedneo.2020.09.009>

1875-9572/Copyright © 2020, Taiwan Pediatric Association. Published by Elsevier Taiwan LLC. This is an open access article under the CC BY-NC-ND license (<http://creativecommons.org/licenses/by-nc-nd/4.0/>).

heart diseases have been reported sporadically in the literature.<sup>6</sup> To the best of our knowledge, this is the first report of the co-occurrence of interrupted aortic arch and Apert syndrome in fetal and neonatal life. IAA, a ductus-dependent heart disease, is possibly observed in fetuses with Apert syndrome. Therefore, the course of the aortic arch should be carefully examined during both fetal perinatology examination and TTE of a newborn.

### Declaration of patient consent

The authors certify that they have obtained all appropriate patient consent forms. In the form the patient(s) has/have given his/her/their consent for his/her/their images and other clinical information to be reported in the journal. The patients understand that their names and initials will not be published and due efforts will be made to conceal their identity, but anonymity cannot be guaranteed.

### Authors contributions

All authors participated in creating content for the manuscript, editing and provided final approval for submission. No undisclosed authors contributed to the manuscript.

### Financial support

This research received no specific grant from any funding agency or commercial or not-for-profit sectors.

### Declaration of competing interest

The author(s) declare no potential conflicts of interest with respect to the research, authorship, and/or publication of this article.

### Appendix A. Supplementary data

Supplementary data to this article can be found online at <https://doi.org/10.1016/j.pedneo.2020.09.009>

### References

1. Apert E. De l' acricephalosyndactylie. *Bull Soc Med Hop Paris* 1906;23:1310–30.

2. Varghese R, Saheed SB, Omoregbee B, Ninan B, Pavithran S, Kothandam S. Surgical repair of interrupted aortic arch and interrupted pulmonary artery. *Ann Thorac Surg* 2015;100:e139–40.
3. Patel DM, Maldjian PD, Lovoulos C. Interrupted aortic arch with post-interruption aneurysm and bicuspid aortic valve in an adult: a case report and literature review. *Radiol Case Rep* 2015;10:5–8.
4. Mahieu-Caputo D, Sonigo P, Amiel J, Simon I, Aubry MC, Lemerrer M, et al. Prenatal diagnosis of sporadic Apert syndrome: a sequential diagnostic approach combining three-dimensional computed tomography and molecular biology. *Fetal Diagn Ther* 2001;16:10–2.
5. Li Y, Ma D, Sun Y, Meng L, Wang Y, Jiang T. Apert syndrome with FGFR2 758 C > G mutation: a Chinese case report. *Front Genet* 2018;9:181.
6. Cohen Jr MM, Kreiborg S. Visceral anomalies in the Apert syndrome. *Am J Med Genet* 1993;45:758–60.

Serap Nur Ergor

Department of Neonatology, Bezmialem Vakif University, Istanbul, Turkey

Mehmet Serdar Kutuk

Department of Obstetrics and Gynecology, Bezmialem Vakif University, Istanbul, Turkey

Nilgun Duman

Department of Medical Genetics, Bezmialem Vakif University, Istanbul, Turkey

Can Yilmaz Yozgat\*

Faculty of Medicine, Bezmialem Vakif University, Istanbul, Turkey

Hafize Otcu Temur

Department of Radiology, Bezmialem Vakif University, Istanbul, Turkey

Murat Ugurlucan

Department of Cardiovascular Surgery, Istanbul Medipol University, Istanbul, Turkey

Yilmaz Yozgat

Department of Pediatric Cardiology, Bezmialem Vakif University, Istanbul, Turkey

\*Corresponding author. Faculty of Medicine, Adnan Menderes Bulvarı, Vatan Caddesi, Bezmialem Vakif University, 34093, Istanbul, Turkey.  
E-mail address: [yozyat@gmail.com](mailto:yozyat@gmail.com) (C.Y. Yozgat)