

# Clinical Features and Spectral-Domain Optical Coherence Tomography Findings of Complete Congenital Stationary Night Blindness Patients

## Komplet Tip Konjenital Durağan Gece Körlüğü Hastalarının Klinik Özellikleri ve Spektral Domain Optik Koherens Tomografi Bulguları

<sup>1b</sup> Rukiye AYDIN,<sup>a</sup>  
<sup>1b</sup> Merve ÖZBEK,<sup>b</sup>  
<sup>1b</sup> Fevzi ŞENTÜRK<sup>b</sup>

<sup>a</sup>Department of Ophthalmology,  
 Columbia University College of  
 Physicians and Surgeons Edward  
 Harkness Eye Institute,  
 New York

<sup>b</sup>Department of Ophthalmology,  
 İstanbul Medipol University  
 Faculty of Medicine,  
 İstanbul

Received: 20.12.2017  
 Received in revised form: 06.02.2018  
 Accepted: 19.02.2018  
 Available online: 25.10.2018

Correspondence:  
 Rukiye AYDIN  
 Columbia University  
 College of Physicians and Surgeons  
 Edward Harkness Eye Institute,  
 Department of Ophthalmology,  
 New York, USA  
 drukiyeaydin@gmail.com

**ABSTRACT Objective:** To describe clinical findings and spectral domain optical coherence tomography (SD-OCT) features of our complete congenital stationary night blindness (CSNB) patients. **Material and Methods:** This retrospective study included 12 eyes of six patients diagnosed with complete type CSNB. Patients were evaluated with SD-OCT, fundus autofluorescence (FAF) and electrophysiological tests. Segmentation of retinal layers was performed on SD-OCT images of all CSNB patients and compared with 6 age matched, normal myopic controls. **Results:** All patients' anterior segments findings were normal and none of our patients had nystagmus or strabismus. Pale optic disc was observed in two patients. On FAF imaging eyes with CSNB demonstrated unremarkable fundi including normal distribution of autofluorescence. Full-field electroretinography (ERG) demonstrated b-wave to a-wave amplitude ratio of less than one in the combined rod-cone response which describes electronegative ERG. SD-OCT segmentation revealed statistically significant thinning of the total retina, retinal nerve fiber layer (RNFL), inner plexiform layer (IPL) and inner retinal thicknesses in the CSNB group compared to control group (respectively  $p=0.015$ ,  $p=0.011$ ,  $p=0.017$  and  $p=0.021$ ). In the other layers of retina, we observed thinning in the CSNB group, but this difference was not statistically significant. **Conclusion:** In our study we observed selective thinning of RNFL and IPL in our patients. We thought that thinning of the IPL and RNFL and possibly optic disc paleness in complete CSNB patients suggests bipolar cell dysfunction or synaptogenesis defect between bipolar cells and ganglion cells and possibly reduced number of these cells.

**Keywords:** Congenital stationary night blindness; optical coherence tomography; full-field electroretinography

**ÖZET Amaç:** Konjenital durağan gece körlüğü (KDGK) hastalarımızın klinik bulguları ve spektral domain optik koherens tomografi (SD-OKT) bulgularını tanımlamak. **Gereç ve Yöntemler:** Bu retrospektif çalışmaya, komplet tip KDGK tanısı alan altı hastanın 12 gözü dahil edildi. Hastalar SD-OKT, fundus otofloresans (FOF) ve elektrofizyolojik testlerle değerlendirildi. Tüm KDGK hastalarının SD-OKT görüntülerinde retinal tabakaların segmentasyonu yapıldı ve altı sağlıklı miyop kontrol ile karşılaştırıldı. **Bulgular:** Tüm hastaların anterior segment bulguları normaldi ve hastaların hiçbirinde nistagmus veya şaşılık yoktu. İki hastada optik disk soluk olarak gözlemlendi. FOF görüntülemesinde KDGK'lı gözlerde otofloresansın normal dağılımı ile birlikte normal fundus bulguları saptandı. Tam alan elektroretinografi (ERG), kombine rod-kon cevaplarında b dalgasının amplitüdünün a dalgasına oranının birden küçük olduğu elektronegatif ERG bulguları gösterdi. KDGK hastaları normal grupla karşılaştırıldığında SD-OKT segmentasyonunda total retina, retina sinir lifi tabakası (RSLT), iç pleksiform tabaka (İPT) ve iç retinal tabakalarda istatistiksel olarak anlamlı inceleme olduğu görüldü (sırasıyla  $p=0.015$ ,  $p=0.011$ ,  $p=0.017$  ve  $p=0.021$  idi). Diğer retina tabakalarında KDGK grubunda inceleme tespit edildi ancak bu fark istatistiksel olarak anlamlı değildi. **Sonuç:** Çalışmamızda hastalarımızda RSLT ve İPT tabakalarında inceleme olduğu tespit edildi. Komplet tip KDGK hastalarında İPT ve RSLT'nin incelenmesi ve optik disk solukluğunun, bipolar ve gangliyon hücreleri arasındaki bipolar hücre fonksiyon bozukluğu, sinaptogenez defekti ve bu hücrelerin sayısındaki muhtemel azalmaya bağlı olduğu düşünüldü.

**Anahtar Kelimeler:** Konjenital durağan gece körlüğü; optik koherens tomografi; tam alan elektroretinografi

**C**ongenital stationary night blindness (CSNB) refers to a group of disorders characterized by night blindness and non-progressive retinal dysfunction caused by defective signal transmission between photoreceptors and bipolar cells.<sup>1,2</sup> Onset of disease occurs in infancy, and patients often have accompanying symptoms of nystagmus and strabismus.<sup>1</sup>

Congenital stationary night blindness has been classified into complete and incomplete types, based on electroretinogram (ERG) findings and clinical characteristics.<sup>3</sup>

In the complete form, full-field ERG testing reveals normal to mildly subnormal cone function and complete absence of rod function. In contrast, patients with the incomplete form have greater disturbances of cone function, but they maintain some rod function.<sup>4</sup>

Both complete CSNB and incomplete CSNB demonstrate the classic negative ERG pattern, or Schubert Bornschein type, in which the b-wave is smaller than the a-wave during maximal response.<sup>5,6</sup>

Previously, optical coherence tomography findings in incomplete CSNB has been defined by Chen et al<sup>1</sup> and recently Al Oreany et al<sup>7</sup> reported relative thinning in inner nuclear layer (INL) compared to other retinal layers in affected twin brothers of a family diagnosed with autosomal recessive complete CSNB.

In this study we aimed to describe our complete CSNB patients clinical findings and spectral domain optical coherence tomography (SD-OCT) features.

## MATERIAL AND METHODS

This retrospective study included 12 eyes of six patients diagnosed with complete type CSNB. Patients with any retinal diseases that could influence ERG responses such as retinal detachment, uveitis, macular diseases or history of consumption of oral treatment or topical eye drops that affect retinal function were also excluded. Informed consent was obtained. Institutional Review Board (IRB)/Ethics Committee approval was obtained. The research

adhered to the tenets of the Declaration of Helsinki.

The patients underwent complete ophthalmic examination, including corrected visual acuity measurement (with Snellen chart), slit lamp biomicroscopy and indirect ophthalmoscopy.

The clinical diagnosis of CSNB was established by retina specialists and confirmed by full-field scotopic and photopic ERGs performed according to the International Society for Clinical Electrophysiology of Vision (ISCEV) standards.<sup>8</sup>

Optical coherence tomography was performed with the Spectralis (Heidelberg Engineering, Heidelberg, Germany) which has software that allows the segmentation of individual layers of the retina including the total retina, RNFL, ganglion cell layer (GCL), INL, inner plexiform layer (IPL), outer plexiform layer (OPL), outer nuclear layer (ONL) and retina pigment epithelium (RPE). Results for these layers were compared between CSNB and control groups.

An angiography device (HRA-2, Heidelberg Retinal Angiography, Dossenheim, Germany) was used to obtain fundus autofluorescence (FAF) images. After instilling 1% tropicamide and achieving sufficient mydriasis, FAF images were obtained.

All ERG measurements were performed at the Medipol University Ophthalmology Department. Baseline standard ERG was provided by one experienced technician with RETiport32 device. Standardized full-field ERGs were elicited with Ganzfeld stimuli using the commercial ERG system (Retiport32; Roland Consult) according ISCEV guidelines.<sup>8</sup> ISCEV standard ERG responses include: (1) dark-adapted 0.01 ERG (formerly “rod response”); (2) dark-adapted 3.0 ERG (formerly “maximal or standard combined rod-cone response”); (3) dark-adapted 3.0 oscillatory potentials (formerly “oscillatory potentials”); (4) light-adapted 3.0 ERG (formerly “single-flash cone response”); (5) light-adapted 3.0 flicker ERG (formerly “30-Hz flicker”).

For the recordings, pupils of both eyes were maximally dilated with 0.5 % tropicamide and 0.5

% phenylephrine, and the other eye was occluded. Silver/ nylon fiber electrodes (DTL, Laird Technologies, Sauquoit Inc., Scranton, USA) were used. The active electrode was inserted into inferior fornix of each eye. ERG recordings were obtained on both eyes. The ISCEV-ERG GF program, which is an integrated part of the system (Roland Consult, Electrophysiologic Diagnostic Systems, Wiesbaden, Germany), was used to record standard ERGs. Stimulation was performed using a full-field flash Ganzfeld stimulator (Roland Consult). All responses were differentially amplified, displayed on an oscilloscope, digitized and stored on a compact disc. An adjustable voltage window was used to reject records contaminated by artifacts. The reference and ground electrodes were placed near the temporal orbital rim and on the forehead, respectively. Dark-adapted ERGs were performed after 20 min of dark adaptation, and after 10 min of light adaptation before recording light-adapted ERGs. For the light-adapted ERGs, the background luminance was set at 30 cd/m<sup>2</sup>. Stimulus strength of 0.01 cd s/m<sup>2</sup> was used for rod stimulation and strength of 3.0 cd s/m<sup>2</sup> for all other standard responses. The band pass of the amplifiers was 1–300 Hz. The outcome measures were the difference between the mean rod response, standard combined response, single-flash cone response and 30 Hz flicker wave amplitude of the patients and normal population.

Statistical analysis was performed using SPSS software (Statistical Package for Social Sciences, version 20, SPSS Inc., Chicago, IL, USA). Qualitative variables were expressed as percentages, and quantitative data were expressed as mean values with standard deviations (SD) and/or confidence intervals (CI). Normal distributions of quantitative data were assessed using the Kolmogorov–Smirnov test. P values less than 0.05 were regarded as statistically significant. The p values were adjusted by Bonferroni correction in order to avoid the possible inflation of p values owing to multiple comparisons.

## RESULTS

The clinical characteristics of the six CSNB patients and control group are summarized in the (Table 1).

There were no significant differences in the patient ages and spherical equivalents values. Snellen best-corrected visual acuity for patients with CSNB ranged from 20/40 to 20/20 and patients ranged in age from 15 to 36 years and 15 to 45 years in control groups. All study patients had unremarkable fundus biomicroscopic examination results. All patients' anterior segments findings were normal, none of patients had nystagmus or strabismus. Pale optic disc was observed in two patients. On FAF imaging eyes with CSNB demonstrated

**TABLE 1:** Clinical characteristics of CSNB patients and control group.

Patient no	Group	Age (y)	Sex	BCVA		SE	
				Right eye	Left eye	Right eye	Left eye
1	CSNB	27	F	20/4	20/25	-1.38	-1.13
2	CSNB	16	F	20/20	20/20	+0.25	+0.25
3	CSNB	35	F	20/20	20/25	+0.50	+0.50
4	CSNB	36	M	20/25	20/40	-0.25	-0.13
5	CSNB	28	F	20/40	20/40	-1.63	-1.13
6	CSNB	15	F	20/20	20/20	-1.50	-1.8
7	Control	25	M	20/20	20/20	+0.25	-0.25
8	Control	28	F	20/20	20/20	1.50	-2.00
9	Control	45	M	20/20	20/20	-0.50	-0.25
10	Control	34	F	20/20	20/20	0	+0.50
11	Control	18	F	20/20	20/20	-1.88	-1.38
12	Control	15	F	20/20	20/20	-0.63	-0.75

BCVA: Best corrected visual acuity; SE: Spherical equivalent.

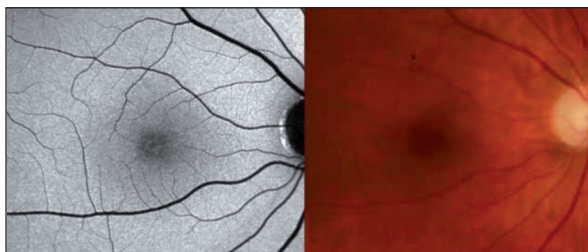
unremarkable fundi including normal distribution of autofluorescence in the (Figure 1).

Central 30° visual fields showed sensitivities within normal range values throughout the visual field for all patients.

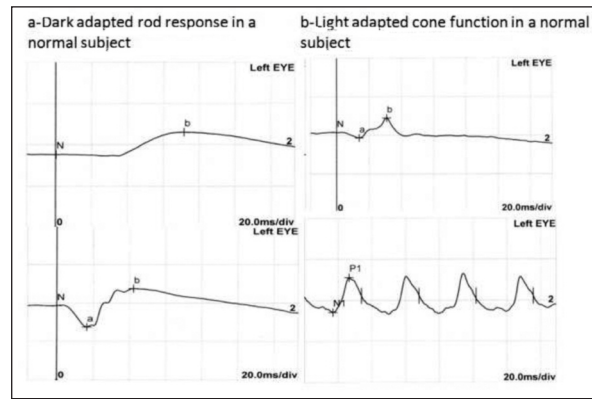
Full-field ERG demonstrated scotopic ERG a-wave was normal but the b-wave severely reduced and b-wave to a-wave amplitude ratio of less than one in the combined rod-cone response which describes electronegative ERG. Light adapted cone responses and 30 Hz flicker responses were normal. Representative ERG waveforms of Patient 4 and a normal subject are shown in the (Figure 2 and Figure 3).

All CSNB patients demonstrated a selective reduction of the b-wave that produces a b-wave to a-wave amplitude ratio of less than one in the scotopic bright-flash combined rod-cone full-field ERG response. This ERG finding describes electronegative response on maximal full-field scotopic ERG.

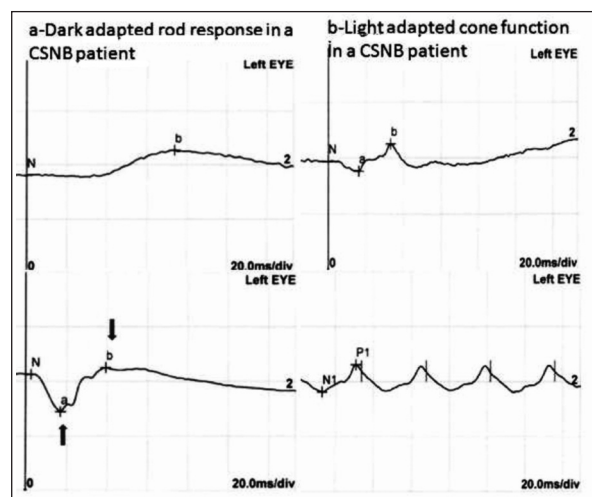
SD-OCT segmentation reveals a decrease in the total retina, RNFL, IPL and inner retinal thicknesses in the CSNB group (Figure 4). In the other layers of retina, we observe a thinning in the CSNB group, but this difference was not statistically significant. In the control and patient groups respectively the total retinal thickness was  $266.2 \pm 9.3\mu\text{m}$  and  $249.9 \pm 18.5 \mu\text{m}$ , the RNFL thickness was  $12.4 \pm 1.5\mu\text{m}$  and  $9.5 \pm 3.0\mu\text{m}$ , the GCL thickness was  $14.6 \pm 2.7\mu\text{m}$  and  $12.5 \pm 6.7\mu\text{m}$ , the IPL thickness was  $20.6 \pm 2.5\mu\text{m}$  and  $16.8 \pm 4.3\mu\text{m}$ , the INL thickness was  $18.4 \pm 3.1\mu\text{m}$  and  $17.5 \pm 5.8\mu\text{m}$ , the OPL thickness was  $23.4 \pm 3.7\mu\text{m}$  and  $22.0 \pm 4.8\mu\text{m}$ , the ONL



**FIGURE 1:** Color fundus photograph (left) and fundus autofluorescence image (right) from right eye of Patient 4. There are normal distribution of autofluorescence and normal optic disc and fundus appearance.



**FIGURE 2:** Normal electroretinography of control patient 10. The amplitude of b-wave is larger than a-wave.

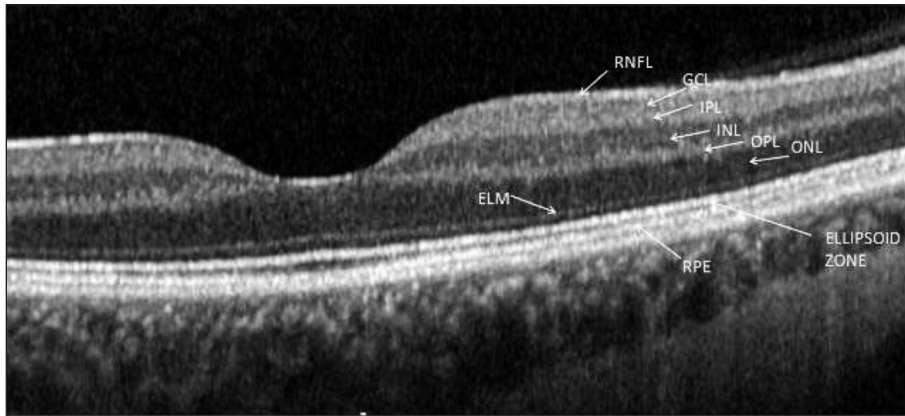


**FIGURE 3:** Full field electroretinography of patient 4. There are an electronegative configuration in the combined rod-cone response. A-wave is larger than the b wave. This is consistent with the electronegative ERG.

thickness was  $90.0 \pm 4.8 \mu\text{m}$  and  $86.4 \pm 8.8 \mu\text{m}$ , RPE thickness was  $16.8 \pm 1.5 \mu\text{m}$  and  $16.4 \pm 2.3 \mu\text{m}$ , the inner retinal thickness was  $178.3 \pm 11.4 \mu\text{m}$  and  $163.2 \pm 17.5 \mu\text{m}$ , the outer retinal thickness was  $88.0 \pm 2.7\mu\text{m}$  and  $86.9 \pm 2.8\mu\text{m}$ . Retinal thicknesses of all patients were summarized in the (Table 2).

## DISCUSSION

In this study, we aim to describe six complete type CSNB patients' clinical findings, electrophysiological tests and OCT findings and compare with the healthy subjects. According to the full field ERG results, all of our patients diagnosed with complete type CSNB. There was no detectable b-wave in the



**FIGURE 4:** Spectral-domain optical coherence tomography segmentation image of right eye of Patient 4. **RNFL:** Retinal nerve fiber layer; **GCL:** Ganglion cell layer; **IPL:** Inner plexiform layer; **INL:** Inner nuclear layer; **OPL:** Outer plexiform layer; **ONL:** Outer nuclear layer; **ELM:** External limiting membrane; **RPE:** Retina pigment epithelium.

rod-specific ERG, whereas the cone and rod-cone a-waves were normal in all CSNB patients.

In this study we observed significant thinning in total retina, RNFL, IPL and inner retinal thicknesses in complete CSNB patients compared to controls. The control group used for this study consisted of healthy mild myopic subjects designed to match myopic patients in CSNB group.

Formerly, in incomplete CSNB patients, Schatz et al. and Chen et al. were described outer retinal thinning especially in the outer plexiform and photoreceptor layers.<sup>1,9</sup>

Al Oreany et al. were analyzed SD-OCT findings of two affected twin brothers diagnosed with complete CSNB with TRPM1 mutations and compared them with five myopic control eyes.<sup>7</sup> They did not find significant thinning in total retinal thickness compared to control group; however, they observed relative thinning of INL compared to other retinal layers.

Godora et al. were analyzed Cirrus HD-OCT (Carl Zeiss Meditec, Inc, Dublin, California, USA) findings of three patients with complete CSNB caused by mutations in GRM6 and compared them with 93 healthy subjects.<sup>10</sup> They observed reduced total retinal thickness in complete congenital stationary night blindness patients. These three patients had normal outer retinal layer thicknesses however they had reduced GCL+IPL thicknesses compare to control eyes.

Based on our SD-OCT segmentation results we suppose that the thinning in RNFL and IPL cause to decreased total retinal and the inner retinal thicknesses. Of our patients had pale optic disc and almost all of our patients had thinner RNFL and IPL thicknesses than age and myopia matched controls. The reason of pale optic disc is not known in CSNB. Al Oreany et al. were related optic disc hypoplasia with possibly disturbed synaptogenesis problem between bipolar cells and ganglion cells.<sup>7</sup>

Our report had some limitations. We could not make molecular genetic screening to our patients because of financial inadequacy of families how-

	<b>Control Mean thickness (µm) ± SD</b>	<b>Patient Mean thickness (µm) ± SD</b>	<b>P value</b>
Total retina	266.2±9.3	249.9±18.5	<b>0.015*</b>
RNFL	12.4 ± 1.5	9.5 ± 3.0	<b>0.011*</b>
GCL	14.6±2.7	12.5±6.7	<b>0.338</b>
IPL	20.6±2.5	16.8±4.3	<b>0.017*</b>
INL	18.4±3.1	17.5±5.8	<b>0.639</b>
OPL	23.4±3.7	22.0±4.8	<b>0.429</b>
ONL	90.0±4.8	86.4±8.8	<b>0.235</b>
RPE	16.8±1.5	16.4±2.3	<b>0.609</b>
Inner retina	178.3±11.4	163.2±17.5	<b>0.021*</b>
Outer Retina	88.0±2.7	86.9±2.8	<b>0.312</b>

**RNFL:** Retinal nerve fiber layer **GCL:** Ganglion cell layer **IPL:** Inner plexiform layer **INL:** Inner nuclear layer **OPL:** Outer plexiform layer **ONL:** Outer nuclear layer **RPE:** Retina pigment epithelium.

ever we did not take any complain about night blindness in none of our patients family members. Today, TRPM1, GPR179, GRM6, LRIT3, and NYX genes have been identified as associated with complete type CSNB.<sup>11</sup>

All are caused by defects in visual signal transduction within rod photoreceptors or in defective photoreceptor to bipolar cell signaling.

In our study we observed selective thinning of RNFL and IPL in our patients. The IPL consists of synaptic connections between the axons of bipolar cells and dendrites of ganglion cells. As a result of our study, we thought that thinning of the IPL and RNFL and possibly optic disc paleness in complete CSNB patients suggests bipolar cell dysfunction or synaptogenesis defect between bipolar cells and ganglion cells and reduced number of these cells.

#### Source of Finance

During this study, no financial or spiritual support was received neither from any pharmaceutical company that has a direct

connection with the research subject, nor from a company that provides or produces medical instruments and materials which may negatively affect the evaluation process of this study.

#### Conflict of Interest

No conflicts of interest between the authors and / or family members of the scientific and medical committee members or members of the potential conflicts of interest, counseling, expertise, working conditions, share holding and similar situations in any firm.

#### Authorship Contributions

**Idea/Concept:** Fevzi Şentürk, Rukiye Aydın, Merve Özbek; **Design:** Rukiye Aydın, Fevzi Şentürk, Merve Özbek; **Control/Supervision:** Merve Özbek, Rukiye Aydın, Fevzi Şentürk; **Data Collection and/or Processing:** Merve Özbek, Rukiye Aydın, Fevzi Şentürk; **Analysis and/or Interpretation:** Fevzi Şentürk, Rukiye Aydın, Merve Özbek; **Literature Review:** Rukiye Aydın, Fevzi Şentürk, Merve Özbek; **Writing the Article:** Merve Özbek, Rukiye Aydın, Fevzi Şentürk; **Critical Review:** Rukiye Aydın, Fevzi Şentürk, Merve Özbek; **References and Fundings:** Rukiye Aydın, Fevzi Şentürk, Merve Özbek; **Materials:** Fevzi Şentürk, Rukiye Aydın, Merve Özbek.

## REFERENCES

- Chen RW, Greenberg JP, Lazow MA, Ramachandran R, Lima LH, Hwang JC, et al. Autofluorescence imaging and spectral domain optical coherence tomography in incomplete congenital stationary night blindness and comparison with retinitis pigmentosa. *Am J Ophthalmol* 2012;153(1):143-54.e2.
- Schubert G, Bornschein H. [Analysis of the human electroretinogram]. *Ophthalmologica* 1952;123(6):396-413.
- Tan X, Aoki A, Yanagi Y. Color vision abnormality as an initial presentation of the complete type of congenital stationary night blindness. *Clin Ophthalmol* 2013;7:1587-90.
- Miyake Y, Yagasaki K, Horiguchi M, Kawase Y, Kanda T. Congenital stationary night blindness with negative electroretinogram: a new classification. *Arch Ophthalmol* 1986;104(7):1013-20.
- Kabanarou SA, Holder GE, Fitzke FW, Bird AC, Webster AR. Congenital stationary night blindness and a "Schubert-Bornschein" type electrophysiology in a family with dominant inheritance. *Br J Ophthalmol* 2004;88(8):1018-22.
- Miyake Y, Yagasaki K, Horiguchi M, Kawase Y. On- and off-responses in photopic electroretinogram in complete and incomplete types of congenital stationary night blindness. *Jpn J Ophthalmol* 1987;31(1):81-7.
- Al Oreany AA, Al Hadlaq A, Schatz P. Congenital stationary night blindness with hypoplastic discs, negative electroretinogram and thinning of the inner nuclear layer. *Graefes Arch Clin Exp Ophthalmol* 2016;254(10):1951-6.
- Marmor MF, Fulton AB, Holder GE, Miyake Y, Brigell M, Bach M. ISCEV Standard for full-field clinical electroretinography (2008 update). *Doc Ophthalmol* 2009;118(1):69-77.
- Schatz P, Abdalla Elsayed MEA, Khan AO. Multimodal imaging in CABP4-related retinopathy. *Ophthalmic Genet* 2017;38(5):459-64.
- Godara P, Cooper RF, Diederichs MA, Sergouniotis P, Genead MA, Webster AR, et al. Assessing photoreceptor reflectance and structure in congenital stationary night blindness. *Invest Ophthalmol Vis Sci* 2012;53(14):5256.
- Malaichamy S, Sen P, Sachidanandam R, Arokiasamy T, Lancelot ME, Audo I, et al. Molecular profiling of complete congenital stationary night blindness: a pilot study on an Indian cohort. *Mol Vis* 2014;20:341-51.