

Endobronchial Management of an Endobronchial Hamartoma

Ekrem Cengiz SEYHAN^a,
 Mehmet Zeki GÜNLÜOĞLU^b,
 Mustafa DÜGER^c,
 Mehmet Akif ÖZGÜL^a,
 Elif ÇALIŞ^d,
 İrem ÖZÖVER^d

^aClinic of Chest Diseases,
 Yedikule Chest Diseases and
 Thoracic Surgery Training and
 Research Hospital,
 Departments of

^bThoracic Surgery,
^cChest Diseases,
^dPathology,
 İstanbul Medipol University
 Faculty of Medicine,
 İstanbul, TURKEY

Received: 23 Apr 2019
 Accepted: 08 Jul 2019
 Available online: 09 Jul 2019

Correspondence:
 Ekrem Cengiz SEYHAN
 Yedikule Chest Diseases and
 Thoracic Surgery Training and
 Research Hospital,
 Clinic of Chest Diseases,
 İstanbul, TURKEY
 drekremcs@yahoo.com

ABSTRACT Endobronchial hamartoma (EH) is a rare benign tumor of the bronchial tree. This tumor can obstruct the bronchus or cause bleeding. The treatment method is chosen according to location and extent of the tumor. Endobronchial hamartoma can be resected via bronchoscopic approach; surgical therapy, is alternative only for cases where the tumor cannot be resected completely through endoscopy, or if irreversible pulmonary changes secondary to obstruction of the bronchus occurred. We herein describe a 52-year-old female presented with progressive dyspnea and treated with diagnosis of asthma. In this patient, EH which is located in the left main lobe bronchus was found in radiologic assessment. Bronchoscopy revealed a broad-based mass obstructing the bronchus. The tumor was resected after coagulation of the tumor with argon plasma coagulation, by the rigid bronchoscope. Pathologic diagnosis was reported as EH. This report highlights the success of rigid bronchoscopic approach in the management of EH.

Keywords: Endobronchial hamartoma; endobronchial management; argon plasma coagulation

Benign lung tumors are rare tumors; consist of less than 1% of body tumors. Among these, hamartomas are the most common and found in the range of 0.02% to 0.3% incidence.¹ Hamartoma may locate into pulmonary parenchyma; these hamartomas are generally asymptomatic. Some hamartomas may be located in the trachea or bronchi, and present with result of tracheal or bronchial obstruction as cough, expectoration, and dyspnea.² Endobronchial hamartomas (EH) often grow and obstruct the bronchial lumen substantially without symptoms such as dyspnea, and wheezing. Without an apparent radiologic sign, the symptoms secondary to bronchial obstruction may lead to misdiagnosis of asthma.¹ Because of the benign nature of these tumors, bronchoscopic removal is generally recommended, but in patients with irreversible lung destruction surgical treatment should be performed.³ We herein report a case of a bulky EH placed in the left main bronchus, diagnosed by bronchoscopy and extracted by endobronchial treatment via rigid bronchoscope.

CASE REPORT

A 52-year-old female patient with a 5-year history of asthma was admitted to the hospital complaining of chest pain and progressive shortness of breath. The patient was a nonsmoker and had no other significant medical his-

tory. Physical examination revealed decreased breath sounds in the lower part of the left hemithorax, and no pathological finding in other systems. Chest x-ray, biochemical blood analysis and complete blood counts were normal.

A computed tomography (CT) of the thorax scan revealed the presence of a solid endobronchial lesion subtotally occluding the left main bronchus (Figure 1 a, b). The patient was performed bronchoscopy that confirmed the presence of a broad-based tumor arising from anterolateral wall of the left main bronchus covered with smooth mucosa, mobile during breathing and near totally occluding the bronchial lumen. The procedure was terminated by planning rigid bronchoscopy under general anesthesia to obtain large samples under safe conditions or with the hope of completely removing the tumor. Rigid bronchoscopy showed near complete obstruction of the proximal of the left main bronchus caused by a broad-based tumor (Figure 2 a, b). Using a biopsy forceps and argon plasma coa-

gulation (APC), the lesion was totally removed with no residual tissue (Figure 2 c). After removal of the tumor, cryotherapy was applied to the bronchial wall under the the tumor. Lumen of the bronchus was seen fully opened (Figure 2 d). Histopathological evaluation revealed mature cartilage and fat tissue in the deeper layer of the tumor, and the tumor was diagnosed as EH (Figure 3 a, b). Computerized tomography of the thorax taken immediately after the endobronchial therapy showed that the left lobe bronchus was entirely patent (Figure 1 c, d).

DISCUSSION

Hamartomas are rarely at endobronchial location.² Endobronchial hamartoma is accounts for 1.4-19.5% of hamartomas.² Symptoms vary according to the tumor location. The most of parenchymal hamartoma patients are asymptomatic. Unlike, most patients with EH had respiratory symptoms secondary to bronchial obstruction such as cough,

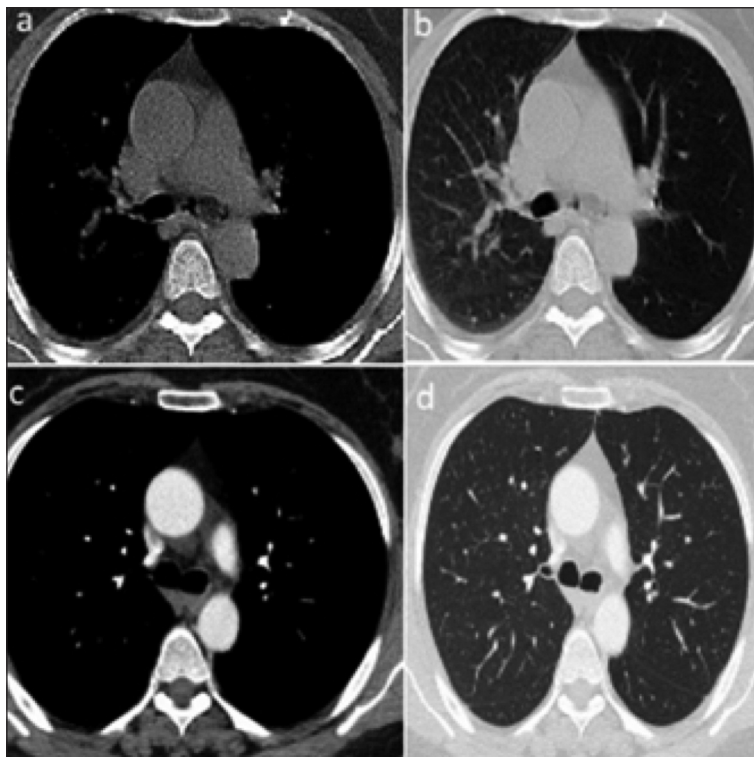


FIGURE 1: Thorax computed tomography scan showing a, b) the presence of a solid endobronchial lesion subtotally occluding the main left bronchus, c, d) totally opened left main bronchus after endobronchial treatment.

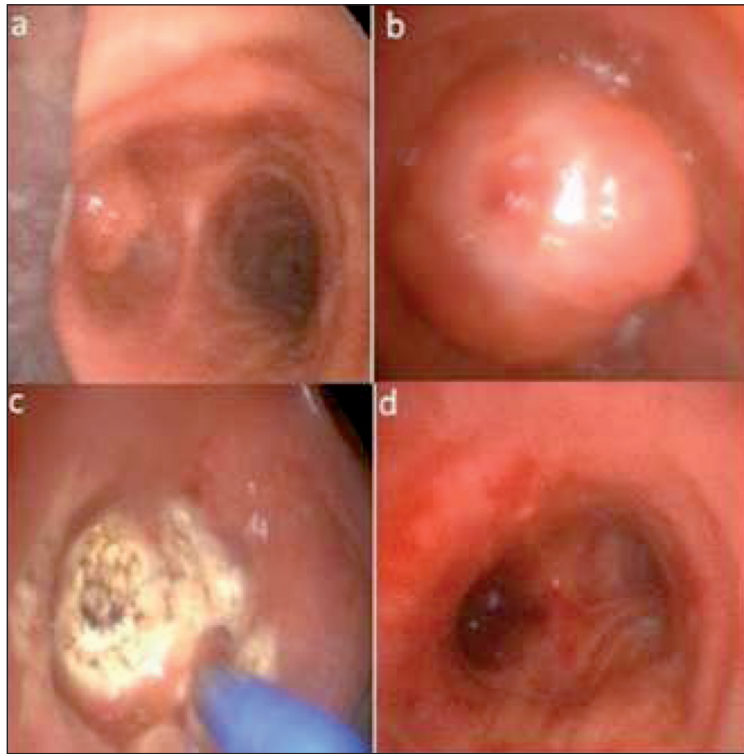


FIGURE 2: Rigid bronchoscopic view; **a)** the mass occluding left main lobe bronchus, **b)** the tumor covered with smooth mucosa, **c)** mass removal by using argon plasma coagulation, **d)** view of bronchial lumen after the removal of the mass.

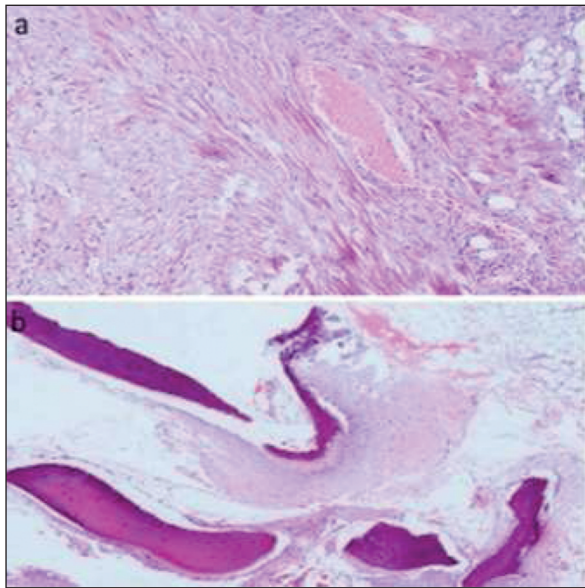


FIGURE 3: Histological examination shows endobronchial hamartoma: **a)** fibroblast cell mesenchymal proliferation and vascular structure (hematoxylin and eosin, x100). **b)** mature adipose tissue, cartilage and occasionally lamellar bone formation (hematoxylin and eosin, x20).

dyspnea, and obstructive pneumonia symptoms; fever and purulent sputum.³ Patients with EH are

often misdiagnosed as asthma due to bronchial obstruction symptoms and signs, and these patients can remain undiagnosed for months or years as in our patient.¹⁻⁴

Conventional radiography often shows changes related to bronchial obstructions, such as atelectasis, pneumonia, and bronchiectasis in EH patients. However, chest X-ray of most of the patients shows no pathological changes due to partial obstruction of the bronchus as in our case. Usual CT appearance of pulmonary hamartomas (PH) is a soft tissue including fat alternating with foci of calcification. Endobronchial hamartoma typically includes more fat tissue than parenchymal ones.⁵ On CT scan, the EH appears as an endobronchial mass with or without signs of obstructive pneumonia or atelectasia.⁶ At careful revision of the pertinent literature, specific radiological features of EH were seen not to be reported; generally, they appear as ovoid low-density endobronchial lesions, with a smooth edge, the lesion includes focal fat, or fat alternating with calcification.⁷ In our case, CT image

of the tumor was a low attenuation endobronchial mass in the left main bronchus.

Early endoscopic examination is important for detection of EHs before the lung distal to the obstruction is irreversibly destroyed. EH at bronchoscopic view appears as a polypoid or pedunculated, well-circumscribed neoplasm, with a smooth surface, no signs of submucosal infiltration are seen.⁸ The diagnosis may be suspected by endoscopic appearance, but EH cannot be reliably distinguished from the other benign bronchial tumors or typical carcinoid tumors, even with small biopsies. Considering these difficulties, we did not prefer to receive a small biopsy via flexible bronchoscope and the patients underwent rigid bronchoscopic procedure.

Pulmonary hamartoma is composed of bronchial primitive mesenchymal tissue; this tissue can turn into various mesenchymal components.⁴ So, on histopathology, PH has various components like fat, cartilage, fibrous tissue, and rarely bone marrow. Endobronchial hamartomas usually have more fat content than pulmonary intraparenchymal hamartomas.¹ For differential diagnosis from the other benign endobronchial tumors and from carcinoid tumor, biopsy is generally required. In our case, we did not obtain a biopsy but final histopathological evaluation showed mature cartilage and also adipose tissue in the deeper layer of the tumor, and diagnosis of EH was confirmed.

Endobronchial hamartoma can be successfully removed both endoscopically and surgically. Currently, bronchoscopic removal has been recommended for both diagnosis and also curative treatment, in the first line.⁸ Bronchoscopic resection techniques such as Nd-YAG or snare laser, electrocautery, cryotherapy, and APC can be used. Surgical resection is preserved for the cases which

an EH cannot be resected through bronchoscopy, or cases needed lung resection secondary to irreversible pulmonary parenchymal destruction from long-standing airway obstruction.³ In our case, there were no irreversible pulmonary parenchymal changes and the tumor was accessible via bronchoscope, so we preferred to resect the the tumor using endobronchial treatment modalities such as APC and cryotherapy.

In conclusion, atypical bronchial asthma symptoms may be related to endobronchial tumors like an EH. According to our experience, bronchoscopic resection of an EH with cryoablation and APC is a safe and effective option for selected patients.

Informed Consent

Written informed consent was obtained from the patient who participated in this case report.

Source of Finance

During this study, no financial or spiritual support was received neither from any pharmaceutical company that has a direct connection with the research subject, nor from a company that provides or produces medical instruments and materials which may negatively affect the evaluation process of this study.

Conflict of Interest

No conflicts of interest between the authors and / or family members of the scientific and medical committee members or members of the potential conflicts of interest, counseling, expertise, working conditions, share holding and similar situations in any firm.

Authorship Contributions

Idea/Concept: Ekrem Cengiz Seyhan; **Design:** Mustafa Düger; **Control/Supervision:** Mehmet Zeki Günlüoğlu; **Data Collection and/or Processing:** Mehmet Akif Özgül; **Analysis and/or Interpretation:** Ekrem Cengiz Seyhan; **Literature Review:** Elif Çalıř; **Writing the Article:** Ekrem Cengiz Seyhan; **Critical Review:** İrem Özöver; **References and Fundings:** Mustafa Düger; **Materials:** Mehmet Akif Özgül.

REFERENCES

1. Cosío BG, Villena V, Echave-Sustaeta J, de Miguel E, Alfaro J, Hernandez L, et al. Endobronchial hamartoma. *Chest*. 2002;122(1):202-5. [[Crossref](#)] [[PubMed](#)]
2. Gjevre JA, Myers JL, Prakash UB. Pulmonary hamartomas. *Mayo Clin Proc*. 1996;71(1):14-20. [[Crossref](#)] [[PubMed](#)]
3. Kaya S, Karalezli A, Balkan E, Cakiroğlu E, Hasanoğlu HC. Endobronchial hamartoma removed by flexible fiberoptic bronchoscopy via electrocautery. *Tuberk Toraks*. 2006;54(3):273-6. [[PubMed](#)]
4. Bernabéu Mora R, García Martín E, Polo García LA, Méndez Martínez P, Abellán Martínez MC, Sánchez Gascón F. [Endobronchial chondroid hamartoma presenting as asthmatic attack]. *An Med Interna*. 2003;20(5):271-2. [[Crossref](#)] [[PubMed](#)]
5. Ahn JM, Im JG, Seo JW, Han HS, Yoon HK, Kim WS, et al. Endobronchial hamartoma: CT findings in three patients. *AJR Am J Roentgenol*. 1994;163(1):49-50. [[Crossref](#)] [[PubMed](#)]
6. Karabulut N, Bir F, Yuncu G, Kiter G. Endobronchial lipomatous hamartoma: an unusual cause of bronchial obstruction (2007: 7b). *Eur Radiol*. 2007;17(10):2687-90. [[Crossref](#)] [[PubMed](#)]
7. Suut S, Al-Ani Z, Allen C, Rajiah P, Durr-E-Sabih, Al-Harbi A, et al. Pictorial essay of radiological features of benign intrathoracic masses. *Ann Thorac Med*. 2015;10(4):231-42. [[PubMed](#)]
8. Stey CA, Vogt P, Russi EW. Endobronchial lipomatous hamartoma: a rare cause of bronchial occlusion. *Chest*. 1998;113(1):254-5. [[Crossref](#)] [[PubMed](#)]