



# REVISTA BRASILEIRA DE ANESTESIOLOGIA

Publicação Oficial da Sociedade Brasileira de Anestesiologia  
www.sba.com.br



## SCIENTIFIC ARTICLE

# Evaluation of sciatic nerve damage following intraneural injection of bupivacaine, levobupivacaine and lidocaine in rats



Oznur Sen<sup>a,\*</sup>, Nevzat Cem Sayilgan<sup>b</sup>, Ayse Cigdem Tutuncu<sup>b</sup>, Mefkur Bakan<sup>c</sup>,  
Guniz Meyanci Koksali<sup>b</sup>, Huseyin Oz<sup>d</sup>

<sup>a</sup> Department of Anesthesiology and Reanimation, Ministry of Health, Haseki Training and Research Hospital, Istanbul, Turkey

<sup>b</sup> Department of Anesthesiology and Reanimation, Istanbul University, Cerrahpasa Medical Faculty, Istanbul, Turkey

<sup>c</sup> Department of Anesthesiology and Reanimation, Bezmialem Vakif University, Faculty of Medicine, Istanbul, Turkey

<sup>d</sup> Department of Anesthesiology and Reanimation, Medipol University, Faculty of Medicine, Istanbul, Turkey

Received 11 September 2014; accepted 29 September 2014

Available online 12 March 2015

### KEYWORDS

Local anesthetics;  
Lidocaine;  
Bupivacaine;  
Levobupivacaine;  
Neurotoxicity

### Abstract

**Objective:** The local anesthetics may cause neurotoxicity. We aimed to compare the neurotoxic potential of different local anesthetics, local anesthetic induced nerve damage and pathological changes of a peripheral nerve.

**Methods:** Sixty Wistar rats weighing 200–350 g were studied. Rats were assigned into 3 groups and 26-gauge needle was inserted under magnification into the left sciatic nerve and 0.2 mL of 0.5% bupivacaine, 5% levobupivacaine, and 2% lidocaine were injected intraneurally. An individual who was blind to the specifics of the injection monitored the neurologic function on postoperative 1st day, and daily thereafter. Neurologic examination included assessment for the presence and severity of nociception and grasping reflexes. At the 7th day sciatic nerve specimen was taken for evaluation of histopathologic changes.

**Results:** There was no statistical difference detected among groups regarding grasping reflex and histopathologic evaluation. Two cases in bupivacaine group, 1 case in levobupivacaine group and 2 cases in lidocaine group had slight grasping, while 1 case in lidocaine group had no grasping reflex on the seventh day. Severe axonal degeneration was observed in all groups, respectively in bupivacaine group 4 (20%), levobupivacaine group 3 (15%), and lidocaine group 6 (30%).

**Conclusion:** In all groups, histopathological damage frequency and severity were more than the motor deficiency.

© 2015 Sociedade Brasileira de Anestesiologia. Published by Elsevier Editora Ltda. All rights reserved.

\* Corresponding author.

E-mail: [senoznur@gmail.com](mailto:senoznur@gmail.com) (O. Sen).

**PALAVRAS-CHAVE**

Anestésicos locais;  
Lidocaína;  
Bupivacaína;  
Levobupivacaína;  
Neurotoxicidade

## Avaliação da lesão do nervo ciático após injeção intraneural de bupivacaína, levobupivacaína e lidocaína em ratos

**Resumo**

**Objetivo:** Os anestésicos locais podem causar neurotoxicidade. Nosso objetivo foi comparar o potencial neurotóxico de diferentes anestésicos locais, os danos induzidos aos nervos e as alterações patológicas de um nervo periférico.

**Métodos:** Sessenta ratos Whistler pesando 200-350 g foram estudados. Os ratos foram divididos em três grupos, uma agulha de calibre 26 foi inserida no nervo ciático esquerdo, com o uso de ampliação, e 0,2 mL de bupivacaína a 0,5%, levobupivacaína a 5% e lidocaína a 2% foram injetados por via intraneural. Um colaborador, cego para os conteúdos das injeções, monitorou a função neurológica no primeiro dia de pós-operatório e depois diariamente. O exame neurológico incluiu a avaliação da presença e da gravidade da nocicepção e dos reflexos de agarrar. No sétimo dia, uma amostra do nervo ciático foi colhida para avaliar as alterações histopatológicas.

**Resultados:** Não houve diferença estatística entre os grupos em relação ao reflexo de agarrar e à avaliação histopatológica. Dois casos no grupo bupivacaína, um caso no grupo levobupivacaína e dois casos no grupo lidocaína apresentaram um leve reflexo de agarrar; também no grupo lidocaína, um caso não apresentou reflexo de agarrar no sétimo dia. Degeneração axonal grave foi observada em todos os grupos: quatro casos no grupo bupivacaína (20%), três casos no grupo levobupivacaína 3 (15%) e seis casos no grupo lidocaína (30%).

**Conclusão:** Em todos os grupos, a frequência de dano histopatológico e de gravidade foi maior que a deficiência motora.

© 2015 Sociedade Brasileira de Anestesiologia. Publicado por Elsevier Editora Ltda. Todos os direitos reservados.

**Introduction**

Effects of intraneural injection of local anesthetics and peripheral nerve injury are rare complications of regional anesthesia. Most of these are temporary, subclinical mononeuropathies.<sup>1</sup> Reversible axonal damage and injury progressing to myelin degeneration can be determined histopathologically after intraneuronal injections. In animal studies, retention of motor functions despite the damage has been observed.<sup>2</sup>

This study has aimed at investigation in the rat of motor dysfunction and the histopathological changes after a single dose injection intraneurally of bupivacaine, levobupivacaine and lidocaine.

**Methods**

Hospital Animal Ethics Council approval was obtained for this study. Sixty Wistar rats of 200–350 g weight were kept in the laboratory under conditions of 20–24 °C temperature, 65–70% humidity, 12 h light and 12 h dark with unrestricted feed and liquid requirements. Experimentally, the rats were anesthetized, after food withdrawal for 4 h, by intraperitoneal injection of 100 mg/kg ketamine hydrochloride (Ketalar®, Eczacıbaşı Warner Lambert, İstanbul, Turkey). Subsequently, the gluteal muscle area was cleaned with bat-ticon antiseptic solution and the sciatic nerve was exposed through a limited transverse incision. Intraneural injections were made with the use of an automatic infusion pump through no 26 cannula entered at 45–60° angles.

The rats were subdivided into three groups as Group B (Bupivacaine) given 0.2 mL 0.5% bupivacaine; Group C (Chirocaine) given 0.2 mL 0.5% levobupivacaine, and Group L (Lidocaine) given 0.2 mL 2% lidocaine over 1 min infusions. The rats were woken up after closing the incisions.

Neurological functions of the rats were evaluated by three individuals, not informed of the applied local anesthetics, every day up to 7 days after the intraneural injections. For neurological assessment, nociception and the grasping reflex were evaluated. Nociception was triggered by pain on the first and the fifth phalanges and rated as 4/‘normal withdrawal reflex’, 3/‘slower withdrawal’; 2/‘slow withdrawal or sound; absence of movement’; 1/‘very slight withdrawal’; 0/‘no withdrawal’; and the grasping reflex was rated as 2/‘normal grasping reflex; 1/‘slow grasping’; 0/‘absence of grasping’.

The rats were given ketamine hydrochloride, sacrificed by decapitation and the sciatic nerve was excised. The samples were routinely placed in 10% buffered formaldehyde, embedded in paraffin, dyed with haematoxylin and eosin and examined under light microscopy for integrity of the neurological structure, mechanical damage, myelin damage and cellular infiltration.

Myelin damage was estimated using the Nerve Injury Scoring System (NISS), and the scoring was as 1 = ‘normal, mild degeneration or demyelination’, 2 = ‘moderate level of degeneration’ or (<50% damaged nerve tissue) and 3 = diffuse degeneration or demyelination (>50% damaged nerve tissue).

The statistical evaluation of the neurological results was carried out by the Kruskal–Wallis and Mann–Whitney *U* tests.

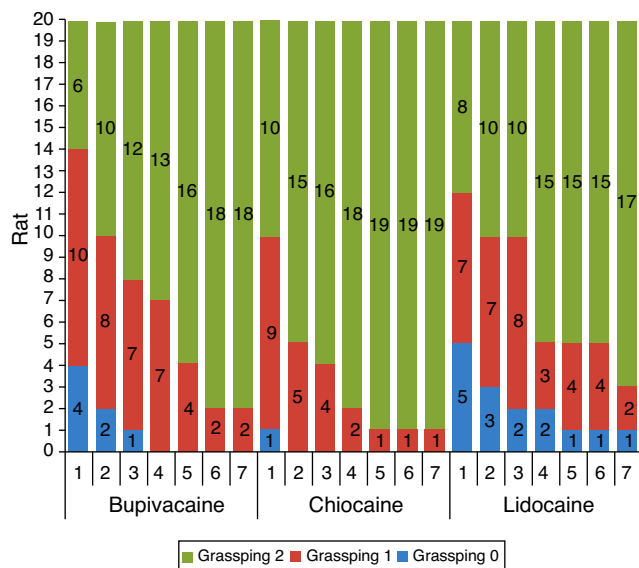


Figure 1 Grasping reflexes.

The damage scores were estimated for each of the anesthetics used with the one-way ANOVA test and the value  $p < 0.05$  was taken to represent statistical significance.

## Results

There was no statistically significant difference in the weights of the 3 groups of rats. Also, there were no statistically significant differences between the grasping reflex scores of the three groups.

In the intragroup comparisons, however, there was a statistically significant increase in the grasping reflexes of Group B ( $p=0.003$ ) and C ( $p=0.0081$ ) on the third day and in Group L ( $p=0.004$ ) on the fourth day after injections as compared to the first day (Fig. 1). Results of nociception evaluation on response to pain on the first and the fifth phalanges were intact in all groups from the first day onwards.

Histopathological rating of NISS as mild, moderate and severe damage in Group B (35%, 45% and, 20% respectively), Group C (45%, 40% and 15% respectively) and in Group L (20%, 50% and 30%) did not yield statistically significant differences between the groups (Fig. 2).

## Discussion

During regional anesthesia peripheral nerve damage is a rarely observed complication with the incidence varying between 0.5% and 1% in the retrospectively scanned studies. These injuries are mostly reversible and develop as subclinical or mild mononeuropathies. The mechanism of damage developing after intraneural injections has not been completely understood.<sup>3</sup> Conventional local anesthetics are also neurotoxic.<sup>4-6</sup> This damage probably results from mechanical trauma, the chemical and toxic effects of the local anesthetics, ischemia or a combination of these factors.

In our study the response to pain perception from the first to the seventh day after injections was complete and it was the same in all the experimental groups such that no differences could be observed.

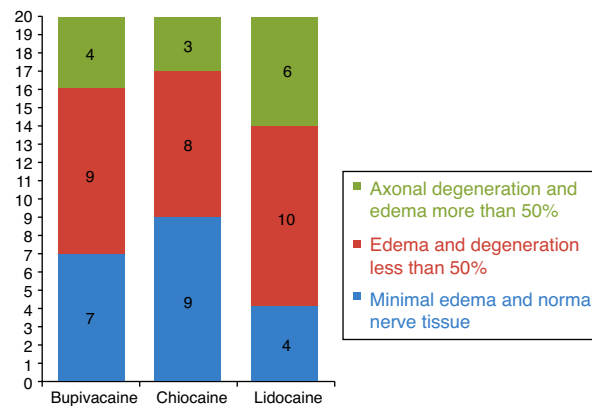


Figure 2 Histopathological rating of NISS.

With respect to the grasping reflex, despite the lack of statistically significant intergroup differences, the seventh day post-injection results showed continuation of slow grasping in 2 rats of Group B, and in 1 rat of Group C, while in Group L, the reflex was absent in 1 rat and slow in 2 rats. Histopathological evaluations showed that 4 rats in Group B, 3 rats in Group C and 6 rats in Group L developed severe axonal degeneration.

Yamashita et al.<sup>4</sup> investigated the neurological and histopathological effects and the glutamate concentration in the cerebrospinal fluid of 5 groups of rats one week after the injection of 0.3 mL NaCl, 2% tetracaine, 10% lidocaine, 2% bupivacaine and 2% ropivacaine. Whereas the CSF glutamate concentrations had significantly increased in all groups; there were no statistically significant differences in the neurological and motor functions between the groups except the lidocaine group that showed significant dysfunction. Histopathological changes were characterized by the width of vacuolation in the dorsal funiculus and was in the respective order of lidocaine = tetracaine > bupivacaine > ropivacaine groups. Similarly, in our study, although statistically significant differences were not observed, the pronounced toxicity of lidocaine was evident with one rat having total loss of motor function with two others showing mild loss.

Histopathological investigation by Yamashita et al.<sup>4</sup> also revealed that although the neuronal damage was equally advanced in the lidocaine and tetracaine injected rats, the neurological and motor function deficit was severer in the lidocaine group which suggests that the margin of safety with lidocaine is very narrow.

Another conflicting observation in our study is that the severity of histopathological damage and the loss of motor function did not progress in parallel. Iohom et al.<sup>7</sup> in a study on 52 rats in 4 groups injected with normal saline, 15% formalin, 0.2% ropivacaine and 0.75% ropivacaine in the left sciatic nerve estimated the motor functions through walking track analysis on days 1, 4, 7, 11, 15, 18, 21 and 67 post-treatment. While no loss of motor function was observed in the saline and ropivacaine groups, a total loss was seen to develop up to the 21st day in the formalin injected rats, which however reverted to complete normality on the 67th day despite the presence of diffuse axonal degeneration as revealed by histological investigations. Similarly, Lupu et al.<sup>8</sup> observed no loss of motor function despite the

histological observation of neuronal damage in 60% of the intraneurally injected pigs. Similarly, in our study, despite the observation of massive axonal degeneration in 4, 3 and 6 rats of, respectively, Groups B, C and L, only mild loss of motor function was observed in 2, 1 and 2 rats of respectively Group B, C and L, with total loss of function in 1 rat of Group L.

Raducan et al.<sup>9</sup> aimed to characterize morphological and functional aspects of sciatic nerve regeneration after mechanical crush injury in rodents. Rat nerve samples were collected before injury and after 24 h, four days, two weeks, and four weeks after injury. They found that morphologic most evident changes caused by axonal degeneration observed after four days post-injury. After four weeks, the number and density of the regenerated myelinated axons were higher compared to controls. About the motor function, they found that marked decrease on function in the first week followed by a gradual recovery of normal gait during the following weeks, so that by the end of the fourth week animal's regained normal gait. Raducan's study differs from ours with respect to generation of a crush injury. In their study, massive axonal degeneration with motor dysfunction and their normalizations coincide. But our study and others, the neurotoxic effect of local anesthetic agents also are present. On the other hand, we evaluated the motor function test till 7 days and took histopathologic specimens on 7th day. However, in the study performed by Iohom et al., evaluation was performed on the 67th day in which the motor dysfunction was improved totally, whereas the massive histopathologic damage continued.

According to our study, intraneural injection of local anesthetics may cause both histopathologic changes and motor deficiency in various frequency and severity in rats. The higher frequency and severity of histopathologic damage more than that of motor deficiency are reasonable, but

histopathological damage and the loss of motor function may not progress in parallel.

## Conflicts of interest

The authors declare no conflicts of interest.

## References

1. Linguory GA. Complications of regional anesthesia: nerve injury and peripheral neural blockade. *J Neurosurg Anesthesiol.* 2004;16:84–6.
2. Bigeleisen PE. Nerve puncture and apparent intraneural injection during ultrasound-guided axillary block does not invariably result in neurologic injury. *Anesthesiology.* 2006;105:779–83.
3. Jeng CL. Intraneural injections and regional anesthesia: the known and unknown. *Minerva Anesthesiol.* 2011;77:54–8.
4. Yamashita A, Matsumoto M, Matsumoto S. A comparison of the neurotoxic effects on the spinal cord of tetracaine, lidocaine, bupivacaine, and ropivacaine administered intrathecally in rabbits. *Anesth Analg.* 2003;97:512–9.
5. Epstein-Barash H, Shichor I, Hwon AH. Prolonged duration local anesthesia with minimal toxicity. *Proc Natl Acad Sci U S A.* 2009;106:7125–30.
6. Miller RD. *Miller's anesthesia.* 7th ed. Philadelphia, PA: Churchill Livingstone/Elsevier; 2010.
7. Iohom G, Lan GB, Diarra DP. Long-term evaluation of motor function following intraneural injection of ropivacaine using walking track analysis in rats. *Br J Anaesth.* 2005;94:524–9.
8. Lupu CM, Kiehl TR, Chan VW. Nerve expansion seen on ultrasound predicts histologic but not functional nerve injury after intraneural injection in pigs. *Reg Anesth Pain Med.* 2010;35:132–9.
9. Raducan A, Mirica S, Duicu O. Morphological and functional aspects of sciatic nerve regeneration after crush injury. *Rom J Morphol Embryol.* 2013;54:735–9.