



## Case Report

# Recovery of Tinnitus and Sensorineural Hearing Loss Due to Lysis of Arachnoid Adhesions in the Posterior Cranial Fossa: Is There a Novel Etiology in Neurotological Disorders?

Raşit Cevizci, Alper Dilci, Ahmet Mahmut Tekin, Yıldırım Bayazıt

Clinic of Ear Nose Throat and Head Neck Surgery, İstanbul Medipol University, İstanbul, Turkey (RC, AMT, YB)  
Clinic of Ear Nose Throat and Head Neck Surgery, Eskişehir Yunus Emre State Hospital, Eskişehir, Turkey (AD)

**Cite this article as:** Cevizci R, Dilci A, Tekin AM, Bayazıt Y. Recovery of Tinnitus and Sensorineural Hearing Loss Due to Lysis of Arachnoid Adhesions in the Posterior Cranial Fossa: Is There a Novel Etiology in Neurotological Disorders? J Int Adv Otol 2017; 13: 295-7.

We reported the recovery of sensorineural hearing loss and tinnitus in a 22-year-old man after complete removal of intracranial portion of jugular foramen schwannoma via the retrosigmoid approach. The aim of this case report was to present the excision of a large jugular foramen schwannoma via the retrosigmoid approach and to describe the improvement of sensorineural hearing loss related to arachnoid inflammations due to chronic arachnoiditis after suboccipital craniectomy. The recovery of sensorineural hearing loss and tinnitus after release of arachnoid adhesions may indicate the clinical significance of these adhesions or arachnoiditis, which should also be considered and investigated in the etiology of other neurotological diseases.

**KEYWORDS:** Tinnitus, schwannoma, skull base approach, jugular foramen mass, retrosigmoid

## INTRODUCTION

Surgical interventions for posterior fossa lesions, such as schwannomas and arachnoid cysts, can lead to hearing loss, which is attributed to various factors, such as surgical trauma, vascular impact, and adhesions on the cochlear nerve. However, the recovery of hearing loss is also possible in some patients who undergo posterior fossa surgery. Arachnoid cyst drainage is one of the interventions, which may result in the recovery of the sensorineural hearing loss<sup>[1]</sup>. One of the rarely reported reasons might be arachnoid adhesions or arachnoiditis. It was proposed that arachnoid inflammations may lead to a reversible hearing loss<sup>[2]</sup>. It was also suggested that a suboccipital craniectomy might lead to a marked improvement in symptoms, which occur after chronic arachnoiditis<sup>[3]</sup>.

Here, we report the recovery of sensorineural hearing loss and tinnitus after complete removal of schwannoma in posterior cranial fossa. The possible mechanisms related to occurrence and recovery of the auditory symptoms are discussed.

## CASE PRESENTATION

This presentation was approved by a local institutional ethical committee and informed consent of the patient was obtained prior to study preparation. A 22-year-old male was presented with progressively distressing tinnitus on the left ear for 2 years. One year ago, he was seen by another Ear, Nose, and Throat (ENT) physician due to the same complaint; however, a follow-up was recommended since his physical examination and audiometric findings were normal.

Physical examination revealed that the tongue was deviating to left when protruded. There was also vocal cord paralysis on the left side. However, the patient did not have any hoarseness or aspiration.

Pure tone and speech audiometry revealed a mild sensorineural loss of approximately 4 kHz and a speech discrimination score 100% for the right ear and 72% for the left ear (Figure 1). Tympanometry was normal. Magnetic resonance imaging (MRI) of the temporal bone and skull base disclosed a heterogeneous, dumbbell-shaped mass with size 5×3×4 cm. The mass was occupying

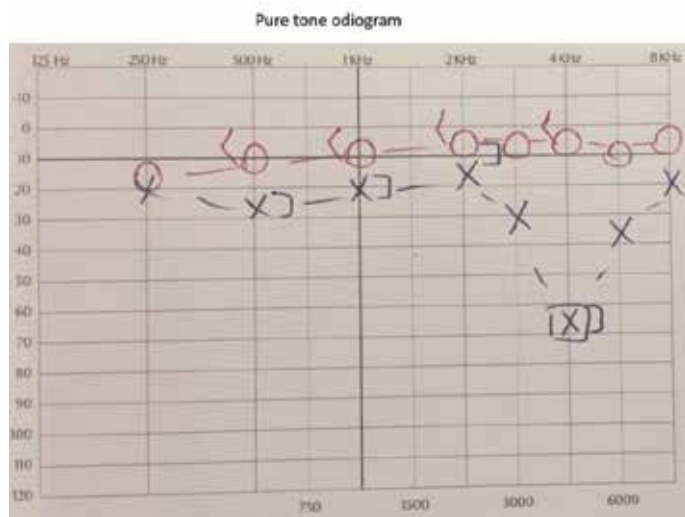

Figure 1. Pure tone audiometry and speech discrimination findings.

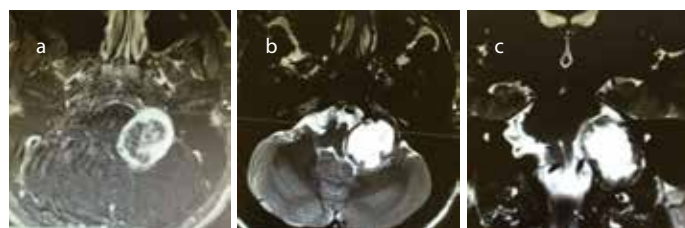


Figure 2. a-c. (a) T1-weighted transverse MRI image of tumor occupying pontocerebellar triangle (b) T1-weighted fat suppressed transverse MRI image of tumor occupying pontocerebellar triangle and jugular foramen. (c) T2-weighted coronal MRI image of tumor occupying pontocerebellar triangle extending through to the neck.

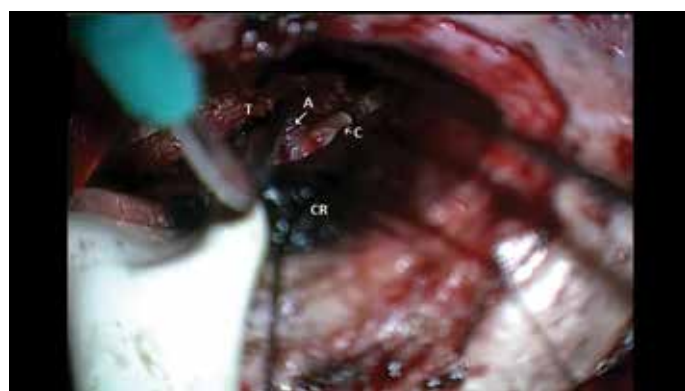

Figure 3. Intraoperative image that shows the arachnoid adhesions between the tumor and cochlear nerve.  
T: tumor, A: adhesions, C: cochlear nerve, CR: cerebellum

the caudal portion of pontocerebellar area and jugular foramen with some extension to the neck on the left side. MRI was suggestive of schwannoma with sharply demarcated configuration and low T1 and high T2 signal intensity (Figure 2).

A retrosigmoid approach was used to remove the tumor. The tumor was completely occupying the caudal portion of the cerebellopontine area, causing distortion in the lower cranial nerves. The tumor was approximating to the cochleovestibular and facial nerves in their distal cisternal portions. There were a few arachnoid adhesions between the tumor and cochleovestibular nerve, which were pulling

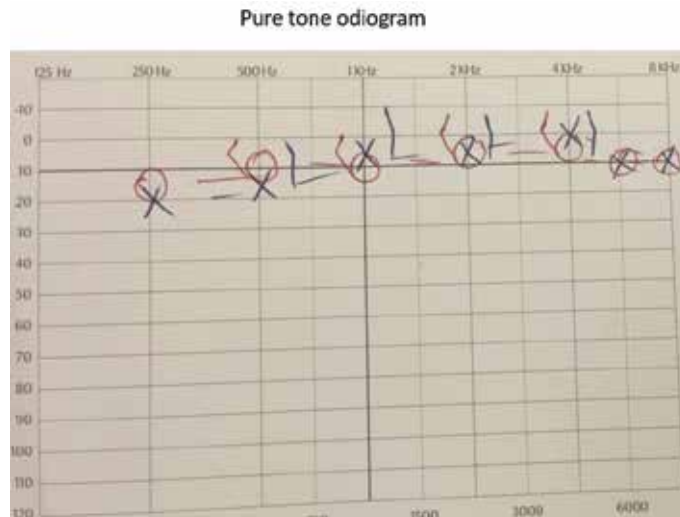


Figure 4. Postoperative audiogram that shows the recovery of hearing loss.

a few nerve fibers away from the cochlear nerve and were released with a sharp dissection (Figure 3; Video 1).

The intracranial portion was completely removed. The extracranial portion was retained for a staged surgery to avoid cerebrospinal fluid leakage. The operation and postoperative period was uneventful. The patient mentioned recovery in tinnitus and hearing after the operation. The postoperative audiogram after 10 days confirmed the recovery in sensorineural hearing loss (Figure 4).

**DISCUSSION**

Jugular foramen schwannoma is a benign rarely observed tumor that extends into the cerebellopontine angle or extends into the parapharyngeal space. Depending on the tumor characteristics, many complications may be observed; sensorineural hearing loss is one of the first manifestations. Although reversible hearing loss has been documented after surgical excision of this tumor, irreversible hearing loss has been reported in many of these surgeries [4].

Different surgical approaches to access the cerebellopontine angle were described. According to Samii et al, surgical approach to jugular foramen schwannoma should be selected individually based upon their extension pattern [5]. Hearing preservation is important and enlarged middle fossa approach is the one of the surgical methods for resection of schwannomas, while preserving of cochlear functions [6]. In most of the cases, prognosis of hearing level is poor in resection of jugular foramen schwannomas. Changes of hearing level and recovery of hearing and tinnitus after surgery of cerebellopontine angle and posterior fossa remain unclear. In 1983, Wigand et al described microsurgical neurolysis of the eighth cranial nerve in cochleovestibular disorders. Traction and compression of nerve fibers, accompanying vascular effect were observed in this study. The eighth cranial nerve was neurolysed to treat these functional disturbances. Although unsatisfactory, the results of this study shows the possibility of recovery of hearing, tinnitus, and other functional disturbances [7].

The clinical presentation of jugular foramen schwannoma depends on the tumors extension rather than the corresponding nerve of origin [8], as in our patient who presented with unilateral tinnitus. Prior

to the operation, the patient was counseled about the possibility of hearing loss after the surgery. However, the postoperative recovery of sensorineural hearing loss and tinnitus necessitates further evaluation of this phenomenon.

Arachnoid adhesions of the cerebellopontine angle may damage the cochleovestibular nerve and cause hearing loss<sup>[9]</sup>. It is possible to visualize arachnoid adhesions in the posterior fossa in some of the surgeries of schwannomas, microvascular decompressions, vestibular nerve sectioning, and auditory brainstem implantations. In 1979, Innitzer et al reported a case of cerebellopontine angle tumor in which the release of dense fibrotic tissues extending from the choroid plexus to the acoustic nerve lead to hearing improvement in the low frequencies<sup>[10]</sup>.

Although there are a few reports about the recovery or stabilization of sensorineural hearing loss after posterior fossa interventions, these are cases of arachnoid cysts. Recovery of hearing loss secondary to posterior fossa arachnoid cyst surgery in a pediatric patient has been reported<sup>[11]</sup>. It was reported that even the fenestration of the arachnoid cyst lead to recovery from sensorineural hearing loss in an adult patient<sup>[1,12]</sup>. According to another case report, cyst decompression could stop progression of hearing loss and render tinnitus more tolerable<sup>[13]</sup>. Oishi et al described an improvement in hearing level after resection of the intracranial portion of jugular foramen schwannoma via retrosigmoidal craniectomy. They hypothesized that compression neuropathy and biochemical changes in axons results hearing disturbances, and a well-preserved cochlear function may indicate recovery of hearing<sup>[4]</sup>. Hearing improvement was seen after resection of a large schwannoma, and Lekovic et al.<sup>[14]</sup> believed that extrinsic compression to the brainstem may contribute to the hearing. Yamakami et al.<sup>[15]</sup> described two cases with recovery of hearing after resection of schwannomas via the lateral suboccipital retrosigmoid approach. These tumors are the intracranial type of jugular foramen schwannomas, and there is no extracranial invasion despite our study. Yamakami et al. [15] pointed that arachnoidal tissue is the main protector of internal auditory artery and cochlear nerve. Gentle dissection of arachnoid fibers may be important in achieving good hearing results.

The cochlear nerve occupies the inferior portion of the cochleovestibular nerve in the cerebellopontine area. The nerve fibers carrying the high frequency sound information are located at the periphery of the cochlear nerve. Accordingly, the fibers pulled by arachnoid adhesions were carrying the information for approximately 4 kHz areas within the cochlear portion of the cochleovestibular nerve. Separation of these fibers from the main trunk of the cochlear nerve might have caused blockage in the axonal conduction as in neuropraxia. In addition, the same effect might have led to an ephaptic stimulation or auditory dysynchrony resulting in tinnitus. Since the tinnitus recovered after the operation and release of the arachnoid adhesions, reorganization in the auditory tonotopicity seems unlikely. If not, we would expect perpetuation of the tinnitus.

## CONCLUSION

There are only a few case reports regarding the recovery of sensorineural hearing loss after posterior fossa surgery, and almost all of them are arachnoid cyst cases. Our patient is the first case of jugular foramen schwannoma for whom hearing recovered after surgery. However, more importantly, the recovery of sensorineural hearing loss after re-

lease of arachnoid adhesions may indicate the clinical significance of these adhesions or arachnoiditis, which should also be considered and investigated in the etiology of other neurotological diseases.

## Video 1. Surgery of jugular foramen schwannoma.

**Informed Consent:** Written informed consent was obtained from patient who participated in this study.

**Peer-review:** Externally peer-reviewed.

**Author Contributions:** Concept - R.C., Y.B.; Design - A.D.; Supervision - R.C., Y.B.; Resources - A.M.T., Y.B.; Materials - A.M.T.; Data Collection and/or Processing - A.D., A.M.T.; Analysis and/or Interpretation - A.D., R.C., Y.B.; Literature Search - A.D.; Writing Manuscript - A.D., Y.B.; Critical Review - R.C., Y.B.

**Conflict of Interest:** No conflict of interest was declared by the authors.

**Financial Disclosure:** The authors declared that this study has received no financial support.

## REFERENCES

- Olaya JE, Ghostine M, Rowe M, Zouros A. Endoscopic fenestration of a cerebellopontine angle arachnoid cyst resulting in complete recovery from sensorineural hearing loss and facial nerve palsy. *J Neurosurg Pediatr* 2011; 7: 157-60. [\[CrossRef\]](#)
- Innitzer J. Reversible deafness as model of pressure damage to the VIIIth nerve. *ORL J Otorhinolaryngol Relat Spec* 1976; 38: 328-33. [\[CrossRef\]](#)
- Ebina K, Suzuki S, Iwabuchi T. Clinical study of chronic arachnoiditis in the posterior fossa. *Acta Neurochir (Wien)* 1976; 33: 69-81. [\[CrossRef\]](#)
- Oishi N, Kohno N, Shiokawa Y. Severe progressive sensorineural hearing loss improved after removal of large jugular foramen schwannoma. *Auris Nasus Larynx* 2011; 38: 398-401. [\[CrossRef\]](#)
- Samii M, Alimohamed M, Gerganov V. Surgical treatment of jugular foramen schwannoma: surgical treatment based on a new classification. *Neurosurgery* 2015; 77: 424-32. [\[CrossRef\]](#)
- Wigand ME. Enlarged middle fossa approach to the cerebellopontine angle. Technique and indications. *Rev Laryngol Otol Rhinol (Bord)* 1998; 119: 159-62.
- Wigand ME, Haid T, Berg M, Rettinger G. Microsurgical neurolysis of the 8<sup>th</sup> cranial nerve in cochlea-vestibular disorders using an extended transtemporal approach. *HNO* 1983; 31: 295-302.
- Kadri PA, Al-Mefty O. Surgical treatment of dumbbell-shaped jugular foramen schwannomas. *Neurosurg Focus* 2004; 17: E9. [\[CrossRef\]](#)
- Ehrenberger K, Innitzer J, Koos W. Successful decompression of the acoustic nerve after postarachnoid hearing damage. *Laryngol Rhinol Otol (Stuttg)* 1976; 55: 561-6.
- Innitzer J, Ehrenberger K, Emami-Nouri M, Brenner H. A case of reversible deafness in cystic arachnoiditis. *Wien Klin Wochenschr* 1976; 88: 668-9.
- Jayaram M, Devaiah AK, Chin LS. Recovery of sensorineural hearing loss following operative management of a posterior fossa arachnoid cyst. Case report. *J Neurosurg Pediatr* 2009; 4: 121-4. [\[CrossRef\]](#)
- Lanzino G, diPierro CG, Ruth RA, Helm G, Jane JA. Recovery of useful hearing after posterior fossa surgery: the role of otoacoustic emissions: case report. *Neurosurgery* 1997; 41: 469-73. [\[CrossRef\]](#)
- Ottaviani F, Neglia CB, Scotti A, Capaccio P. Arachnoid cyst of the cranial posterior fossa causing sensorineural hearing loss and tinnitus: a case report. *Eur Arch Otorhinolaryngol* 2002; 259: 306-8.
- Lekovic GP, Gonzalez LF, Weisskopf P, Smith KA. Hearing improvement after resection of a large jugular foramen schwannoma: case report. *Skull Base* 2008; 18: 195-9. [\[CrossRef\]](#)
- Yamakami I, Nakamura T, Ono J, Yamaura A. Recovery of hearing after removal of a large jugular foramen schwannoma. *Surg Neurol* 1999; 51: 60-5. [\[CrossRef\]](#)