

Significant Contribution of *Fluorodeoxyglucose* Positron Emission Tomography/Computed Tomography (FDG PET/CT) in a Case of Acute Lymphoblastic Leukemia Presenting with Fever of Unknown Origin

Ferhat Arslan¹, Mesut Yılmaz¹, Tansel Çakır² and Ali Mert³

Abstract

The diagnostic value of *fluorodeoxyglucose* positron emission tomography/computed tomography (FDG PET/CT) has not been thoroughly evaluated in patients with leukemia. We herein report the case of a patient with B cell acute lymphoblastic leukemia (ALL) presenting with fever of unknown origin (FUO) who was diagnosed after FDG PET/CT indicated diffuse bone marrow involvement.

Key words: positron emission tomography, fever of unknown origin, leukemia

(Intern Med 53: 789-791, 2014)

(DOI: 10.2169/internalmedicine.53.1443)

Introduction

Diseases that cause fever of unknown origin (FUO) range from infections to malignancies and autoimmune diseases (1). In recent years, *fluorodeoxyglucose* positron emission tomography/computed tomography (FDG PET/CT) has been used as the last resort diagnostic modality in FUO patients, with great success, where conventional methods have failed (2, 3). Both anatomic and metabolic information has proved to have significant benefits in the diagnostic workup of FUO. We herein report the case of a patient with B cell acute lymphoblastic leukemia (ALL) presenting with FUO who was diagnosed after FDG PET/CT showed diffuse bone marrow involvement.

Case Report

A 51-year-old man was referred to our hospital due to a high fever and asthenia for the previous four months. The findings of a physical examination were normal, except for hepatomegaly. A hemogram showed a white blood cell count of 5,480/mm³ (neutrophils, 37.6%; basophils, 3.4%; monocytes, 24.7%; lymphocytes, 34.3%), a hemoglobin

level of 10.7 g/dL and a platelet count of 238,000/mm³. Routine biochemistry tests were normal, except for the erythrocyte sedimentation rate (101; normal range <20/hour) and levels of serum ferritin (1,827; normal range 30-400), triglycerides (232; normal range <150 mg/dL), lactate dehydrogenase (1,091 IU/L; normal range, 135 to 225 IU/L) and C-reactive protein (69.46 mg/L; normal range, <5 mg/L). Contrast-enhanced thorax and abdominal computed tomography revealed no evidence of abnormalities, except for hepatomegaly (190 mm). FDG PET/CT performed to rule out any possible malignant neoplasms showed a diffuse high FDG uptake in the bone marrow (Figure). A bone marrow biopsy revealed 30% lymphoblasts, and the results of a flow cytometric immunophenotypic analysis were compatible with the findings of precursor B cell lymphoblastic leukemia. A flow cytometric immunophenotyping analysis showed that approximately 44% leukemic cells expressed CD19, CD20, CD22, CD10 and CD34 Tdt+ antigens, compatible with a diagnosis of precursor B cell lymphoblastic leukemia. breakpoint cluster region (BCR)/ABL was negative using the polymerase chain reaction (PCR) method. No abnormalities were found in the bone marrow karyotype analysis.

¹Infectious Disease, Istanbul Medipol University, Turkey, ²Nuclear Medicine, Istanbul Medipol University, Turkey and ³Internal Medicine, Istanbul Medipol University, Turkey

Received for publication July 25, 2013; Accepted for publication October 20, 2013

Correspondence to Dr. Ferhat Arslan, ferhatarslandr@hotmail.com

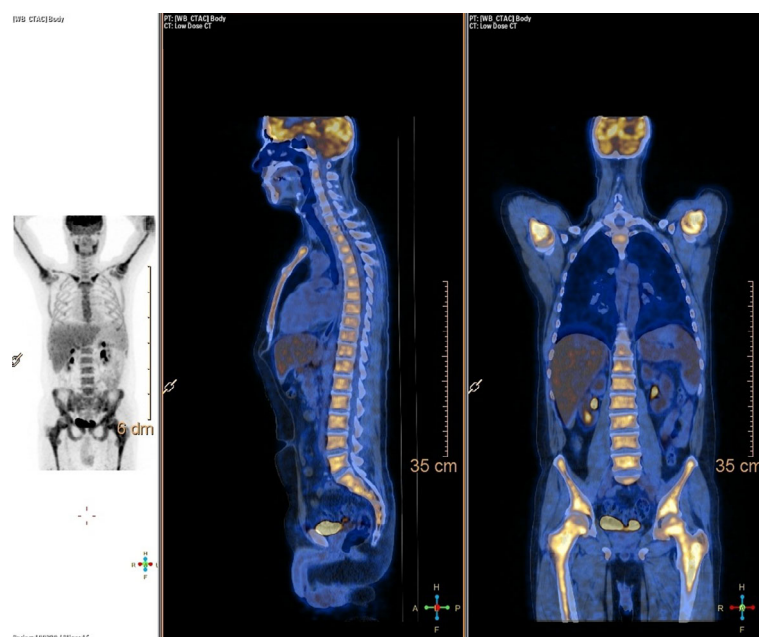


Figure. On PET/CT images bone marrow has diffuse increased uptake with a standardized uptake value (SUVmax value) of 8 at the caput of femur. Liver to spleen ratio is in normal limits. Scanning of the lower limb shows that increased metabolic activity of bone marrow also includes appendicular skeletal system. There are no pathological lymph nodes in the body. Lung parenchyma and abdominal organs have normal findings. Bone marrow also includes appendicular skeletal system. There are no pathological lymph nodes in the body. Lung parenchyma and abdominal organs have normal findings.

Discussion

PET/CT is a very important tool in the diagnosis and staging of hematological malignancies, particularly lymphomas. Case reports showing the diagnostic value of PET/CT in various forms of leukemia, including intramedullary and extramedullary relapse of acute myeloid leukemia, myeloid sarcoma, plasma cell leukemia and NK-cell leukemia, have been reported (4-9).

We found two cases of ALL diagnosed incidentally on PET/CT scanning during our search of the medical literature (10, 11). Ennishi et al. reported a patient referred to their hospital with a long-term fever and diffuse bone pain. Routine hematologic and radiologic (CT and MRI techniques) investigations did not reveal any abnormalities. FDG PET/CT showed a diffuse and increased bone marrow uptake, and the bone marrow aspirate revealed 98% lymphoblasts (10). In the second case, FDG PET/CT was performed to detect and evaluate an inflammatory focus in a patient with FUO. Diffuse homogeneous FDG uptake was observed in the bone marrow without splenomegaly. The final diagnosis was ALL (11).

In recent years, PET/CT has become a critical diagnostic tool in patients with FUO as a last resort procedure (12). This modality has made a significant contribution to the differential diagnosis of FUO. Keidar et al. reported that PET/CT identified the underlying cause of fever in 22 (46%) of

48 patients and contributed to the diagnosis in 90% of the patients (13). Bleeker-Rovers et al. evaluated the distribution of diagnosis among patients with FUO based on published cases. They reported that the percentage of undiagnosed patients with FUO has increased from 9% to 51%, albeit in association with the development of medical diagnostic procedures, in the last fifty years (14).

In conclusion, if PET/CT reveals a diffuse high FDG uptake in the bone marrow on an evaluation of FUO while the examination of the peripheral blood shows no remarkable abnormalities, then a bone marrow biopsy should be considered in order to make a diagnosis of hematological malignancy.

The authors state that they have no Conflict of Interest (COI).

References

- Hayakawa K, Ramasamy B, Chandrasekar PH. Fever of unknown origin: an evidence-based review. *Am J Med Sci* **344**: 307-316, 2012.
- Meller J, Sahlmann CO, Gürocak O, Liersch T, Meller B. FDG-PET in patients with fever of unknown origin: the importance of diagnosing large vessel vasculitis. *Q J Nucl Med Mol Imaging* **53**: 51-63, 2009.
- Kumar R, Basu S, Torigian D, Anand V, Zhuang H, Alavi A. Role of modern imaging techniques for diagnosis of infection in the era of 18F-fluorodeoxyglucose positron emission tomography. *Clin Microbiol Rev* **21**: 209-224, 2008.

4. Stölzel F, Röllig C, Radke J, et al. ¹⁸F-FDG-PET/CT for detection of extramedullary acute myeloid leukemia. *Haematologica* **96**: 1552-1556, 2011.
5. Schollaert P, Loosen C, André M, Chatelain B, Krug BMG. An atypical relapse of acute myeloid leukemia diagnosed by 18F-FDG PET/CT. *Clin Nucl Med* **37**: 1018-1021, 2012.
6. Cocciolillo F, Treglia G, Villani MF, Giordano A. Atypical presentation of plasma cell leukemia secondary to multiple myeloma detected by F-18 FDG PET/CT. *Clin Nucl Med* **36**: e220-e223, 2011.
7. Rao S, Langston A, Galt JR, Halkar RK. Extramedullary acute myeloid leukemia and the use of FDG-PET/CT. *Clin Nucl Med* **34**: 365-366, 2009.
8. Derlin T, Mester J, Klutmann S. F-18 FDG PET/CT findings of aggressive NK-cell leukemia. *Clin Nucl Med* **36**: 932-933, 2011.
9. Paolini R, Bianchini E, D'Andrea E, et al. FDG-PET detection of primary bone marrow large B-cell lymphoma in a patient with hairy cell leukemia. *Nucl Med Rev Cent East Eur* **10**: 23-25, 2007.
10. Ennishi D, Maeda Y, Niiya M, Shinagawa K, Tanimoto M. Incidental detection of acute lymphoblastic leukemia on [18F]fluorodeoxyglucose positron emission tomography. *J Clin Oncol* **27**: e269-e270, 2009.
11. Su K, Nakamoto Y, Nakatani K, Kurihara K, Hayakawa N, Togashi K. Diffuse homogeneous bone marrow uptake of FDG in patients with acute lymphoblastic leukemia. *Clin Nucl Med* **38**: e33-e34, 2013.
12. Halcin A, Kinova S. Contribution of PET/CT imaging to differential diagnosis of fever of unknown origin. *Bratisl Lek Listy* **114**: 67-70, 2013.
13. Keidar Z, Gurman-Balbir A, Gaitini D, Israel O. Fever of unknown origin: the role of 18F-FDG PET/CT. *J Nucl Med* **49**: 1980-1985, 2008.
14. Bleeker-Rovers CP, Vos FJ, de Kleijn EMHA, et al. A prospective multicenter study on fever of unknown origin: the yield of a structured diagnostic protocol. *Medicine (Baltimore)* **86**: 26-38, 2007.