

Mid-Term Results of Two Different Fixation Methods for Chevron Osteotomy for Correction of Hallux Valgus

Baran Komur, MD ¹, Baris Yilmaz, MD ², Erdem Kaan, MD ³, Bulent Yucel, MD ¹, Tahir Mutlu Duymus, MD ¹, Guzelali Ozdemir, MD ², Olcay Guler, MD ⁴

¹Orthopedist, Kanuni Sultan Suleyman Training and Research Hospital, Istanbul, Turkey

²Orthopedist, Fatih Sultan Mehmet Training and Research Hospital, Istanbul, Turkey

³Orthopedist, Dr. Ersin Arslan Training and Research Hospital, Gaziantep, Turkey

⁴Orthopedist, Department of Orthopaedics and Traumatology, Medipol University, Istanbul, Turkey

ARTICLE INFO

Level of Clinical Evidence: 3

Keywords:

bioabsorbable pins
cannulated screws
chevron osteotomy
fixation methods
hallux valgus

ABSTRACT

We compared 2 different fixation methods (bioabsorbable pins and cannulated screws) after chevron osteotomy for the treatment of hallux valgus. We reviewed consecutive proximal chevron osteotomies in 80 patients (100 feet) performed by 2 surgeons. Of the 100 feet (80 patients), 48 feet (40 patients) were stabilized with bioabsorbable pins, and 52 feet (40 patients) were stabilized with cannulated screws. In the pin group, 8 patients were male (20%) and 32 were female (80%). In the screw group, 10 patients were male (25%) and 30 were female (75%). The mean patient age was 43.1 (range 24 to 60) years in the pin group and 43.5 (range 20 to 60) years in the cannulated screw group. The visual analog scale, intermetatarsal angle, and hallux valgus angle decreased significantly and the American Orthopaedic Foot and Ankle Society scores increased significantly in all patients in both groups after surgery ($p < .05$). No statistically significant differences were found between the 2 groups ($p > .05$). Both fixation methods were found to be safe and reliable under the appropriate conditions and when performed by an experienced surgeon.

© 2018 by the American College of Foot and Ankle Surgeons. All rights reserved.

Hallux valgus is the most common problem of the forefoot in adults (1). It is progressive and involves several stages, beginning with lateral deviation of the great toe (hallux) and medial deviation of the first metatarsal (metatarsus primus varus) (2). Management of hallux valgus generally begins with conservative treatment, especially in juvenile hallux valgus. Surgical correction is indicated for cases of failed conservative management, progressive and painful deformity, or disruption of lifestyle or activity (3).

More than 140 surgical procedures have been described to correct hallux valgus. The chevron osteotomy has become widely accepted for correction of mild to moderate hallux valgus deformities (4). This technique includes removal of the medial eminence and a horizontally directed V-shaped osteotomy of the distal first metatarsal (5). The indications for this procedure include the following: failed conservative treatment, mild to moderate deformity (metatarsophalangeal

angle $<35^\circ$ and an intermetatarsal angle [IMA] $<15^\circ$), and the absence of arthritis in the first metatarsophalangeal joint.

Currently, nondegradable implants are primarily made of steel or titanium. Although these implants provide maximum stability, the disadvantages include interference with imaging modalities such as direct radiography and magnetic resonance imaging. In addition, they might require an undesirable second operation for hardware removal. Moreover, the mechanical properties of nondegradable implants are quite different from those of cortical bone, potentially resulting in inhomogeneous stress transfer and limited bone healing. This constellation of effects is referred to as “stress shielding.” Therefore, it might be beneficial to use implants with a Young’s modulus close to that of cortical bone. Biodegradable implants are currently in clinical use for fixation in distal chevron osteotomies. These implants are mechanically weaker than their metallic counterparts and have been associated with foreign body reactions and osteolysis (6,7). However, bioabsorbable pins have been shown to provide a similar correction of the IMA and to have comparable rates of complications compared with cannulated screws (8).

The aim of the present study was to compare the outcomes using cannulated screws and bioabsorbable pins for fixation after chevron osteotomy in the surgical treatment of hallux valgus.

Financial Disclosure: None reported.

Conflict of Interest: None reported.

Address correspondence to: Baran Komur, MD, Kanuni Sultan Suleyman Training and Research Hospital, Turgut Ozal Street, No:1, Halkali, Kucukcekmece, Istanbul, Turkey.
E-mail address: barankomur@gmail.com (B. Komur).

Patients and Methods

We reviewed 100 distal chevron osteotomies in 80 patients performed by 2 surgeons (B.K., B.Y.) from March 2014 to February 2016. Our local ethics committee approved the study. The mean follow-up period was 14 (range 2 to 27). All the patients provided written informed consent before enrollment in the study. Of the 100 feet, 48 feet (40 patients) were stabilized with bioabsorbable pins by 1 surgeon (B.K.) and 52 feet (40 patients) were stabilized with cannulated screws performed by 1 surgeon (B.Y.). This method was chosen to minimize surgical bias. In the pin group, 8 patients were male (20%) and 32 were female (80%). In the screw group, 10 patients were male (25%) and 30 were female (75%). The mean patient age was 43.1 (range 24 to 60) years in the pin group and 43.5 (range 20 to 60) years in the cannulated screw group. Patients with rheumatoid arthritis, hallux rigidus, or failed previous hallux valgus surgery were excluded from the present study. Clinical results were obtained using the American Orthopaedic Foot and Ankle Society (AOFAS) ankle-hindfoot score and the visual analog scale (VAS) for pain. Radiographically, the hallux valgus angle (HVA) (Fig. 1), IMA (Fig. 2), and distal metatarsal articular angle (DMAA) (Fig. 3) were measured and compared between the 2 groups. The HVA was measured as the angle between the center of the longitudinal axis of the first metatarsal and the axis of the great toe. The IMA was measured as the angle between the line of the first metatarsal and the line bisecting the diaphyseal portions of the second metatarsal. Finally, DMAA was calculated as the angle between the articular surface of the distal first metatarsal and the longitudinal axis of the first metatarsal.

Surgical Technique

The surgical technique used for both study groups was the same except that different implants were used, as described. The chevron osteotomy was performed in both groups through a medial longitudinal incision starting from the base of the proximal phalanx and extending 5 to 7 cm proximally to the metatarsal head. The subcutaneous tissue and bursa were dissected, and the capsule of the joint was identified. The capsule of the joint was incised in a Y-shaped fashion, and a straight longitudinal incision was continued out to the bone. The toe was then adducted, and a bunionectomy was performed using an oscillating saw. The medial eminence was removed, and the “V” osteotomy was performed with an angle of 50° to 60° between the cuts. After the osteotomy had been completed, the distal metatarsal head was slid laterally and

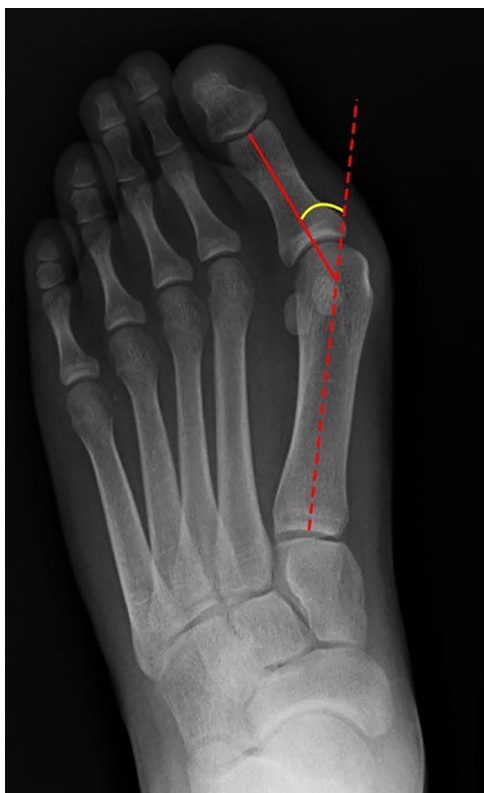

Fig. 1. Plain radiograph showing hallux valgus angle of the first metatarsal.

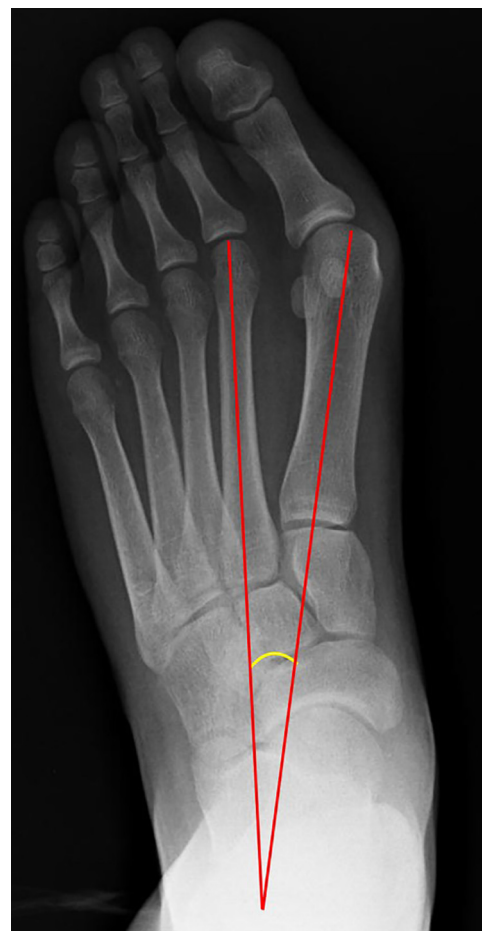

Fig. 2. Plain radiograph showing intermetatarsal angle of the hallux.

displaced 3 to 4 mm. Once this displacement was complete, the osteotomy site was first fixed with Kirschner wires, after which bioabsorbable pins composed of biodegradable copolymers L-lactide, D,L-lactide, and trimethylene carbonate (OTPS Biodegradable Pins, Inion, Tampere, Finland) or cannulated screws (Herbert headless cannulated titanium screws, TST Tibbi Aletler San., Istanbul, Turkey) were applied to hold the fragments in position (Fig. 4). Postoperatively, all operative feet in both groups were placed in a splint for ~3 weeks, and weightbearing on the first toe was not allowed until the seventh postoperative week (Fig. 5). No differences were found in terms of the surgical approach or postoperative management for the patients in either group.

Statistical Analysis

Descriptive statistics were used to describe the continuous dependent variables (mean, standard deviation, minimum, median, and maximum). The Wilcoxon signed-rank test was used to compare the dependent data that were not normally distributed, and the Mann-Whitney *U* test was used to compare the independent data that were not normally distributed. Data were deemed statistically significant when $p < .05$. All analyses were performed using MedCalc Statistical Software, version 12.7.7 (MedCalc, Ostend, Belgium; available at: <http://www.medcalc.org>; 2013).

Results

We compared the age and sex distribution between the bioabsorbable pin and cannulated screw groups and found no statistically significant difference between them (Tables 1 and 2).

Changes in the HVA, IMA, and DMAA with respect to the time after surgery in the 2 groups are presented in Tables 3–5. Preoperatively,

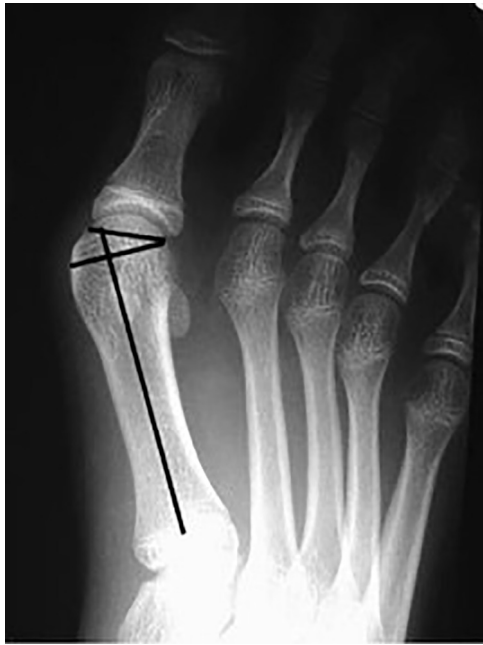

Fig. 3. A hallux valgus radiograph of a juvenile showing the distal metatarsal articular angle of the hallux.

no differences were found in any of these angles between the 2 groups. Postoperatively, a significant decrease in the HVA was observed in both the bioabsorbable pin and the cannulated screw groups, and the reduction was similar between the 2 groups ($p = .858$). The IMA in the pin and screw groups decreased significantly after surgery compared with the preoperative measurements ($p < .001$, for both groups), and the reduction was similar for both groups ($p = .495$). The DMAA in the pin and screw groups also decreased significantly postoperatively compared with preoperatively ($p < .001$, for both groups). Also, the reduction was similar for both groups ($p = .618$; [Tables 3–5](#)).

The VAS scores in the pin and screw groups had decreased significantly postoperatively compared with preoperatively ($p < .001$, for both groups). The decrease was also similar for both groups ($p = .629$; [Table 6](#)).

The AOFAS ankle-hindfoot scale scores in the pin and screw groups were significantly increased postoperatively compared with before

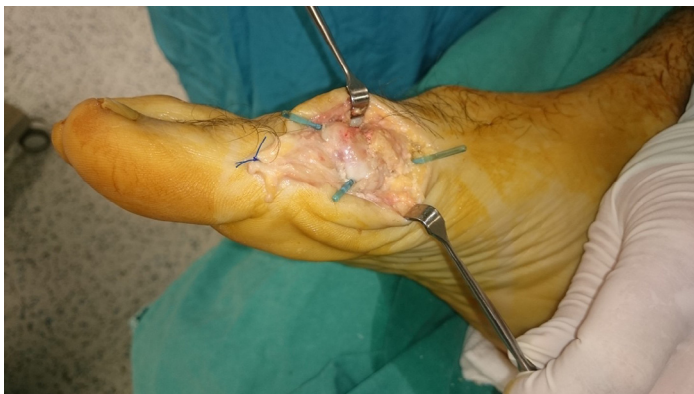


Fig. 4. Intraoperative photograph showing insertion of the bioabsorbable pin across the osteotomy site after bunionectomy.

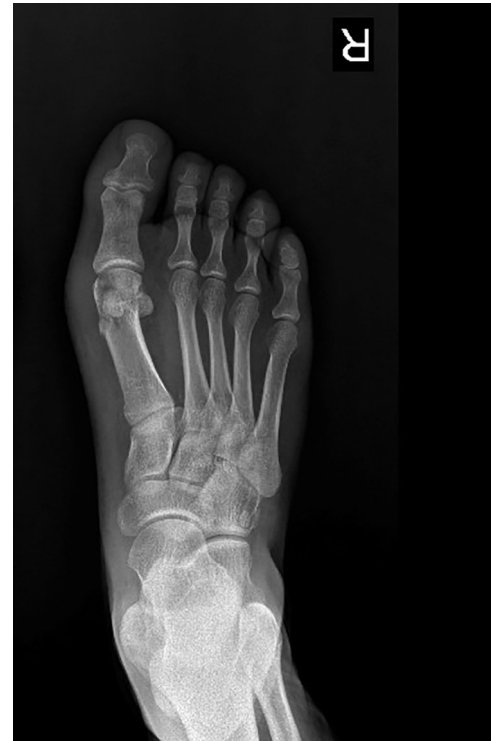

Fig. 5. Postoperative radiographs of a chevron osteotomy with bioabsorbable pins used for fixation.

surgery ($p < .001$, for both groups). This increase was also similar for both groups ($p = .119$; [Table 7](#)).

Four patients in group 1 and two in group 2 developed superficial wound infections that healed after superficial debridement. Loss of correction was not observed in any patient.

Discussion

Since Austin and Leventen first described the chevron osteotomy for the treatment of symptomatic hallux valgus, the procedure has been

Table 1
Gender distribution stratified by study group

Fixation Method	Male Patients	Female Patients	Total
Pin	8 (20)	32 (80)	40 (100)
Screw	10 (25)	30 (75)	40 (100)
Total	18 (22.5)	62 (77.5)	80 (100)

Data presented as n (%).
 $p = .592$, χ^2 test.

Table 2
Demographic information of study groups stratified by age

Variable	Age (y)		
	Pin Group	Screw Group	Whole Group
Patients (n)	40	40	80
Mean	43.1	43.5	43.3
Median	43.0	45.5	43.0
Standard deviation	11.5	11.8	11.6
Minimum	24.0	20.0	20.0
Maximum	60.0	60.0	60.0

$p = .857$. Mann-Whitney *U* test.

Table 3
Preoperative and postoperative hallux valgus angle stratified by treatment group

Variable	Pin Group			Screw Group		
	Pre-HVA	Post-HVA	Difference	Pre-HVA	Post-HVA	Difference
Patients (n)	40	40	40	40	40	40
Mean	32.850	12.825	-20.0	32.800	12.725	-20.07
Median	33.000	13.000	-20.0	33.000	13.500	-20.00
Standard deviation	1.1886	0.6751	1.1	2.2326	1.9214	3.30
Minimum	30.0	12.0	-21.0	29.0	10.0	-26.00
Maximum	34.0	14.0	-17.0	36.0	15.0	-14.00
p Value*	< .001			< .001		

Abbreviations: HVA, hallux valgus angle; Pre-HVA, preoperative HVA; Post-HVA, postoperative HVA.

* Wilcoxon signed rank test.

modified to improve stability by incorporating various internal fixation methods (7,8). These have included Kirschner wires, metal screws, metal plates, staples, and, more recently, bioabsorbable pins (7,8).

Screw fixation has become widely used owing to its ease of use and the absence of an externally protruding wire, which decreases the risk of skin irritation and pin tract infection (9). This technique has

generally been performed on younger patients who have good bone quality. Herbert screws, cortical screws, and Acutrak compression screws can be used for fixation of chevron osteotomies. The cannulated Acutrak screws have the advantage of providing greater compression and more solid bony union. Furthermore, removal of the screw has only been required in rare cases. Toorney and McGarvey

Table 4
Preoperative and postoperative intermetatarsal angle stratified by treatment group

Variable	Pin Group			Screw Group		
	Pre-IMA	Post-IMA	Difference	Pre-IMA	Post-IMA	Difference
Patients (n)	40	40	40	40	40	40
Mean	17.72	7.50	-10.22	17.525	7.65	-9.87
Median	18.00	7.50	-11.00	18.00	8.00	-10.0
Standard deviation	0.9334	0.5064	1.0497	1.4848	0.5796	1.712
Minimum	16.0	7.0	-11.00	14.0	7.0	-12.00
Maximum	19.0	8.0	-8.00	19.0	9.0	-6.00
p Value*	< .001			< .001		

Abbreviations: IMA, intermetatarsal angle; Pre-IMA, preoperative IMA; Post-IMA, postoperative IMA.

* Wilcoxon signed rank test.

Table 5
Preoperative and postoperative distal metatarsal articular angle stratified by treatment group

Variable	Pin Group			Screw Group		
	Pre-DMAA	Post-DMAA	Difference	Pre-DMAA	Post-DMAA	Difference
Patients (n)	40	40	40	40	40	40
Mean	15.600	9.000	-6.60	15.57	9.075	-6.500
Median	15.000	9.000	-7.00	15.00	9.000	-7.000
Standard deviation	0.7779	0.9058	0.9554	0.6751	1.1851	1.3587
Minimum	15.0	8.0	-8.00	15.0	7.0	-9.00
Maximum	17.0	11.0	-5.00	17.0	11.0	-4.00
p Value*	< .001			< .001		

Abbreviations: DMAA, distal metatarsal articular angle; Pre-DMAA, preoperative DMAA; Post-DMAA, postoperative DMAA.

* Wilcoxon signed rank test.

Table 6
Preoperative and postoperative visual analog scale scores stratified by treatment group

Variable	Pin Group			Screw Group		
	Pre-VAS	Post-VAS	Difference	Pre-VAS	Post-VAS	Difference
Patients (n)	40	40	40	40	40	40
Mean	75.000	18.750	-56.2500	76.375	21.875	-54.5000
Median	75.000	25.000	-55.0000	75.000	25.000	-55.0000
Standard deviation	5.5470	11.8619	12.39055	4.5273	9.1769	10.36513
Minimum	65.0	0.0	-80.00	65.0	0.0	-80.00
Maximum	80.0	30.0	-40.00	90.0	30.0	-40.00
p Value*	< .001			< .001		

Abbreviations: VAS, visual analog scale; Pre-VAS, preoperative VAS; Post-VAS, postoperative VAS.

* Wilcoxon signed rank test.

Table 7
Preoperative and postoperative American Orthopaedic Foot and Ankle Society scale score stratified by treatment group

Variable	Pin Group			Screw Group		
	Pre-AOFAS	Post-AOFAS	Difference	Pre-AOFAS	Post-AOFAS	Difference
Patients (n)	40	40	40	40	40	40
Mean	30.40	82.125	51.73	31.275	80.00	48.73
Median	30.000	85.000	53.00	30.000	80.000	48.50
Standard deviation	6.7967	3.9039	6.41	6.1602	4.9355	7.372
Minimum	22.0	75.0	41.00	22.0	75.0	33.00
Maximum	41.0	85.0	63.00	42.0	90.0	63.00
p Value*	<.001			<.001		

Abbreviations: AOFAS, American Orthopaedic Foot and Ankle Society (ankle-hindfoot scale); Pre-AOFAS, preoperative AOFAS; Post-AOFAS, postoperative AOFAS.

* Wilcoxon signed rank test.

(10) summarized the advantages of the cannulated screw. These include stable osteotomy compression and fixation, the ability to check the osteotomy alignment and position before final fixation, precision of drilling and screw insertion, and the presence of a low-profile screw head that eliminates potentially prominent hardware (10). We did not observe any implant failure in the screw group.

In contrast, the use of permanent metal implants has been associated with drawbacks such as the potential need for hardware removal and the recently discovered possibility of metal hypersensitivity. The incidence of metal implant removal has ranged from 2% to 15%, according to various investigators, and, in some cases, this can be a complex procedure (6). Therefore, these challenges have led to improvements in the development of bioabsorbable implants. Bioabsorbable pins are advantageous in that they have a lower elasticity modulus, and their mechanical properties are more similar to that of cancellous bone (11). During our follow-up period, we removed the bioabsorbable pins from 3 patients because of irritation.

The field of bioabsorbable implants for fixation in orthopedics is new and rapidly growing (12–14). The bioabsorbable implants that are commercially available primarily consist of 1 or 2 of 3 polymers: polyglycolic acid (PGA), polylactic acid, and polydioxanone. These polymers are part of a group known as α -polyesters or poly(α -hydroxy acids) (15).

Pelto-Vasenius et al (16) reported 21 episodes (22%) of osteolysis among 94 chevron osteotomies that were fixed with PGA pins. They found no association between osteolysis and the development of foreign body reactions, infection, avascular necrosis, loss of hallux valgus correction, or osteoarthritis. They concluded that the osteolytic changes did not require treatment (16). We did not observe any osteolytic changes in our patients. Pihlajamäki et al (17) reported a series of 27 patients with osteotomies treated by internal fixation with absorbable self-reinforced poly-L-lactide pins. No displacement occurred in any patient, and no signs of inflammatory foreign body reaction were noted (17).

Although more expensive than cannulated screws, bioabsorbable pins seem to be adequate for the fixation of small fragments such as the metatarsal heads and the radial head. They have the advantage of not resulting in inflammatory sinus tracts, osteolysis, or loss of fixation (18). Plaass et al (19) compared bioabsorbable magnesium screws and titanium screws using magnetic resonance imaging and found that magnesium screws are comparable to titanium screws and more suitable for radiologic analysis. Successful use of bioabsorbable pins is likely related to the size of the bone and the implant, the inherent stability of the osteotomy, and the type of implant used.

One weakness of our study was that we did not have long-term follow-up data for our patients. Thus, we could not observe all possible complications in each of our groups. We have continued to monitor these patients in the long term.

In the present study, we compared the use of absorbable pins and cannulated screws for fixation of distal chevron osteotomies of the first metatarsal. We found no significant difference between these implants. Both implants led to a decreased HVA, DMAA, and IMA. We believe these implants (bioabsorbable pins and cannulated screws) result in no significant differences in outcomes for fixation of chevron osteotomy. They each have individual advantages and disadvantages. It has been our impression that bioabsorbable pin fixation is a safe and effective method of fixing relatively stable osteotomies in the first metatarsal; however, the costs are greater than those with cannulated screws.

In conclusion, both fixation methods are safe and reliable fixation methods after chevron osteotomy for correction of hallux valgus under appropriate conditions and when performed by an experienced surgeon. The 2 fixation methods each have specific advantages and disadvantages.

References

1. Hecht PJ, Lin TJ. Hallux valgus. *Med Clin North Am* 98:227–232, 2014.
2. Hardy RH, Clapham JC. Observations on hallux valgus; based on a controlled series. *J Bone Joint Surg Br* 33:376–391, 1951.
3. Mann RA, Coughlin MJ. Hallux valgus—etiology, anatomy, treatment and surgical considerations. *Clin Orthop Relat Res* 157:31–41, 1981.
4. Trnka HJ, Hofstaetter S. The chevron osteotomy for correction of hallux valgus. *Interact Surg* 2:52–61, 2007.
5. Johnson JE. Chevron osteotomy for hallux valgus: surgical indications and technique. *Oper Tech Orthop* 2:177–183, 1992.
6. Windhagen H, Radtke K, Weizbauer A, Diekmann J, Noll Y, Kreimeyer U, Schavan R, Stukenborg-Colsman C, Waizy H. Biodegradable magnesium-based screw clinically equivalent to titanium screw in hallux valgus surgery: short term results of the first prospective, randomized, controlled clinical pilot study. *Biomed Eng Online* 12:62, 2013.
7. Morandi A, Ungaro E, Fraccia A, Sansone V. Chevron osteotomy of the first metatarsal stabilized with an absorbable pin: our 5-year experience. *Foot Ankle Int* 34:380–385, 2013.
8. Alcelik I, Alnaib M, Pollock R, Marsh DJ, Tulloch DJ. Bioabsorbable fixation for Mitchell's bunionectomy osteotomy. *J Foot Ankle Surg* 48:9–14, 2009.
9. Andrews BJ, Fallat LM, Kish JP. Screw versus plate fixation for chevron osteotomy: a retrospective study. *J Foot Ankle Surg* 55:81–84, 2016.
10. Toorney EP, McGarvey SR. Fixation of the proximal first metatarsal crescentic osteotomy with the small cannulated screw system. *Foot Ankle* 11:397–399, 1991.
11. Côte-Real N, Vasco Silva J, Esquivel Pereira J, Caramelo J. Chevron osteotomy fixed with biodegradable screws in the treatment of Hallux valgus. *Foot Ankle Surg* 4:87–91, 1998.
12. Pentikainen I, Ojala R, Ohtonen P, Piippo J, Leppilähti J. Preoperative radiological factors correlated to long-term recurrence of hallux valgus following distal Chevron osteotomy. *Foot Ankle Int* 35:1262–1267, 2014.
13. Caminear DS, Pavlovich R Jr, Pietrzak WS. Fixation of the Chevron osteotomy with an absorbable copolymer pin for treatment of hallux valgus deformity. *J Foot Ankle Surg* 44:203–210, 2005.
14. Ford TC, Maurer LM, Myrick KW. Cortical bone pin fixation: a preliminary report on fixation of digital arthrodeses and distal Chevron first metatarsal osteotomies. *J Foot Ankle Surg* 41:23–29, 2002.

15. Raikin SM, Ching AC. Bioabsorbable fixation in foot and ankle. *Foot Ankle Clin* 10:667–684, 2005.
16. Peltö-Vasenius K, Hirvensalo E, Vasenius J, Rokkanen P. Osteolytic changes after polyglycolide pin fixation in Chevron osteotomy. *Foot Ankle Int* 18:21–25, 1997.
17. Pihlajamäki H, Böstman O, Hirvensalo E, Törmälä P, Rokkanen P. Absorbable pins of self-reinforced poly-L-lactic acid for fixation of fractures and osteotomies. *J Bone Joint Surg Br* 74:853–857, 1992.
18. Winemaker MJ, Amendola A. Comparison of bioabsorbable pins and Kirschner wires in the fixation of chevron osteotomies for hallux valgus. *Foot Ankle Int* 17:623–628, 1996.
19. Plaass C, von Falck C, Ettinger S, Sonnow L, Calderone F, Weizbauer A, et al. Bioabsorbable magnesium versus standard titanium compression screws for fixation of distal metatarsal osteotomies—3 year results of a randomized clinical trial. *J Orthop Sci* 30300, 2017.