



## Acute effects of exercise on choroidal thickness and ocular pulse amplitude

Exercise, choroidal thickness and ocular pulse amplitude

Mehmet Serdar Dervişoğulları<sup>1</sup>, Yüksel Totan<sup>2</sup>, Ali Ender Kulak<sup>3</sup>, Emre Güler<sup>4</sup>

<sup>1</sup>Ophthalmology Department, Başkent University, Adana,

<sup>2</sup>Maya Göz Hastanesi, Ankara,

<sup>3</sup>Kırşehir Ahi Evran Eğitim Araştırma Hastanesi, Kırşehir,

<sup>4</sup>Medipol University, Istanbul, Turkey

### Abstract

**Aim:** To explore ocular changes in healthy people after exercise. **Material and Method:** Twenty participants underwent exercise for 15 minutes on a treadmill. Measurements of choroidal thickness, intraocular pressure (IOP), ocular pulse amplitude (OPA), and blood pressure were taken before and after exercise. Enhanced Depth, Imaging optical coherence tomography (EDI-OCT) was used to measure choroidal thickness at the fovea and at the areas 1500µm nasal and 1500µm temporal to the fovea; IOP and OPA were measured by the dynamic contour tonometer (DCT; Swiss Micro technology AG, Port, Switzerland). Blood pressure was measured concurrently with the acquisition of the scans. **Results:** Twenty participants (20 eyes) with a mean age of 22.65±0.98 years were measured. There was a significant increase in systolic and diastolic pressure after exercise ( $p<0.05$ ). There was a significant decrease in IOP and OPA after exercise ( $p<0.05$ ). There was no significant difference in the subfoveal, nasal or temporal choroidal thickness measurements after exercise ( $p>0.05$ ). **Discussion:** In our study, there was no significant change in the thickness of the choroid after exercise. IOP and OPA significantly decreased, and systolic and diastolic blood pressure significantly increased, after exercise. This indicates an adaptation of vascular resistance due to vasoconstriction. The IOP and OPA decreases do not seem to be related with the changes in choroid thickness.

### Keywords

Exercise; Choroid; Ocular Pulse Amplitude

DOI: 10.4328/JCAM.5844 Received: 28.03.2018 Accepted: 27.04.2018 Published Online: 28.04.2018 Printed: 01.01.2019 J Clin Anal Med 2019;10(1): 62-6  
Corresponding Author: Mehmet Serdar Dervişoğulları, Ophthalmology Department, Başkent University Medical School, Adana Dr. Turgut Noyan Clinic and Research Center, Yüreğir, Adana, Turkey. T.: +90 3223272727 F.: +90 3223271274 GSM: +905327720616 E-Mail: serdarderv@hotmail.com  
ORCID ID: 0000-0003-2006-2906

## Introduction

Although the mechanism has not been fully defined, exercise may cause a reduction in IOP [1]. Physical activity can also make some changes in other ocular parameters like ocular blood flow [2], tonic accommodation [3], pupil size [4], anterior chamber angle [5], and retinal activity [6].

The choroid is a highly vascularized tissue. It provides oxygen and nourishment to the outer retinal layers and regulates heat at the foveal region. Nearly 90 percent of the ophthalmic artery blood flow is received by the choroid [7]. It is shown that the anatomy and physiologic functions of choroid is quite important in ocular diseases like glaucoma [8]. Several studies have reported noninvasive in vivo measurements of the choroid thickness with optical coherence tomography (OCT) in normal subjects and choroid or retinal diseases [9].

The difference between the systolic and diastolic intraocular pressure (IOP) is called the ocular pulse amplitude (OPA) and it is caused by cardiovascular pulsations and ocular blood flow. The OPA is an index of choroid perfusion and there are many different methods for measuring the OPA and choroid perfusion [10]. The dynamic contour tonometer (DCT; Swiss Micro technology AG, Port, Switzerland) is a relatively new technology that allows the measurement of both intraocular pressure (IOP) and OPA.

To the best of our knowledge, there are no previous studies in the literature evaluating choroid thickness and OPA together after physical activity. In our study, we aimed to show the relation between exercise, choroid thickness, and OPA as this may help to understand the mechanism of decrease in IOP after physical activity. The choroid has no or only minimal autoregulation. Thus, changes in systemic blood flow induce changes in the choroidal perfusion and thickness. We aimed to visualize and quantify the choroidal thickness with OCT and show perfusion status with OPA measurements.

## Material and Method

This prospective observational study was carried out with the fifth class students of the .. University Medical Faculty from May 15 to December 15, 2014. The study was performed in adherence with the tenets of the Declaration of Helsinki and was approved by the local ethics committee. Informed consent was obtained from all of the study participants. Twenty healthy individuals (12 men and 8 women) with a mean age of  $22.65 \pm 0.98$  years (ages 21 to 24 years) were included in the study. One eye from each participant was randomly selected and the tests were performed at the same time of day (10:00–12:00) to overcome the effect of diurnal variations. History was taken to ensure that all patients were free of ocular or systemic diseases and were not taking any systemic medications known to affect visual functions. Cigarette smokers were not included in the study [11]. As water loading may effect axial length and IOP, participants were asked not to ingest food or liquid for 30 minutes before exercise [12]. The subjects were also asked not to use caffeine and alcohol for 6 hours before the study [13]. The participants were also asked not to exercise 1 hour before the study. Subjects had rest in a sitting position in a quiet room maintained at 20–25°C prior to the exercise. Each subject was evaluated with an ophthalmologic examina-

tion before the study to exclude patients with undiagnosed ocular disease. Visual acuity, refraction, and IOP were measured in all subjects followed by an anterior segment slit lamp exam and a dilated fundoscopic exam. The axial length was measured with Nidek AL-Scan (Nidek Co. Ltd. Gamagori, Japan). All participants underwent blood pressure (BP), IOP, OPA and choroidal thickness measurements before and 5 minutes after exercise.

BP measurements were performed using an automated BP cuff. Resting BP was taken before exercise and postexercise BP was taken 5 minutes after exercise. Using the IOP and median BP, ocular perfusion pressure (OPP) was calculated by the equation ( $OPP = 2/3 \text{ median BP} - \text{IOP}$ ). All participants exercised for 15 minutes on an electric treadmill and their heart rates were monitored throughout the exercise. The exercise intensity was the heart rate above 70% of their maximum heart rate, which was defined as  $208 - (0.7 * \text{age})$ . Electric treadmill speed ranged from 7–8 km/h for men and 6.5 – 7.5 km/h for women.

The IOP and the OPA were measured with DCT by an experienced operator (AEK) after administering topical anesthesia before and 5 minutes after exercise. Each IOP measurement was performed three times.

All OCT scans were performed by the same experienced technician who was blind to the study protocol. The choroidal thickness was measured by the Cirrus high definition optical coherence tomography (HD-OCT, Cirrus Version 6.0; Carl Zeiss Meditec, Dublin, CA). Each participant's head was fixed on the sustainer with the eye focusing on the international fixation target without blinking or moving the eye while six radial retinal scans were performed. The scans were only accepted if they were completed, well centered, had signal strength of at least 6, and had no motion or blinking artifacts. After each examination, two independent masked graders (MSD, YT) evaluated the best image that s projected on a computer screen. The image was accepted and used for analysis when two graders determined that both inner and outer borders of the choroid were clearly distinguishable. The choroidal image was obtained according to the previous method [11]. The protocol of HD 5 Line Raster centered foveally and spaced at 0.25mm was performed. This protocol consisted of 6mm parallel lines with 1024 A-scans/B-scans and averaging 4 B-scans per image. As the inversion of the image by using the Cirrus software results in a pixelated and low resolution image, the images were not inverted to bring the choroid into closer proximity to the zero delay line. The image of the thinnest point of the macula was chosen to prevent the effect of positioning on the measured thickness of the fovea. The image size was doubled, foveally centered and the subfoveal choroidal thickness was measured manually from the outer portion of the hyper-reflective line corresponding to the retina pigment epithelium to the inner surface of sclera by the linear measuring tool of Cirrus software. The thickness of the choroid at the areas 1500µm nasal and 1500µm temporal to the fovea was also examined (Figure1). Two independent raters (MSD, YT) measured images without information about the eye or other observer, as previously described [11], and the average of the two measurements was taken; the differences between the readings of the masked physicians were found to be within 10% of the mean. In a previous study, subfoveal choroidal thickness measurements by EDI-OCT showed a high

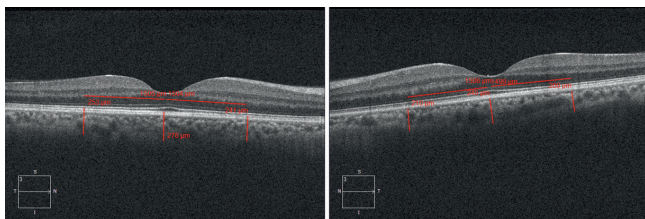


Figure 1. Choroid thickness in a participant using enhanced depth imaging optical coherence tomography.

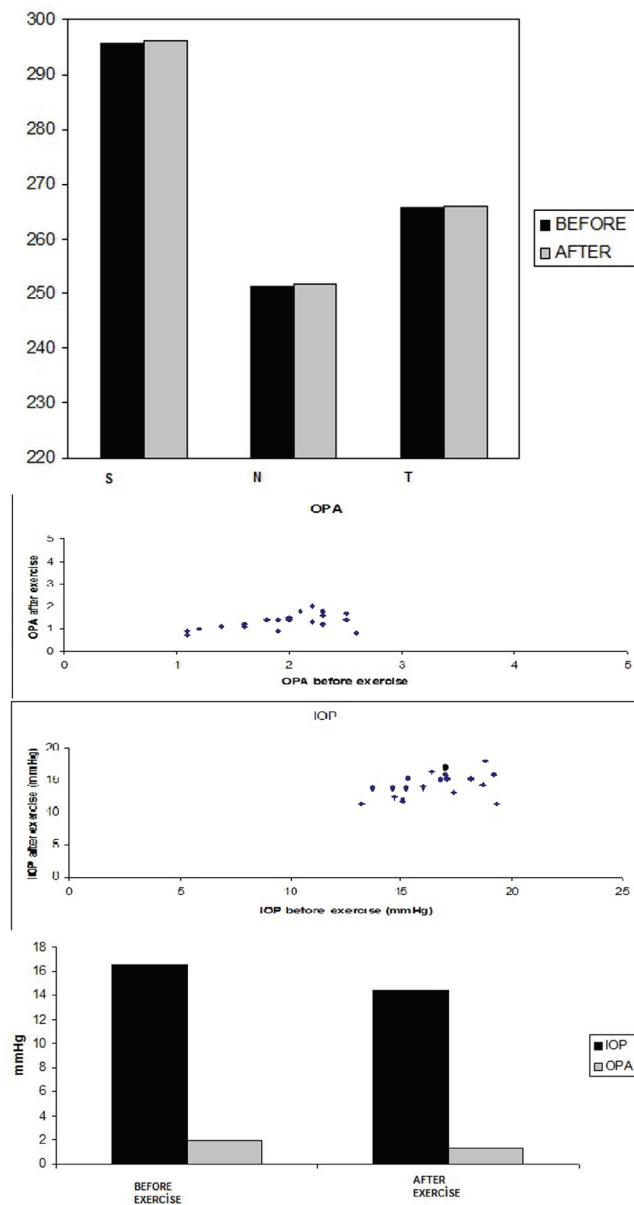


Figure 2. Graph displaying the choroidal thickness at the different location: S (subfoveal), N (1500 μm nasal), and T (1500 μm temporal). No significant difference was observed before and after exercise, despite significant change in diastolic and systolic blood pressure, IOP, and OPA as outlined in Table 1 and 2 (A). IOP and OPA scatterplot before and after exercise (B). IOP and OPA before and after exercise. A decrease was observed before and after exercise ( $p < 0.05$ ) (C).

intra-observer reproducibility and inter-observer reproducibility [12]. Statistical analyses were performed using SPSS V.20.0 (SPSS Inc., IBM Corp, Chicago, Illinois, USA). The normal distribution of the data was checked using the Kolmogorov-Smirnov test. Statistical analyses were performed using a paired t test. A 95% confidence interval and a 5% level of significance were adopted; therefore, the results with a  $p$  value  $\leq 0.05$  were considered significant.

**Results**

Twenty healthy individuals (12 men and 8 women) with a mean age of  $22.65 \pm 0.98$  years (ages 21 to 24 years) with no history of any ocular disease or surgery were scanned. The spherical equivalent was  $-0.8 \pm 0.79$  D (min  $-2.25$  max 0) and the axial length was  $23,78 \pm 0.63$  mm (min 22,8 max 25). Figures 2a to 2c, as well as Tables 1 and 2 outline the results. There was a significant increase in systolic and diastolic pressure, mean arterial pressure (MAP), and OPP after exercise ( $p < 0.05$ ), as depicted in Table 1. Choroidal thickness measurements at all locations before and after exercise are shown in Table 2. There was no significant difference in choroidal thickness at all locations before and after exercise ( $p > 0.05$ ) (Figure 2a). The nasal, temporal, and subfoveal choroid thicknesses were  $251.35 \pm 35.31, 265.65 \pm 43.9, 295.68 \pm 38.09$  μm before exercise and  $251.90 \pm 35.62, 265.90 \pm 43.49, 296.15 \pm 38.33$  after exercise, respectively. There was a significant decrease in IOP and OPA after exercise ( $p < 0.05$ ) (Table 2, Figure 2b and 2c).

Table 1. The effect of exercise on blood pressure

	MEAN±SD BEFORE EXERCISE (mmHg)	MEAN±SD AFTER EXERCISE (mmHg)	P VALUE (paired t-test)
DBP	76.50±5,40	77.50±5,50	$P < 0.05$
SBP	116.25±6,25	145.50±6,86	$P < 0.05$
MAP	96.37±10,93	111.15±14,97	$P < 0.05$
OPP	47.82±6,20	58.16±8,13	$P < 0.05$

SBP: systolic blood pressure, DBP: diastolic blood pressure, MAP: mean arterial pressure, OPP: ocular perfusion pressure.

Table 2. The effects of exercise on intraocular pressure, ocular pulse amplitude and choroidal thickness.

PARAMETER	MEAN±SD BEFORE EXERCISE (N=25)	MEAN±SD AFTER EXERCISE (N=25)	P VALUE (paired t-test)
IOP (mmHg)	16,53±1,79	14,44±1,90	$P < 0,05$
OPA	1,93±0,46	1,31±0,35	$P < 0,05$
CTN (μm)	251,35±35,31	251,90±35,62	$P > 0,05$
CTT (μm)	265,65±43,90	265,90±43,49	$P > 0,05$
CTS (μm)	295,65±39,09	296,15±38,33	$P > 0,05$

SD: standard deviation, IOP: intraocular pressure, OPA: ocular pulse amplitude CTN: choroid thickness 1500 μm nasal to the fovea CTT: choroid thickness 1500 μm temporal to the fovea CTS: subfoveal choroid thickness

**Discussion**

To the best of our knowledge, this is the first investigation evaluating choroid thickness and OPA together in young healthy participants after dynamic exercise. Exercise, whether isometric or dynamic, can result in acute decreases in IOP [14]. Our data is consistent with the previous studies which stated that dynamic exercise can lower IOP. In our study, OPA also seemed to decrease after dynamic exercise.

The choroid is a highly vascularized tissue and it is directly influenced by intraocular and perfusion pressures. It is shown that OCT is superior to histology in term of accuracy of measuring the choroid thickness [15]. Measurements of the OPA and the choroid thickness together may be important as the relationship between choroid thickness and choroid perfusion is still debated. The OPA is caused by cardiovascular pulsations and ocular blood flow and is an index of choroid perfusion [16].

There are many different methods for measuring the OPA and the choroid perfusion including DCT [17]. It was suggested that choroid blood flow may not be correlated with choroid thickness in an experimental study in which measurements with laser Doppler flowmetry showed that increased choroid blood flow preceded the increase in choroid thickness during recovery from deprivation myopia [18]. In contrast, it has been reported that sildenafil citrate increases the choroid thickness due to a vasodilator effect on circulation [19]. This relationship was further investigated in a study that used swept-scan high-frequency digital ultrasound to measure the ocular blood flow and the study suggested that increased choroid circulation may be associated with increased choroid thickness [20]. In another recent study, subfoveal choroid thickness, measured by enhanced depth imaging OCT (EDI-OCT), was not found to be significantly correlated with choroid blood flow in young healthy eyes [21]. The authors suggested that further prospective studies are required to determine the changes in choroidal thickness during stimulation that can cause choroid circulation changes. There are many factors that may affect the choroid [22] but our data indicate that there was not a change in the choroid thickness after dynamic exercise despite a decrease in the IOP and the OPA.

Unchanged ocular blood flow during isometric exercise was reported with different techniques [23, 24]. Riva et al. [23] reported an increase in choroidal vascular resistance that limited increases in choroidal blood flow when OPP increased up to 67%, but this regulatory process failed when OPP increased further. Movaffaghy et al. [24] reported no significant variation in mean velocity, volume, or flow of red blood cells in the range of OPP from 56 to 80mmHg, with increased vascular resistance. Okuno et al. [13] reported that dynamic exercise produces increased tissue blood flow in the retina in the early period but blood flow increases more persistently in the choroid-retina and this difference in control of blood flow in these two regions may be related to stronger autoregulatory mechanism of blood flow in the retina. Based on these reports, it can be said that different types of exercise (isometric vs dynamic) may involve differential regulatory mechanisms. In our study, choroid thickness was not significantly changed by exercise in young healthy participants. This data is in agreement with that from Alwassia et al. [22] and Hong et al. [12] Alwassia et al. studied patients with a mean age of  $60.66 \pm 10.4$  years who underwent cardiac exercise stress testing in the cardiovascular stress testing unit. Exercise was stopped as soon as patients reached a given heart rate. In our exercise regimen, healthy individuals ran for 15 minutes on treadmill at 6.5–8 km/h for up to 2 km and continued running even after reaching 70% of their maximum heart rate, similar to the study of Hong et al. [17] Sayin et al. measured CT 5 min and 15 min after dynamic exercise and reported that CT increased 5 min following exercise compared to the baseline but did not differ significantly at 15 min. As a matter of fact, in our study it took us more than 5 minutes to take all measurements but their 15 min results are similar to our study [25].

Our investigation demonstrated no significant change in the thickness of the choroid after exercise, despite significant changes in SBP, DBP, MAP, and OPP. This indicates an adaptation of vascular resistance due to vasoconstriction. The mecha-

nism of this regulation is probably mediated by autoregulation or by the intricate neural innervation of the choroidal vessels. The myogenic theory assumes that changes in transmural pressure are responsible for smooth muscle constriction in response to an OPP increase, in an effort to keep vessel wall tension constant. Neural regulatory mechanisms may play a role as sympathetic and parasympathetic nerves have been previously identified in the choroid [26].

Our study had some limitations. First of all, the number of cases was limited. Another limitation was that the choroid thickness measurements had to be performed manually, which introduces a potential cause of inter-observer bias. To overcome this limitation, two different observers performed measurements at three different points, a process used in previous studies [11], but the time needed to measure the choroid thickness manually may lead to observer fatigue and may increase the possibility of false measurements. Although this is still the most commonly used method for determining choroid thickness, there is still a need to minimize the bias associated with this measurement method. To eliminate factors that may have an effect on choroid circulation, patients on systemic and topical medications, patients with a known systemic or ocular disease, smokers, and pregnant subjects were excluded.

In conclusion, despite these limitations we found that the IOP and OPA significantly decreased and SBP, DBP, MAP, and OPP significantly increased, but choroid thickness did not change after dynamic exercise in a population of young healthy participants. These findings may be useful in future studies investigating the relation between exercise, choroid perfusion, and OPA and may be a step toward understanding the pathogenesis of glaucoma. Our results may change our view regarding the relationship of the choroid and IOP as previous studies have suggested a link between these two variables.

#### **Scientific Responsibility Statement**

*The authors declare that they are responsible for the article's scientific content including study design, data collection, analysis and interpretation, writing, some of the main line, or all of the preparation and scientific review of the contents and approval of the final version of the article.*

#### **Animal and human rights statement**

*All procedures performed in this study were in accordance with the ethical standards of the institutional and/or national research committee and with the 1964 Helsinki declaration and its later amendments or comparable ethical standards. No animal or human studies were carried out by the authors for this article.*

#### **Funding: None**

#### **Conflict of interest**

*None of the authors received any type of financial support that could be considered potential conflict of interest regarding the manuscript or its submission.*

## References

1. Hamilton-Maxwell KE, Feeney L. Walking for a short distance at a brisk pace reduces intraocular pressure by a clinically significant amount. *J Glaucoma*. 2012;21(6):421–5.
2. Polska E, Simader C, Weigert G, Doelemeyer A, Kolodjaschna J. Regulation of choroidal blood flow during combined changes in intraocular pressure and arterial blood pressure. *Invest Ophthalmol Vis Sci*. 2007;48: 3768–74.
3. Ritter AD, Huhn-Beck H. Dark focus of accommodation and nervous system activity. *Optom Vis Sci*. 1993;70:532–4.
4. Hayashi N, Someya N, Fukuba Y. Effect of intensity of dynamic exercise on pupil diameter in humans. *J Physiol Anthropol*. 2010; 29(3): 119–22.
5. Haargaard B, Jensen PK, Kessing SV, Nissen OI. Exercise and iris concavity in healthy eyes. *Acta Ophthalmol Scand*. 2001;79:277–82.
6. Kergoat H, Forcier P. Correlation of an exercise-induced increase in systemic circulation with neural retinal function in humans. *Doc Ophthalmol*. 1996;92:145–57.
7. Hayreh SS. Segmental nature of the choroidal vasculature. *Br J Ophthalmol*. 1975;59:631–48.
8. Kubota T, Jonas JB, Naumann GO. Decreased choroidal thickness in eyes with secondary angle-closure glaucoma: an aetiological factor for deep retinal changes in glaucoma? *Br J Ophthalmol*. 1993;77:430–2.
9. Branchini L, Regatieri CV, Flores-Moreno I. Reproducibility of choroidal thickness measurements across three spectral domain optical coherence tomography systems. *Ophthalmology*. 2012;119:119–23.
10. Schmetterer L, Dallinger S, Findl O, . Noninvasive investigations of the normal ocular circulation in humans. *Invest Ophthalmol Vis Sci*. 1998;39:1210–20.
11. Dervişoğulları MS, Totan Y, Tenlik A, Yuce A. Effects of cigarette smoking on choroidal and retinal thickness and ocular pulse amplitude. *Cutan Ocul Toxicol*. 2014;8:1–7.
12. Hong J, Zhang H, Kuo DS, Wang H, Huo Y, Yang D, et al. The short-term effects of exercise on intraocular pressure, choroidal thickness and axial length. *PLoS One*. 2014;9(8):e104294.
13. Okuno T, Sugiyama T, Kohyama M, Oku H, Ikeda T. Ocular blood flow changes after dynamic exercise in humans. *Eye (Lond)*. 2006;20(7):796–800.
14. Qureshi IA. Effects of mild, moderate and severe exercise on intraocular pressure of sedentary subjects. *Ann Hum Biol*. 1995;22: 545–53.
15. Maul EA, Friedman DS, Chang DS, Boland MV, Ramulu PY, Jampel HD et al. Choroidal thickness measured by spectral domain optical coherence tomography: factors affecting thickness in glaucoma patients. *Ophthalmology*. 2011;118(8):1571–79.
16. Walker RE, Langham ME. Pneumatic applanation tonometer studies. Analysis of pulsatile response. *Exp Eye Res*. 1975;20:245–53.
17. Schmetterer L, Dallinger S, Findl O, Strenn K, Graser U, Eichler HG et al. Non-invasive investigations of the normal ocular circulation in humans. *Invest Ophthalmol Vis Sci*. 1998;39:1210–20.
18. Fitzgerald ME, Wildsoet CF, Reiner A. Temporal relationship of choroidal blood flow and thickness changes during recovery from form deprivation myopia in chicks. *Exp Eye Res*. 2002;74(5):561–70.
19. Vance SK, Imamura Y, Freund KB. The effects of sildenafil citrate on choroidal thickness as determined by enhanced depth imaging optical coherence tomography. *Retina* 2011;31(2): 332–5.
20. Kim DY, Silverman RH, Chan RV. Measurement of choroidal perfusion and thickness following systemic sildenafil (Viagra). *Acta Ophthalmol*. 2013;91(2):183–8.
21. Sogawa K, Nagaoka T, Takahashi A. Relationship between choroidal thickness and choroidal circulation in healthy young subjects. *Am J Ophthalmol*. 2012;153(6):1129–32.
22. Alwassia AA, Adhi M, Zhang JY. Exercise-induced acute changes in systolic blood pressure do not alter choroidal thickness as measured by a portable spectral-domain optical coherence tomography device. *Retina*. 2013; 33(1):160–5.
23. Riva CE, Titzel P, Hero M, Movaffaghy A, Petrig BL. Choroidal blood flow during isometric exercises. *Invest Ophthalmol Vis Sci*. 1997; 38: 2338–43.
24. Movaffaghy A, Chamot SR, Petrig BL, Riva CE. Blood flow in the human optic nerve head during isometric exercise. *Exp Eye Res*. 1998;67:561–68.
25. Sayin N, Kara N, Pekel G et al. Choroidal thickness changes after dynamic exercise as measured by spectral-domain optical coherence tomography. *Indian J Ophthalmol*. 2015;63(5):445–50.
26. Lutjen-Drecoll E. Choroidal innervation in primate eyes. *Exp Eye Res*. 2006;82: 357–61.

## How to cite this article:

Dervişoğulları MS, Totan Y, Kulak AE, Güler E. Acute effects of exercise on choroidal thickness and ocular pulse amplitude. *J Clin Anal Med* 2019;10(1): 62–6.