



Case report

Endotracheal ectopic parathyroid adenoma mimicking asthma



M. Akif Özgül^a, Ekrem Cengiz Seyhan^{b,*}, Güler Özgül^c, Erdoğan Çetinkaya^a,
Songul Büyükkale^a, Nurcan Ünver^a, Tansel Çakır^d, Adnan Sayar^a

^a Yedikule Teaching Hospital for Chest Diseases and Thoracic Surgery, Istanbul, Turkey

^b Medipol University, Medical Faculty, Chest Diseases, Istanbul, Turkey

^c Bağcılar Teaching Hospital for Chest Diseases, Istanbul, Turkey

^d Medipol University, Medical Faculty, Nuclear Medicine, Istanbul, Turkey

A B S T R A C T

Keywords:

Ectopic parathyroid adenoma
Endobronchial treatment
Trachea benign tumors

Primary benign tumors of the trachea are uncommon. These tumors may cause tracheal occlusion and lead to a misdiagnosis of asthma. Ectopic parathyroid adenoma (EPA) can be seen anywhere between the mandibular angle and the mediastinum. The distal part of the trachea is a rare location for EPA, and EPA obstructing the endotracheal lumen has not been reported in the literature. We herein describe a 52-year-old female with a several-year history of asthma treatment who presented with progressive dyspnea. Computed tomography revealed a mass that was obstructing the tracheal lumen. Total mass excision was performed via endobronchial treatment, and pathologic examination revealed EPA.

© 2014 The Authors. Published by Elsevier Ltd. This is an open access article under the CC BY-NC-SA license (<http://creativecommons.org/licenses/by-nc-sa/3.0/>).

Introduction

Primary benign tumors of the trachea and main bronchi are uncommon. Such tumors often grow undetected and obstruct a major portion of the tracheobronchial lumen before symptoms such as dyspnea, wheezing, and stridor develops. They are often misdiagnosed as asthma and can remain undetected for months or years [1]. The parathyroid (PT) glands generally lie close to the posterior surface of the thyroid lobes, and there are usually four PT glands in humans [2]. Ectopic PT glands can be seen from the front of the bifurcation of the carotid artery to the pericardium because of the long path of migration of the thymus during the embryological period [3]. In this case report, we present a case involving an ectopic PT adenoma (EPA) obstructing the tracheal lumen and located in the distal part of the trachea. To date, such a case has never been reported in the literature.

Case report

A 52-year-old female patient with a 5-year history of asthma treatment was hospitalized after being referred to our center with a

prediagnosis of a tracheal mass. Thoracic computed tomography (CT) had been performed because of progressive dyspnea; the mass was found to be almost completely obstructing the distal part of the trachea. The patient was a nonsmoker and had no significant medical history with the exception of two myomectomies.

In the pulmonary auscultation, the expiration was found to be long and there were widespread bilaterally rhonchi. There were no pathological findings in other systems' examinations. Biochemical blood analysis and complete blood counts were normal. Patient's epicentral thorax CT showed a polypoid lesion with sizes of 22 × 19 mm in the trachea with a posterior soft tissue extension (Fig. 1).

Flexible bronchoscopy was performed with a prediagnosis of a tracheal mass. A vegetating polypoid lesion that was constricting 90% of the distal part of the tracheal lumen was identified (Fig. 2). The procedure was terminated by planning endobronchial treatment with rigid bronchoscopy under general anesthesia because of the inability to progress further to the distal part of the lesion, the need for airway security, and the lesion's tendency to hemorrhage. Rigid bronchoscopy revealed a pink mass with hypervascular nodular formation on its surface obliterating 95% of the distal tracheal lumen. The mass was treated by argon plasma coagulation (APC) and neodymium: yttrium–aluminum garnet (Nd:YAG) laser photoresection (Video 1). Debris was removed by a biopsy forceps and aspiration catheter. The tracheal lumen was fully opened (Fig. 3). The biopsy report identified the lesion as an abnormally located PT adenoma (Fig. 4). After this report of EPA, blood analysis

* Corresponding author. Ressay Salihermez sok, Inta A blk, D.18 Göztepe, İstanbul, Turkey. Tel.: +90 212 6641700, +90 216 5652227 (home); fax: +90 212 5472233.

E-mail address: drekremcs@yahoo.com (E.C. Seyhan).

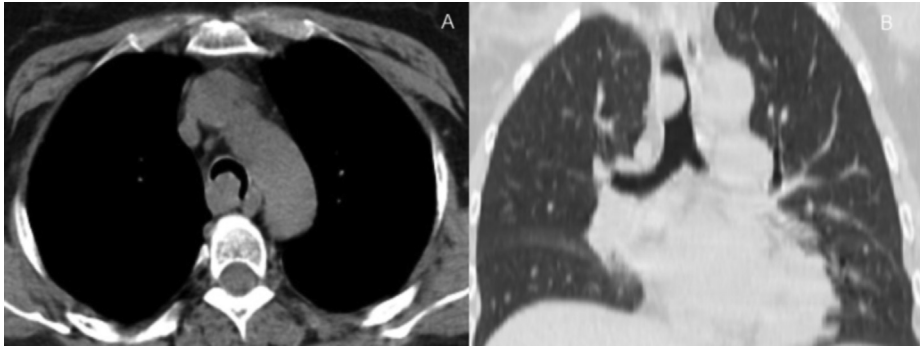


Fig. 1. Pulmonary CT scan images reformatted in oblique axial (a) and coronal (b) planes showed a polypoid lesion with sizes of 22 × 19 mm in the trachea with a posterior soft tissue extension.

to diagnose hyperparathyroidism was performed. Parathormone (PTH): 48.3 pg/mL (normal range: 15–65 pg/mL), Calcium (Ca): 9.95 (normal range: 8–10.6 mg/dl), and Calcium in 24 h urine: 253 mg/day (100–300 mg/day) were found. According to these results, EPA was determined as nonfunctional.

Supplementary video related to this article can be found at <http://dx.doi.org/10.1016/j.rmcr.2014.07.006>.

PT scintigraphy was performed with technetium 99m methoxyisobutylisocyanide (Tc-99m MIBI). On the early image at 15 min, a focal area of increased uptake of Tc-99m MIBI was observed in the right posterolateral wall of the trachea. The focal uptake continued on the delayed images acquired after the second hour of injection. No evidence of adenomas in other fields was found (Fig. 5). Single-photon emission CT (SPECT) was performed to determine the exact location of the lesion. The lesion was located in the right posterolateral wall of the trachea (Fig. 5). Surgery was performed to remove the remaining tissue. Positron emission tomography/CT with 18F-fluorodeoxyglucose (¹⁸F-FDG PET/CT) was performed preoperatively to determine the metabolic activity of the suspicious lesion located in the trachea and to identify possible metastasis. The lesion was located in the right posterolateral wall of trachea; its maximum standardized uptake value (SUVmax) was 10.6, and it

measured 17 × 12 × 19 mm. There were no other abnormal findings on PET/CT (Fig. 5).

Right posterolateral thoracotomy was performed, and the right hemithorax was explored. A 2-cm tumor was found in the distal part of the trachea, extending from the membranous surface to the posterior mediastinum, starting 2 cm above the carina and extending 2 cm cranially. The trachea was dissected from the surrounding tissues at this site. After dissection, the trachea was circularly incised 1 cm proximally and 1 cm distally; a total of 4 cm of tracheal tissue was resected. No postoperative complications occurred. The patient was discharged on the fifth postoperative day.

Histopathological examination showed that the mass contained pathological PT tissue. The tissue was not immunoreactive to pancytokeratin, chromogranin, or CD 56 antibodies. The Ki-67 proliferation index was 2%. In light of these findings, the mass was determined to be adenomatous ectopic PT tissue (Fig. 6).

Discussion

EPAs are rare and usually associated with the structures developing from the third and fourth pharyngeal clefts. They can be seen in various locations due to the differences in embryological development [4]. The most commonly seen ectopic location is the

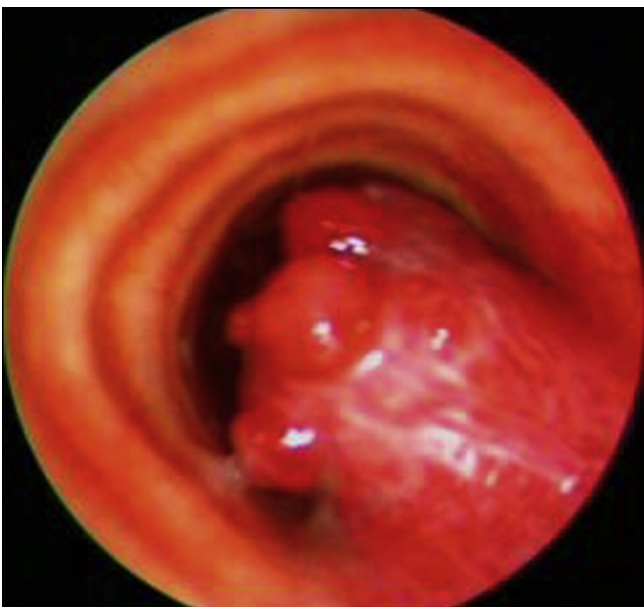


Fig. 2. Fiberoptic bronchoscopy revealed a vegetating polypoid lesion which was constricting 80% of the distal part of the tracheal lumen.

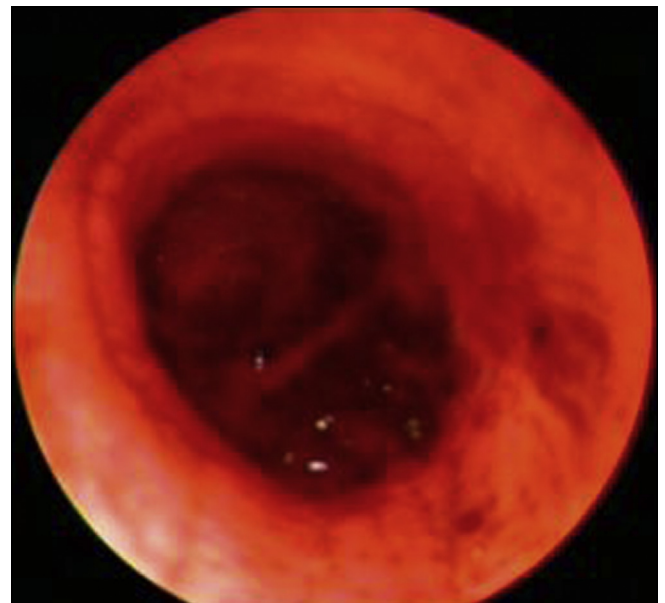


Fig. 3. View of tracheal lumen after the removal of the mass with rigid bronchoscopy.

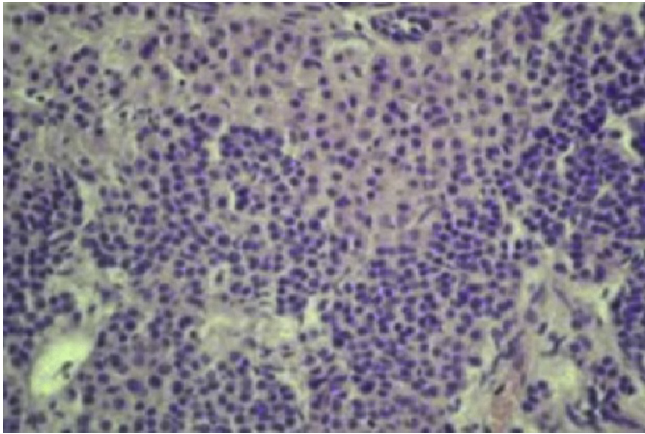


Fig. 4. Parathyroid tissue in the mass which was removed endobronchially, showing a combination of Chief and oxyphil cells (H&E stain 400X).

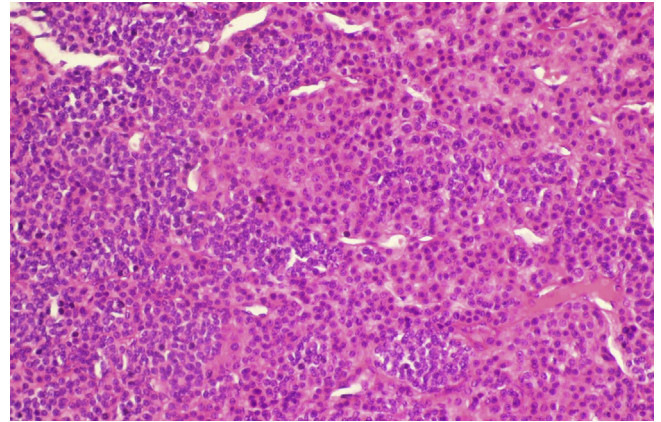


Fig. 6. Parathyroid tissue showing a combination of Chief and oxyphil cells after resection (H&E stain 40 × 10).

tracheoesophageal groove (27–33% of cases) [3]. Other ectopic sites include the inner aspect of the thyroid, neighboring region of the para-aortic arch, anterior aspect of the sternocleidomastoideus muscle, neighboring region of the hypoglossal nerve, parasophageal region, anterior mediastinum, aortopulmonary window, and pericardium [5]. In our case, the EPA was located

posterolateral to the trachea and passed through the intratracheal area, resulting in an almost complete constriction. To the best of our knowledge, an ectopic localization consistent with that in the present case has not been reported in the literature to date.

A bronchial asthma-like syndrome may also be seen in patients with upper airway obstructions of both extrathoracic (e.g., vocal

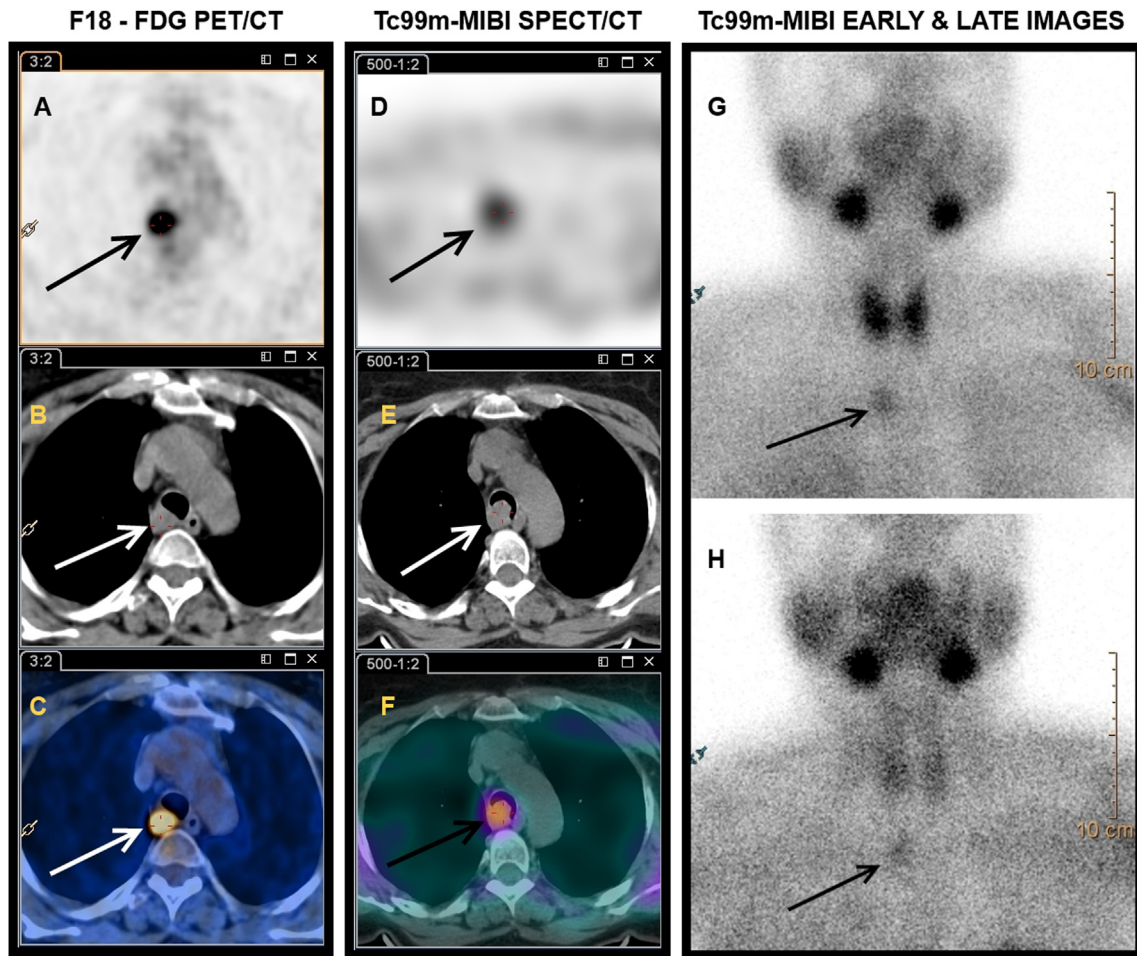


Fig. 5. On the early images at 15 min (G) a focal increased uptake of ^{99m}Tc-MIBI was observed at mediastinum. Focal uptake continued at delayed images acquired after the second hour of injection (H). SPECT/CT was performed in order to determine the exact localization of the lesion. Lesion was located in the right posterolateral wall of trachea similar as PET/CT (D: SPECT images, E: CT images, F: SPECT/CT fused images).

cord dysfunction syndrome, epiglottitis) and intrathoracic causes (e.g., tracheal stenosis, endobronchial tumors). Benign endobronchial tumors are characterized by a slow growth rate and generally present with a dry cough and wheezing. Intermittent, low-grade respiratory symptoms can often be misdiagnosed as asthma [6]. Thus, diagnosis of conditions other than bronchial asthma should be considered when the initial evaluation suggests their presence or when the patient does not respond to conventional asthma medications [7]. Our patient was being followed with an asthma diagnosis for several years. Because of her dyspnea and asthma diagnosis secondary to constriction of the tracheal lumen by ectopic PT tissue, the patient had a treatment history of inhaled steroids and betamimetic agents.

Various localization and screening techniques for PT adenoma are used for misdiagnosed or missed PT adenomas. These techniques are performed routinely because of the development of nuclear techniques that are less invasive. Ultrasound, Tc-99m MIBI scintigraphy, SPECT, and MRI are the most commonly used noninvasive methods [8]. Tc-99m MIBI PT scintigraphy is used widely for the localization of PT pathologies, and the sensitivity and specificity of diagnosis of PT adenomas are 91.0% and 98.8%, respectively [9]. The Tc-99m sestamibi remains in the PT gland but is immediately cleared from the thyroid gland, allowing for localization of the PT glands in the neck. If SPECT is added to Tc-99m MIBI scintigraphy, the probability of finding a PT adenoma increases. The positive predictive value of this technique was 95% in one study [10]. In our patient, who had a prediagnosis of a tracheal mass, the mass was urgently removed by rigid bronchoscopy for both diagnosis and treatment. After a pathological diagnosis of EPA, Tc-99m MIBI scintigraphy and SPECT/CT were performed. MIBI uptake was seen in the right posterolateral distal part of the trachea, and this tissue was considered to be an EPA. No evidence of an adenoma was found in other sites.

Studies on the localization of PT adenoma with PET/CT have been performed [11]. The role of PET/CT with 18F-FDG in cancer is well documented in the literature. Evangelista et al. stated that PET/CT is a highly sensitive tool in all phases of PT cancer [12]. With PET/CT, both correct localization of the PT adenoma and determination of the presence of multiglandular disease are possible [13]. In our case, preoperative 18F-FDG PET/CT was performed to identify any malignancy. A 1.6- × 1.8-cm lesion in the right posterolateral distal trachea, constricting lumen and demonstrating soft tissue density (SUVmax, 6.9) was found. This lesion was present at the same site shown with SPECT and MIBI scintigraphy.

Endobronchial bronchoscopic resection can be both diagnostic and curative because of the benign nature of tracheal tumors. Many endobronchial methods using rigid or flexible bronchoscopy have been developed for the treatment of these tumors. Nd: YAG laser photoresection, cryotherapy, electrocautery, and APC are used to provide airway openness [14,15]. In our case, because of the near-complete obstruction by the tracheal mass, we primarily used Nd: YAG laser photoresection followed by APC to clear the tumor and provide airway openness.

The most appropriate surgical technique is dependent upon the location of the adenoma. Thoracotomy is the preferred surgical approach for lesions located in the middle and posterior mediastinum [16]. In our case, thoracotomy was performed to excise the remaining residual tissue after rigid bronchoscopic PT adenoma resection. Right posterolateral thoracotomy allowed the right hemithorax to be explored. A 2-cm tumor was found in the distal

part of the trachea, extending from the membranous surface to the posterior mediastinum, starting 2 cm above the carina and extending 2 cm cranially. The trachea was dissected from the surrounding tissues at this site. After dissection, the trachea was incised circularly 1 cm proximally and 1 cm distally; a total of 4 cm of tracheal tissue was resected.

In conclusion, PA may be seen endotracheally in an ectopic location. Clinicians should be aware of this rare entity, which can clinically mimic other common pulmonary pathologies, such as bronchial asthma.

Conflicts of interest

The authors declare no conflicts of interest.

Acknowledgments

The English in this document has been checked by at least two professional editors, both native speakers of English. For a certificate, please see: <http://www.textcheck.com/certificate/8aNHac>.

References

- [1] Rodrigues AJ, Coelho D, Dias Júnior SA, Jacomelli M, Scordamaglio PR, Figueiredo VR. Minimally invasive bronchoscopic resection of benign tumors of the bronchi. *J Bras Pneumol* 2011;37(6):796–800.
- [2] Akerstrom G, Malmaeus J, Bergstrom R. Surgical anatomy of human parathyroid glands. *Surgery* 1984;95(1):14–21.
- [3] Okuda I, Nakajima Y, Miura D, Maruno H, Kohno T, Hirata K. Diagnostic localization of ectopic parathyroid lesions: developmental consideration. *Jpn J Radiol* 2010;28(10):707–13.
- [4] Karvounaris DC, Symeonidis N, Triantafyllou A, Flaris N, Sakadamis A. Ectopic parathyroid adenoma located inside the hypoglossal nerve. *Head Neck* 2010;32:1273–6.
- [5] Arnault V, Beaulieu A, Lifante JC, Sitges Serra A, Sebag F, Mathonnet M, et al. Multicenter study of 19 aortopulmonary window parathyroid tumors: the challenge of embryologic origin. *World J Surg* 2010;34:2211–6.
- [6] Rani F, Kumar B, Reddy P, Narwal-Chadha R, Kasmani R, Tita J. An endobronchial lipoma mimicking asthma and malignancy. *Prim Care Respir J* 2010;19:281–3.
- [7] Smyrniotis NA, Irwin RS. Wheeze. In: Irwin RS, Curley FJ, Grossman RF, editors. *Diagnosis and treatment of symptoms of the respiratory tract*. Armonk, NY: Futura Publishing Company; 1997. p. 117–53.
- [8] Smith JR, Oates ME. Radionuclide imaging of the parathyroid glands: patterns, pearls, and pitfalls. *Radiographics* 2004;24:1101–15.
- [9] Denham D, Norman J. Cost-effectiveness of preoperative sestamibi scan for primary hyperparathyroidism is dependent solely upon the surgeon's choice of operative procedure. *J Am Coll Surg* 1998;186(3):293–305.
- [10] Nordin AJ, Larcos G, Ung O. Dual phase 99m-technetium sestamibi imaging with single photon emission computed tomography in primary hyperparathyroidism: influence on surgery. *Australas Radiol* 2001;45(1):31–4.
- [11] Weber T, Cammerer G, Schick C, Solbach C, Hillenbrand A, Barth TF, et al. Luster M.C-11 methionine positron emission tomography/computed tomography localizes parathyroid adenomas in primary hyperparathyroidism. *Horm Metab Res* 2010;42(3):209–14.
- [12] Evangelista L, Sorgato N, Torresan F, Boschin IM, Pennelli G, Saladini G, et al. FDG-PET/CT and parathyroid carcinoma: review of literature and illustrative case series. *World J Clin Oncol* 2011;2(10):348–54.
- [13] Rubello D, Pelizzo MR, Boni G, Schiavo R, Vaggelli L, Villa G, et al. Radioguided surgery of primary hyperparathyroidism using the low-dose 99mTc-sestamibi protocol: multiinstitutional experience from the Italian Study Group on radioguided surgery and immunoscintigraphy (GISCRIS). *J Nucl Med* 2005;46(2):220–6.
- [14] Bolliger CT, Sutedja TG, Strausz J, Freitag L. Therapeutic bronchoscopy with immediate effect: laser, electrocautery, argon plasma coagulation and stents. *Eur Respir J* 2006;27:1258–71.
- [15] Wahidi MM, Herth FJF, Ernst A. State of the art. *Interventional pulmonology*. *Chest* 2007;131:261–74.
- [16] Obara T, Fujimoto Y, Tanaka R, Ito Y, Kodama T, Yashiro T, et al. Mid-mediastinal parathyroid lesions: preoperative localization and surgical approach in two cases. *Jpn J Surg* 1990;20:481–6.