

Efficacy of radial keratotomy in the optical rehabilitation of mild to moderate keratoconus cases

Ibrahim Kocak^{1,2}, Ali Aydin^{1,2}, Faruk Kaya¹, Hakan Baybora¹, Salih Bozkurt³

¹Department of Ophthalmology, Nisa Hospital, Istanbul 34196, Turkey

²Ophthalmology Clinic, School of Medicine, Medipol University, Istanbul 34214, Turkey

³Inci Eye Hospital, Sakarya 54100, Turkey

Correspondence to: Ibrahim Kocak. Özel Nisa Hastanesi, Göz Hastalıkları Servisi, Fatih Caddesi, Yenibosna, Bahçelievler, Istanbul 34196, Turkey. ibrahimkocak@msn.com

Received:2012-09-11 Accepted:2015-01-16

放射状角膜切开术在轻中度圆锥角膜病例中视觉康复的疗效

Ibrahim Kocak^{1,2}, Ali Aydin^{1,2}, Faruk Kaya¹, Hakan Baybora¹, Salih Bozkurt³

(作者单位:¹34196 土耳其,伊斯坦布尔,Nisa 医院眼科;²34214 土耳其,伊斯坦布尔,Medipol 大学医学院临床眼科;³54100 土耳其,萨卡里亚,Inci 眼科医院)

通讯作者:Ibrahim Kocak. ibrahimkocak@msn.com

摘要

目的:探讨放射状角膜切开术在轻中度圆锥角膜治疗中光学和视力康复的效果。

方法:回顾性分析应用放射状角膜切开术治疗圆锥角膜的病例 22 例 31 眼并进行了至少 12mo 的随访。测量并分析术前术后裸眼视力,最佳矫正视力,自动屈光计值,角膜曲率,角膜不规则指数以及并发症。

结果:在最后一次随访中,平均裸眼视力(logMAR)由 0.86±0.34 显著提升至 0.30±0.29 ($P<0.0001$),平均最佳矫正视力由 0.47±0.21 提升至 0.17±0.23 ($P<0.0001$)。平均角膜曲率由 48.69±3.68D 降低至 44.33±3.09D ($P<0.0001$)。自动屈光计测得平均等效球镜值由 -5.61±2.85D 显著提升至 -2.29±1.95D ($P<0.0001$)。在整个随访过程中,中央角膜厚度和 3mm,5mm 区域的角膜不规则指数均无变化。术中和术后没有观察到严重并发症。

结论:在本组病例中,放射状角膜切开术是轻中度圆锥角膜视觉康复的有效治疗方法。

关键词:放射状角膜切开术;圆锥角膜;视觉重建

引用:Kocak I, Aydin A, Kaya F, Baybora H, Bozkurt S. 放射状角膜切开术在轻中度圆锥角膜病例中视觉康复的疗效. 国际眼科杂志 2015;15(4):572-576

Abstract

• **AIM:** To investigate the efficacy of radial keratotomy (RK) for the optical and visual rehabilitation of mild to moderate keratoconus.

• **METHODS:** Thirty-one eyes of 22 keratoconus patients

with at least 12mo follow-up were recruited and reviewed retrospectively. Uncorrected visual acuity (UCVA), best spectacle corrected visual acuity (BSCVA), autorefractometer values, keratometric values, corneal irregularity indexes, and complications were analyzed pre- and post-operatively.

• **RESULTS:** At the last follow-up visit, mean UVCA (logMAR) improved significantly from 0.86±0.34 to 0.30±0.29 ($P<0.0001$), and mean BSCVA (logMAR) improved from 0.47±0.21 to 0.17±0.23, ($P<0.0001$). Mean keratometric values decreased from 48.69±3.68 to 44.33±3.09 diopters ($P<0.0001$). Mean spherical equivalent measured by autorefractometer was also improved significantly from -5.61±2.85 to -2.29±1.95 at the last follow-up visit ($P<0.0001$). Central corneal thickness and corneal irregularity index of 3mm and 5mm zones did not change during the overall follow-up time. No serious intraoperative or postoperative complication was observed.

• **CONCLUSION:** RK is assessed as an effective treatment method for the optical and visual rehabilitation of mild to moderate keratoconus cases, according to our results in a selected group of keratoconus patients.

• **KEYWORDS:** radial keratotomy; keratoconus; optical rehabilitation

DOI:10.3980/j.issn.1672-5123.2015.4.02

Citation: Kocak I, Aydin A, Kaya F, Baybora H, Bozkurt S. Efficacy of radial keratotomy in the optical rehabilitation of mild to moderate keratoconus cases. *Guoji Yanke Zazhi(Int Eye Sci)* 2015; 15(4):572-576

INTRODUCTION

Keratoconus is a progressive disorder in which the cornea assumes a conical shape secondary to paraxial stromal thinning and protrusion^[1]. This ectatic corneal disorder has an incidence of approximately 1/2000^[2]. In advanced keratoconus with severe consequences such as irregular astigmatism, corneal scarring, and excessive thinning, patients ultimately require corneal transplantation surgery^[3]. In early cases, spectacles and soft contact lenses may provide adequate vision correction. However, rigid contact lenses are required for higher degrees of irregular astigmatism to render a regular refracting surface^[4,5]. When these patients show intolerance to contact lens, they are faced with the need of various surgical treatment modalities including incisional keratotomy, photorefractive keratectomy (PRK), epikeratoplasty, intrastromal ring implantation, and Athens protocol in which collagen cross-

linking is combined with topography guided PRK to maintain functional vision^[6-12].

In the past, radial keratotomy (RK) had been used for correction of myopic refractive errors until excimer laser became mainstay of treatment^[13]. In addition to treatment of myopia, it has been also used for optical rehabilitation of mild to moderate keratoconus^[14-17]. In our clinic, we have been treating keratoconus in selected cases using RK, since 2007, based on the technique reported by Utine *et al*^[14]. In this study, we retrospectively assessed our results to analyze the efficacy and safety of RK in keratoconus treatment.

SUBJECTS AND METHODS

Subjects Subjects enrolled in the study were consecutive keratoconus patients who underwent RK at the Nisa Hospital, Istanbul, Turkey, from January 2007 to November 2010. Informed consent approved by the local ethics committee was signed by all patients and the study was conducted in accordance with the Declaration of Helsinki. Patients who had met the following criteria were scheduled for surgery: keratoconus with a central corneal thickness (CCT) over 400 μ m, poor corrected visual acuity (≤ 0.4 at Snellen visual acuity charts), contact lens intolerance, no apical scarring, no ocular or systemic problem other than keratoconus. Although mild to moderate keratoconus was defined as keratoconus with an average keratometry of ≤ 54 diopters (D), patients with an average keratometry of >54 D were also included if they did not have corneal apical scarring, prominent Descemet's striae, or a CCT of $<400\mu$ m.

Contact lens wear was discontinued 1mo before the initial examination in all patients. All patients had a full ophthalmologic examination, including the objective refraction, uncorrected and best spectacle corrected Snellen visual acuity (UCVA and BSCVA), slit lamp examination, posterior segment examination, intraocular pressure measurement, corneal thickness measurement by using an ultrasonic pachymeter (DGH 4000B, DGH Technology, Inc., Frazer, PA, USA), and corneal topography (Orbscan II, Bausch&Lomb, Rochester, NY, USA), at the preoperative and postoperative visits. Postoperative follow up visits were scheduled at the 1st, 7th, 30th day and the 6th month after surgery, and then yearly afterward. Patients with at least 1y follow-up were included in the study.

Methods

Surgical procedure All the surgical treatments were performed under topical anesthesia. Radial incisions were made from limbus to center with a Russian type 30° RK diamond blade. Central optical zone marking was made with Thornton optical zone markers ranging from 3mm to 5mm. Profile markers with 4-10 lines were used for corneal marking before radial incisions. Depth of radial incisions was adjusted to 95% of CCT. The target correction was planned according to the preoperative objective cycloplegic refraction measurement. Ten to 12 radial incisions were made for correction of 5 or more diopters of myopia, and 8 incisions for 3-5D, 6 incisions for 1-3D, 4 incisions for one or less diopter were

made. Fine adjustment was achieved by optical zone assessment. Astigmatic corrections were made by oblique optical zone markers which provide longer and more central incisions at the steep axis. No arcuate incision was used for astigmatic correction. Astigmatic correction was not intended if the myopia was more than 8D. If the myopia was more than 10D, peripheral re-deepening was performed 7mm from the center of the cornea with 600 μ m incisions. Radial incisions were irrigated with a 27 gauge blunt tip cannula at the end of surgery.

Follow-up During the first postoperative week, patients were treated with topical antibiotic, artificial tear, and corticosteroid drops. At the end of the first week, topical antibiotic drops were discontinued. During the first postoperative week, patients were treated with topical antibiotic, artificial tear, and corticosteroid drops. At the end of the first week, topical antibiotic drops were stopped. Topical corticosteroids were stopped at the end of the first month with gradual tapering (4 \times 1 in first two weeks, 2 \times 1 in third week, and 1 \times 1 in the last week). In the case of emmetropia (spherical equivalent: 0.00 \pm 1.00D) or overcorrection by the end of the 1st month, corticosteroid was stopped. If there was undercorrection corticosteroid was continued 1 \times 1 for 3mo. Artificial tear substitutes were also used during the first month after surgery.

Statistical Analysis Paired two sample *t*-test and Wilcoxon matched pairs test were used to compare parameters before and after surgery. Two tailed distribution outcomes were accepted for *P* values. All analyses were performed with Statplus software (Analysoft, USA). *P* values less than 0.05 were considered to be statistically significant.

RESULTS

Fifty-five eyes of 36 patients with keratoconus had RK procedure at the Nisa Hospital between 2007 and 2010. Thirty-one eyes of 22 patients with at least one year follow-up were qualified for this study. The mean age \pm standard deviation (SD) of patients was 26.26 \pm 5.59y (range 18-41y). Fifteen of 22 patients were male and seven were female. Mean follow-up time was 18.16 \pm 10.83mo (range 12 - 52mo). Patient characteristics and baseline parameters are presented in Table 1. All of the patients were operated under topical anesthesia. Mean number of incisions was 9.35 \pm 2.03 (range 5 - 12). Seventeen (55%) of eyes were treated with 10 or more incisions, 13 (42%) with six or more, and one (3%) with less than six incisions. Oblique zone markers were used in 24 (77%) of eyes. In the remaining seven eyes circular optical zone markers were used. Mean optical zone diameter of these seven eyes was 3.29 \pm 0.39mm. No serious intraoperative or postoperative complication was observed. Microperforation occurred in two eyes and treated with therapeutic contact lens application.

At the last follow-up visit, mean UCVA and BSCVA were both increased compared to values of preoperative examination (*P* < 0.0001 for both) (Table 2). Mean BSCVA was improved by the first day of RK procedure and remained stable

Table 1 Patient characteristics and baseline refractive parameters ($\bar{x} \pm s$, range)

Characteristics	Baseline parameters
Age (a)	26.26±5.59 (18-41)
Gender (F/M)	7/15
UCVA (logMAR)	0.86±0.34 (0.30-1.30)
BSCVA (logMAR)	0.47±0.21 (0.30-1)
Spherical equivalent (D)	-5.61±2.85 (-1.50 to -14.00)
Corneal curvature (D)	48.69±3.68 (42.1-61.63)
Central corneal thickness(μm)	448.29±37.82(402-520)

till the last follow-up visit. Box-plot graphical presentation of the group's BSCVA changes was shown in Figure 1. Mean Snellen lines gained at the last follow-up visit was 3.71 ± 1.89 (range 0-6) for BSCVA, and 4.08 ± 2.37 (range 1-9) for UCVA. BSCVA improved in 29 of 31 eyes. In the remaining two eyes BSCVA did not change. None of the eyes showed worsening of BSCVA or UVCA. Mean spherical equivalent measured by autorefractometer was also significantly decreased at the last follow-up visit compared to preoperative values ($P < 0.0001$). There was a slight decrease in mean cylindrical refractive error, but it was not statistically significant. Objective refraction changes are presented in Table 2.

Mean keratometric values decreased significantly from $48.69 \pm 3.68D$ to $44.33 \pm 3.09D$ ($P < 0.0001$), and corneal astigmatism from $4.00 \pm 1.61D$ to $2.75 \pm 1.96D$ ($P = 0.0002$). CCT, and corneal irregularity index of 3mm and 5mm zones did not change significantly during the overall follow-up time ($P = 0.4189$, $P = 0.3975$ and $P = 0.6498$, respectively). Corneal changes were shown in Table 3. Keratometric values were decreased by the first day of RK procedure, and remained stable during the follow-up. The change of keratometric values is shown by using a box plot presentation in Figure 2. Corneal topography of a demonstrative case treated with RK was shown in Figure 3.

DISCUSSION

In this study, we reviewed and analyzed the outcomes of our RK experience in mild to moderate keratoconus patients with a CCT greater than $400\mu m$. Patients unwilling or intolerant to contact lens wear were recruited for RK procedure. Mild keratoconus patients that have satisfactory visual acuity with spectacles and advanced cases requiring penetrating keratoplasty were not eligible for the treatment. All the eyes showed improvement in UCVA, and 29 of 31 eyes showed improvement in BSCVA. Differences between last follow-up visit and preoperative state were statistically significant for both UCVA and BSCVA. Myopic refractive error, mean keratometric values, and corneal astigmatism all decreased significantly after RK procedure.

These findings were consistent with other studies in which RK was used for the optical rehabilitation of mild to moderate keratoconus, and keratoconus suspects^[14-17]. Grandon and Weber screened 1368 eyes treated with RK using corneal

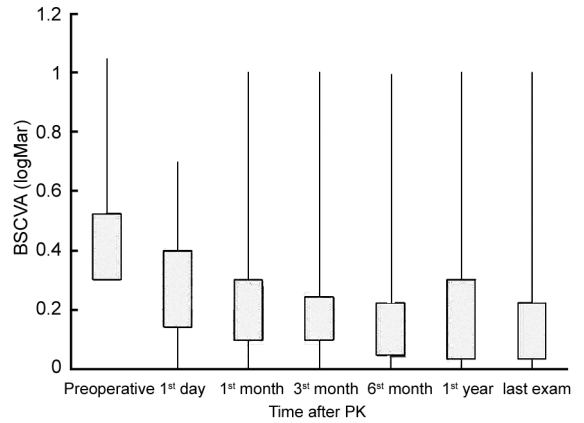


Figure 1 Box-plot graphic of the BSCVA change from before to after RK.

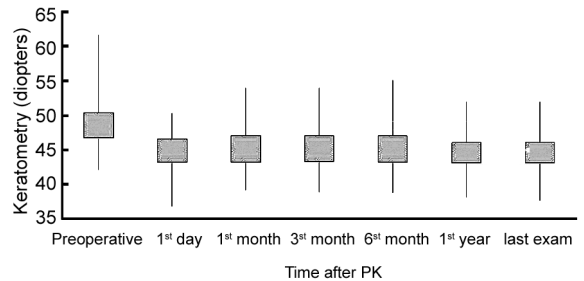


Figure 2 Box-plot graphic of keratometric change from before to after RK.

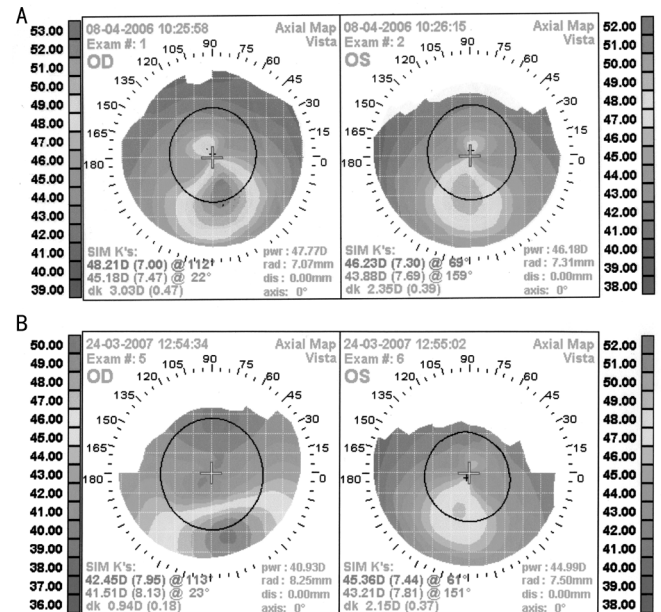


Figure 3 Corneal topography of a keratoconus case treated with RK Preoperative UCVA was 0.3 and BSCVA was 0.5 with -4.00 (170° -3.25) diopters. Mean corneal power calculated with Orbscan II was $46.3 \pm 3.1D$ (A). By the end of the first year of RK, UCVA increased to 0.8 and BSCVA to 1.0 with (60° -0.75) D. Mean corneal power decreased to $42.9 \pm 3.5D$ (B).

topography, and found that 14 eyes of nine patients exhibited topographic patterns of keratoconus suspect status before the surgery^[15]. They reported that refraction and UCVA improved in all 14 of these eyes at 4-19mo postoperatively. In a similar study, Bowman *et al*^[16] reviewed the records of 67 consecutive patients who underwent RK to determine the

Table 2 Visual acuity and objective refraction values before and after radial keratotomy ($\bar{x} \pm s$, range)

Parameters	Preoperative	Postoperative	P
UCVA			
LogMAR	0.86±0.34 (0.30–1.30)	0.30±0.29 (0–1)	<0.0001
Decimal	0.1	0.5	
BSCVA			
LogMAR	0.47±0.21 (0.30–1)	0.17±0.23 (0–1)	<0.0001
Decimal	0.3	0.7	
Spherical equivalent (D)	5.61±2.85 (1.50–14.00)	2.29±1.95 (0.25–8.00)	<0.0001
Cylinder (D)	3.15±1.45 (0.50–6.50)	2.57±1.64 (0.00–7.00)	0.0737

UCVA:Uncorrected visual acuity; BSCVA: Best spectacle corrected visual acuity.

Table 3 Corneal parameters before and after radial keratotomy ($\bar{x} \pm s$, range)

Parameters	Preoperative	Postoperative	P
Averagekeratometry (D)	48.69±3.68 (42.1–61.63)	44.33±3.09 (37.75–52.00)	<0.0001
Corneal astigmatism (D)	4.00±1.61 (1.50–8.25)	2.75±1.96 (0.50–8.00)	0.0002
Central corneal thickness (µm)	448.29±37.82 (402–520)	445.94±40.76 (384–518)	0.4189
Irregularity (3mm zone)	5.36±1.85 (2.6–9.2)	5.16±1.73 (1.5–8.9)	0.3975
Irregularity (5mm zone)	5.54±1.69 (2.8–9.2)	5.66±1.98 (1.7–12.6)	0.6498

frequency of keratoconus suspects by using videokeratography, and reported that three patients were identified as keratoconus suspect. All of these eyes achieved postoperative UCVA of 20/30 or better. In the large and detailed study of Utine *et al*^[14], authors presented their experience of RK for the optical rehabilitation of 96 patients with mild to moderate keratoconus. They reported that RK procedure yielded significant increase in UCVA and BSCVA as the result of corneal flattening and reduction of spherical – astigmatic refractive errors in keratoconus patients. This improvement was stable and remained relatively unchanged throughout the follow-up, as we observed in our patients.

In some previous studies, several uncommon late complications of RK are reported in cases with keratoconus. Sharma *et al*^[18] reported an acute hydrops development in a patient with subclinical keratoconus who underwent RK eight years ago. Panda *et al*^[19] presented three cases that had incisional dehiscence following blunt trauma 10 – 13y after RK. Durand *et al*^[20] also reported a similar dehiscence two years after RK. We did not observe such late complications in our series. Utine *et al*^[14] reported that they had observed microperforation in four eyes (2.2%) and perforation in two eyes (1.2%), with an incision depth of 100% of CCT. In our study, microperforation occurred in two eyes during the operation. No perforation was observed in our patients. This may be related to our more conservative incision depth that we assigned as 95% of CCT. Besides, we have a limited case number compared to Utine *et al*'s^[14] study.

Late hyperopic shift following RK due to progressive corneal flattening is reported in some previous studies^[14, 21]. Additionally, Saragoussi *et al*^[22,23] suggested that subclinical keratoconus might be a possible cause of progressive corneal flattening following RK. In our study, myopic refractive error (spherical equivalent) decreased from -2.26±2.16D (at the

6th month after RK) to -1.96±2.30D at the last follow-up visit (P = 0.0262). Mean keratometry also decreased from 44.64±3.33D (at the 6th month after RK) to 44.33±3.09D at the last follow-up visit (P = 0.0204). These findings reveal the presence of late hyperopic shift due to progressive corneal flattening that shows consistence with previous studies. We believe that hyperopic shift of less than 1D after RK would not create a significant problem in cases with keratoconus who are mostly left with some degree of myopic error following RK operation.

CCT and irregularity index of 3mm, and 5mm zone did not change during the overall follow-up time in our study. These results can be interpreted as RK limits the progression of keratoconus disease at least during follow-up time of our study. We think that fibrotic activation promoted by RK incisions may strengthen the biomechanical structure of cornea and limit progression of disease. It has been shown that perpendicular incisions could trigger a more significant corneal wound healing process compared to lamellar incisions. Additionally, epithelial plugs above the RK incisions cause fibrotic activation even after years^[24, 25].

The visual rehabilitation issue of contact lens intolerant cases with mild to moderate keratoconus is still controversial. Authors have suggested different surgical treatment modalities including incisional keratotomy, photorefractive keratectomy, epikeratoplasty, intrastromal ring implantation, and Athens protocol to treat these patients^[6-12]. The procedures that attenuate biomechanical structure of cornea by thinning may increase the progression of keratoconus. However, combining collagen cross linking with surgical procedures such as PRK gives promising outcomes as in the case of Athens protocol. In the study of Kanellopoulos^[26], UCVA (logMAR) improved from 0.96±0.2 to 0.3±0.25, and BSCVA from 0.39±0.3 to 0.11±0.16 in keratoconus cases treated with Athens protocol,

similar to our results. Intracorneal ring segment implantation is another current option for visual rehabilitation of keratoconus patients. In the study of Kaya *et al*^[27], patients with keratoconus gained (0.18±0.04) lines of UCVA and (0.21±0.05) lines of BSCVA with Intacs rings; and gained (0.21±0.09) lines of UCVA, and (0.26±0.08) lines of BSCVA with Ferrara ring. Visual acuity improvement seems better with RK than ring implantation when these results compared to ours. Besides, some complications related to ring implantation such as severe corneal vascularization, anterior chamber perforation, ring exposure, and dense corneal infiltrates were reported^[28,29].

Nowadays, corneal collagen cross-linking has become the standard therapy for stabilizing the progressive keratoconus. It would be interesting to compare the effects of RK and corneal cross-linking on keratoconus in a large progressive study.

In conclusion, our study showed that RK is an effective method for the visual and optical rehabilitation of selected cases with mild to moderate keratoconus. However, these results should be interpreted with caution due to the small number of patients and limited follow-up period, and potential biases related to the retrospective and observational nature of our study.

REFERENCES

- 1 Feder RS, Kshetry P. Noninflammatory ectatic disorders. In: Krachmer JH, Mannis MJ, Holland EJ. eds. *Cornea* 2nd ed. Elsevier inc; 2005:955-974
- 2 Rabinowitz YS. Keratoconus. *Surv Ophthalmol* 1998;42(4):297-319
- 3 Zadok D, Schwartz S, Marcovich A, Bakana Y, Morad Y, Eting E, Avni I. Penetrating keratoplasty for keratoconus: long-term results. *Cornea* 2005;24(8):959-961
- 4 Szcotka LB, Barr JT, Zadnik K. A summary of the findings from the Collaborative Longitudinal Evaluation of Keratoconus (CLEK) Study. CLEK Study Group. *Optometry* 2001;72(9):574-584
- 5 Edrington TB, Szcotka LB, Barr JT, Achtenberg JF, Burger DS, Janoff AM, Olafsson HE, Chun MW, Boyle JW, Gordon MO, Zadnik K, The CLEK Study Group. Rigid contact lens fitting relationships in keratoconus. Collaborative Longitudinal Evaluation of Keratoconus (CLEK) Study Group. *Optom Vis Sci* 1999;76(10):692-699
- 6 Kasparova EA, Kasparov AA. Six-year experience with excimer laser surgery for primary keratoconus in Russia. *J Refract Surg* 2003;19(2 Suppl):250-254
- 7 Krumeich JH, Daniel J, Knulle A. Live-epikeratophakia for keratoconus. *J Cataract Refract Surg* 1998;24(4):456-463
- 8 Bilgihan K, Ozdek SC, Konuk O, Akata F, Hasanreisoglu B. Results of photorefractive keratectomy in keratoconus suspects at 4 years. *J Refract Surg* 2000;16(4):438-443
- 9 Siganos D, Ferrara P, Chatziniokolas K, Bessis N, Papastergiou G. Ferrara intrastromal rings for the correction of keratoconus. *J Cataract Refract Surg* 2002;28(11):1947-1951
- 10 Siganos SC, Kymnionis GD, Kartakis N, Theodorakis MA, Astryrakakis N, Pallikaris IG. Management of keratoconus with Intacs.

- Am J Ophthalmol* 2003;135(1):64-70
- 11 Spitznas M, Eckert J, Frising M, Eter N. Long-term functional and topographic results seven years after epikeratophakia for keratoconus. *Graefes Arch Clin Exp Ophthalmol* 2002;240(8):639-643
- 12 Krueger RR, Kanellopoulos AJ. Stability of simultaneous topography-guided photorefractive keratectomy and riboflavin/UVA cross-linking for progressive keratoconus: case reports. *J Refract Surg* 2010;26(10):827-832
- 13 Sanders DR, Marks RG. Prospective clinical study of radial keratotomy. *Ophthalmology* 1982;89(11):1292-1293
- 14 Utine CA, Bayraktar S, Kaya V, Kucuksumer Y, Eren H, Perente I, Yilmaz OF. Radial keratotomy for the optical rehabilitation of mild to moderate keratoconus: more than 5 years' experience. *Eur J Ophthalmol* 2006;16(3):376-384
- 15 Grandon SC, Weber RA. Radial keratotomy in patients with atypical inferior steepening. *J Cataract Refract Surg* 1994;20(6):670-671
- 16 Bowman CB, Thompson KP, Stulting RD. Refractive keratotomy in keratoconus suspects. *J Refract Surg* 1995;11(3):202-206
- 17 Lombardi M, Abbondanza M. Asymmetric radial keratotomy for the correction of keratoconus. *J Refract Surg* 1997;13(3):302-307
- 18 Sharma N, Sachdev R, Jindal A, Titiyal JS. Acute hydrops in keratectasia after radial keratotomy. *Eye Contact Lens* 2010;36(3):185-187
- 19 Panda A, Sharma N, Kumar A. Ruptured globe 10 years after radial keratotomy. *J Refract Surg* 1999;15(1):64-65
- 20 Durand L, Monnot JP, Burillon C, Assi A. Complications of radial keratotomy: eyes with keratoconus and late wound dehiscence. *Refract Corneal Surg* 1992;8(4):311-314
- 21 Waring GO 3rd, Lynn MJ, McDonnell PJ. Results of the prospective evaluation of radial keratotomy (PERK) study 10 years after surgery. *Arch Ophthalmol* 1994;112(10):1298-1308
- 22 Saragoussi JJ, Pouliquen YJ. Does the progressive increasing effect of radial keratotomy (hyperopic shift) correlate with undetected early keratoconus? *J Refract Corneal Surg* 1994;10(1):45-48
- 23 Saragoussi JJ. Progressive hyperopia after radial keratotomy. A new etiological hypothesis early keratoconus. *J Fr Ophthalmol* 1993;16(10):499-500
- 24 Cameron JD. Corneal reaction to injury. In: Krachmer JH, Mannis MJ, Holland EJ. eds. *Cornea* 2nd ed. : 2005 Elsevier Inc. ; 2005: 115-131
- 25 Tuli S, Goldstein M, Schultz GS. Modulation of corneal wound healing. In: Krachmer JH, Mannis MJ, Holland EJ. eds. *Cornea* 2nd ed. Elsevier inc. ; 2005:133-150
- 26 Kanellopoulos AJ. Comparison of sequential *vs* same-day simultaneous collagen cross-linking and topography-guided PRK for treatment of keratoconus. *J Refract Surg* 2009;25(9):812-818
- 27 Kaya V, Utine CA, Karakus SH, Kavadarli I, Yilmaz OF. Refractive and visual outcomes after Intacs *vs* ferrara intrastromal corneal ring segment implantation for keratoconus: a comparative study. *J Refract Surg* 2011;27(12):907-912
- 28 Kymnionis GD, Kontadakis GA. Severe corneal vascularization after intacs implantation and rigid contact lens use for the treatment of keratoconus. *Semin Ophthalmol* 2012;27(1-2):19-21
- 29 Kanellopoulos AJ, Pe LH, Perry HD, Donnenfeld ED. Modified intracorneal ring segment implantations (INTACS) for the management of moderate to advanced keratoconus: efficacy and complications. *Cornea* 2006;25(1):29-33