




In vivo wound-healing and *in vitro* antibacterial and antioxidant properties of *Carduus adpressus* extract

AYŞE ARZU ŞAKUL^{1*} , ŞULE AYLA² , MEHMET EVREN OKUR³ , AYŞE ESRA KARADAĞ⁴ 
, BENAY DAYLAN⁵ , ELİF GÜZEL⁶ , EKREM MUSA ÖZDEMİR⁷ , MEHMET YALÇIN
GÜNAL⁸ 

- 1 Department of Medical Pharmacology, Faculty of Medicine, Istanbul Medipol University, Beykoz 34815 Istanbul, Türkiye.
- 2 Department of Histology and Embryology, Faculty of Medicine, Istanbul Medeniyet University, Kadıköy 34720 İstanbul, Türkiye.
- 3 Department of Pharmacology, Faculty of Pharmacy, University of Health Sciences, Üsküdar 34668 İstanbul, Türkiye.
- 4 Department of Pharmacognosy, Faculty of Pharmacy, Istanbul Medipol University, Beykoz 34815 Istanbul, Türkiye.
- 5 Department of Histology and Embryology, Faculty of Medicine, Istanbul Medipol University, Beykoz 34815 Istanbul, Türkiye.
- 6 Department of Medical Pharmacology, Faculty of Medicine, Istanbul Medipol University, Beykoz 34815 Istanbul, Türkiye.
- 7 Department of Animal Facility, Research Institute for Health Sciences and Technologies, Istanbul Medipol University, Beykoz 34815 Istanbul, Türkiye.
- 8 Department of Physiology, Faculty of Medicine, Alanya Alaaddin Keykubat University, Alanya 07450 Antalya, Türkiye.

* AYŞE ARZU ŞAKUL. E-mail: aasakul@medipol.edu.tr (A.A.Ş.); Tel. +90-536-266 77-74.

Received: 07 October 2022 / Revised: 27 January 2022 / Accepted: 28 January 2022

ABSTRACT: *Carduus adpressus* has been used for its anti-hair loss effect in traditional folk medicine. The plant species is mainly distributed in Türkiye, Bulgaria, and the Western Caucasus. The studies on this specific plant in the genus *Carduus* is limited which remarks the significance of the current study. This study aims to investigate the antibacterial, antioxidant, and wound-healing properties of the methanolic extract of *Carduus adpressus*. Extract was obtained by maceration. The broth microdilution assay was performed on *Staphylococcus aureus*, *Enterococcus faecalis*, *Pseudomonas aeruginosa*, and *Escherichia coli*. DPPH and ABTS radical scavenging assays were performed to detect the antioxidant capacity. Wound-healing activity was tested using alloxan-induced diabetic BALB-c mice. 4 groups, control, vehicle, CAE and *Carduus adpressus* groups were treated with the relative agent for 10 days. Extract demonstrated 62.5 µg/mL MIC against *S. aureus* and *E. faecalis*, and 125 µg/mL MIC against *P. aeruginosa* and *E. coli*. ABTS assay showed higher antioxidant activity compared to the DPPH assay. *Carduus adpressus* group demonstrated strong regeneration, epithelisation, and angiogenesis compared to the control group on day 10. Additionally, expression of PDGF, VEGF, and collagen formation was increased in the *Carduus adpressus* group compared to the control group on day 10. Extract demonstrated strong antibacterial, antioxidant, and wound-healing activities which indicate that it could be a source in developing wound-healing agents.

KEYWORDS: Antibacterial; antioxidant; *Carduus adpressus*; extract; BALB-c mice; wound-healing

1. INTRODUCTION

Carduus adpressus is an endemic monotypic perennial shrub that can grow up to 100 centimeters, has lilac to purple flowers and it belongs to the *Asteraceae* family. The family *Asteraceae* includes more than 1600 genus, and *Carduus* genus has approximately 90 species. *Carduus adpressus* distributes worldwide however, it is mainly native to the Black Sea region of Türkiye, Bulgaria, and the Western Caucasus [1]. Traditionally, *C. adpressus* is used against hair loss [2]. The previous studies on *Carduus adpressus* and other *Carduus* species are limited. In a previous study that was conducted on *Carduus adpressus* collected from Gümüşhane province, antibacterial assays were performed on a variety of bacteria and yeasts. 4 different plant extract was tested for

How to cite this article: Şakul AA, Ayla Ş, Okur ME, Karadağ AE, Daylan B, Güzel E, Özdemir EM, Günal MY. *In vivo* wound-healing and *in vitro* antibacterial and antioxidant properties of *Carduus adpressus* extract. J Res Pharm. 2023; 27(2): 665-676.

their antimicrobial activity which were *n*-hexane, ethyl acetate, ethanol and methanol extracts, against various Gram-positive, Gram-negative bacteria, and yeasts. The results of MIC assays ranged between 32 to 64 µg/mL, some of them were lower than the control antimicrobial agent which indicated the antimicrobial properties of the plant species. The same study investigated the antioxidant property of the plant extract as well. DPPH and ABTS radical scavenging assays were performed and strong antioxidant property of the *C. adpressus* was observed [3]. Other species of the *Carduus* genus also demonstrated antibacterial and antioxidant properties. A study conducted on various endemic *Carduus* species from Bulgaria demonstrated antioxidant activity depending on several radical scavenging assays. In addition, the plant extracts were analysed and determined that they were rich in various phenolic acids and flavonoids [4]. Studies on extracts of *Carduus pycnocephalus* L. which cultivates in Saudi Arabia shown to demonstrate antibacterial, anti-inflammatory, antispasmodic, and hypotensive activities and were rich in fatty acid content [5]. Lastly, an endemic *Carduus* species to Türkiye, *Carduus lanuginosus*, was investigated for its antimicrobial and antioxidant activities and demonstrated strong biological activity. Additionally, it was detected that the various extracts of the plant species were rich in various flavonoids and phenols. This study also examined *in vitro* enzyme inhibitory activity of the plant extracts, they demonstrated α-amylase and α-glucosidase inhibitory activity [6]. Due to the limited studies in the literature on *Carduus adpressus* and other *Carduus* species, the chemical composition and biological activities of the plant extracts are yet to be investigated. To the best of our knowledge, this is the first *in vivo* study performed on *Carduus adpressus* species to investigate the wound-healing activity of the methanolic extract of the plant species on the alloxan-induced diabetic mice model.

The objective of this study is to determine *in vitro* antibacterial and antioxidant activities and *in vivo* wound-healing activity of the methanolic extract of *Carduus adpressus*. To determine these properties, methanolic extracts will be obtained. Then, *in vitro* broth microdilution assay, DPPH and ABTS radical scavenging assays, and *in vivo* wound-healing assay on alloxan-induce diabetes model in mice will be performed on the methanolic extracts.

2. RESULTS

2.2 Antibacterial Activity

The antibacterial activity of MeOH extracts of aerial parts of *Carduus adpressus* was evaluated according to the MIC values obtained from broth microdilution assay. The outcome of the current study was compared with the antibacterial inhibitory activity of the positive control antibiotic, Tetracycline.

Methanolic extract demonstrated antibacterial property against all the tested bacteria. The inhibitory effect was recorded higher in the Gram-positive bacteria rather than the Gram-negative bacteria. MIC of MeOH extract for both Gram-positive *S. aureus* ATCC 6538 and *E. faecalis* ATCC 29212 was the same and recorded as 62.5 µg/mL. Whereas the MIC of the MeOH extract for Gram-negative *P. aeruginosa* ATCC 10145 and *E. coli* NRLL B-3008 was recorded as 125 µg/mL. The MIC value of the positive control antibiotic Tetracycline was recorded as 0.0016 µg/mL for all the bacteria except for *S. aureus* ATCC 6538 which was recorded as 0.025 µg/mL. Previous studies conducted on *Carduus adpressus* extracts also shown that the methanolic extract has inhibitory activity against several pathogens including the strains tested on the current study (3). The MIC of the methanolic extract and Tetracycline against the tested microorganisms are shown in "Table 1".

Table 1. DPPH and ABTS radical scavenging activity of MeOH extracts of *Carduus adpressus* and the standards [IC₅₀ ± SD (mg/mL)].

Technique	<i>C. adpressus</i> extract	Standards
DPPH	0,35 ± 0,04	0,009 ± 0,002 (Ascorbic Acid)
ABTS	0,58 ± 0,02	0,034 ± 0,001 (Trolox)

2.3 Antioxidant Activity

The antioxidant activity of the MeOH extract of *C. adpressus* was tested with 2 different methods. DPPH free radicals scavenging ability was determined compared with standard ascorbic acid and ABTS radical scavenging ability was determined compared with standard trolox. IC₅₀ values were used to calculate the antioxidant activity which indicates the fractions of MeOH extract concentrations scavenge 50% DPPH and ABTS radicals. The plant species demonstrated antioxidant activity which confirmed that the methanolic extract of *C. adpressus* is rich in antioxidant content such as phenolic and flavonoid compounds. The

antioxidant activity of the plant species was slightly higher in the ABTS technique compared to the DPPH technique. The results of the antioxidant assays are summarized in “Table 2” below.

Table 2. MIC values of *Carduus adpressus* MeOH extract and control antibiotic on tested bacteria in µg/mL.

Column A	Column B	<i>C. adpressus</i> extract	Tetracycline
Gram-positive	<i>Staphylococcus aureus</i> ATCC 6538	62.5	0.025
	<i>Enterococcus faecalis</i> ATCC 29212	62.5	0.016
Gram-negative	<i>Pseudomonas aeruginosa</i> ATCC 10145	125	0.016
	<i>Escherichia coli</i> NRLL B-3008	125	0.016

2.4 *In vivo* Wound-Healing Activity

2.4.1 Macroscopic Wound-Healing

The differences between the macroscopic changes between the experimental groups were observed and evaluated through the treatment period of 10 days. After a few days of the treatment, the formation of the crust was seen on the wound site. After the crust fell off, a residual lesion was felt on the wound area. The treatments including blank gel, *Centella asiatica* extract, and *Carduus adpressus* extract didn't demonstrate any allergic skin reaction or irritation on the skin.

The wound-healing rate was calculated as the percent reduction in the wound size on the day 10 in comparison with day 0 for each group in order to estimate the wound treatment capability of the *Carduus adpressus* methanolic extract in diabetic mice. To assess the progress on the wound closure, quantitative measurements of the size of the wound were used routinely throughout the treatment [7]. The wound contraction and statistical significance between the groups are shown in “Figure 1”. On day 10, a statistically insignificant difference was observed in the wound contraction in the *Carduus adpressus* group in comparison with the control group ($p < 0.056$).

The healing percentage of the wound area was calculated at approximately 88.63 % for the control group, 90.9 % for the vehicle group, 93,18 % for the CAE group, and 95.45 % for the *Carduus adpressus* extract group.

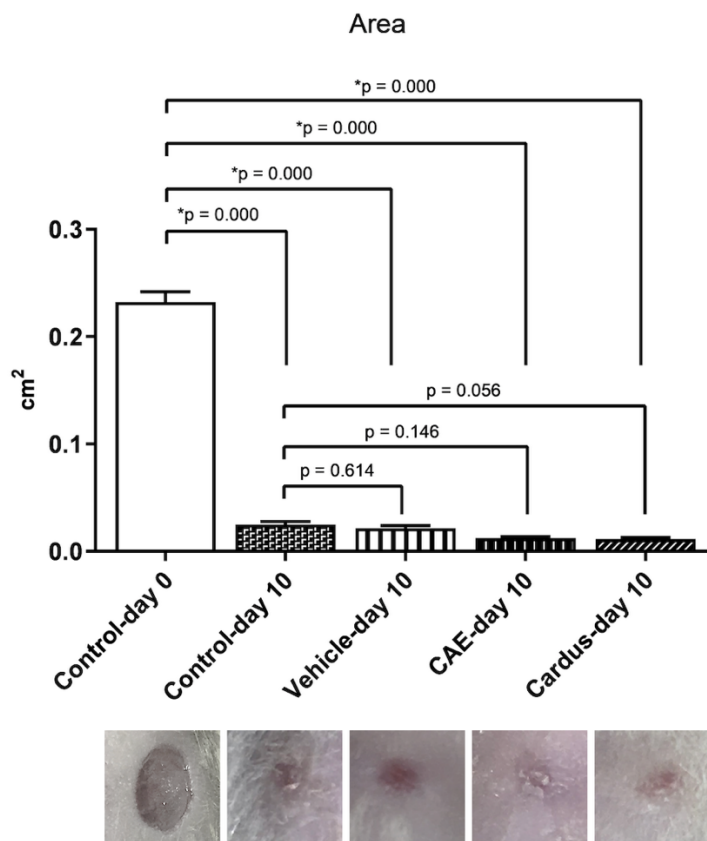


Figure 1. Macroscopic wound-healing percentage and the image of the wound area for each group in comparison with the control group on day 0 and day 10. The *Carduus adpressus* group is statistically insignificant in comparison with the control on day 10; $p > 0.05$.

2.4.2 Histology

In the current study, the formation of granulation tissue in the *Carduus adpressus* extract group was slightly thicker than the control Madecassol® group. The formation of granulation tissue was significant for the *Carduus adpressus* extract group in comparison with the control group on day 10 ($***p < 0.001$). Granulation is primarily related to the wound-healing process as it supports keratinocytes utilized by matrix and activates re-epithelization of the tissue site [8].

In addition, the *Carduus adpressus* extract group has shown a significant regeneration at the wound site in comparison with the control group ($***p < 0.001$) and with the Madecassol® group ($***p < 0.001$). The regeneration of the standard Madecassol® group and the *Carduus adpressus* group was almost the same which expressed strong wound-healing activity of the tested plant species. Lastly, angiogenesis was also increased in the *Carduus adpressus* extract group when compared with the control group. Fibroblast activity and support in the wound site are enhanced by angiogenesis. An increase in the fibroblast activity stimulates the formation of granulation tissue, and reactive oxygen species in the wound site decreases the proliferation of the fibroblasts and collagen synthesis as a result in diabetic patients. An agent that could stimulate the activity of fibroblast and the following cascades could be used as a strong wound-healing agent, especially in diabetic patients. The comparison of the regeneration, granulation, and angiogenesis of the experimental groups is shown in "Figure 2".

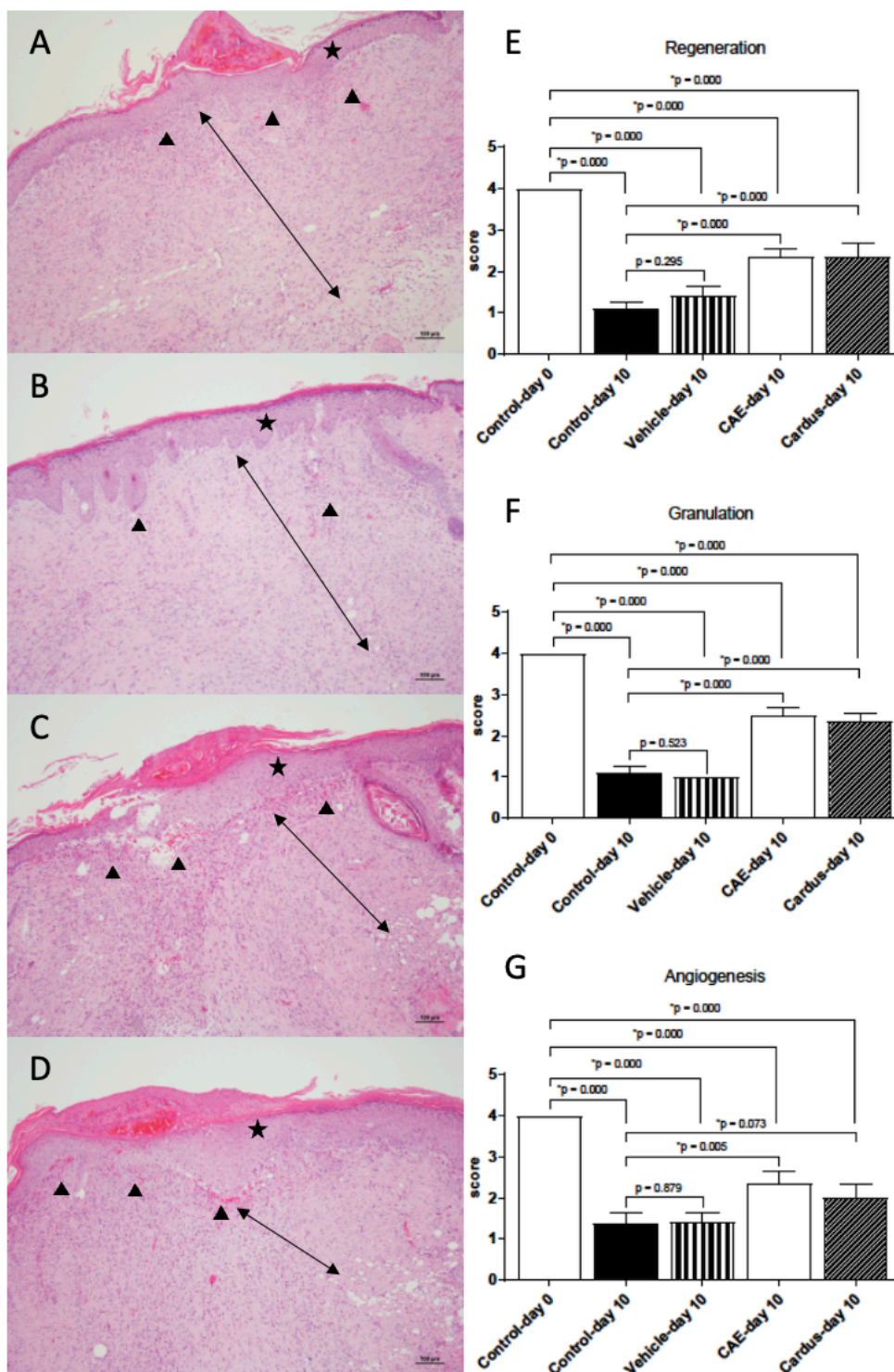


Figure 2. Histological views of the injured tissues of the control group (A), vehicle gel group (B), CAE group (C), *Carduus adpressus* test group (D). (E) Histological scores of epidermal regenerations of all groups, significant to control; $p < 0.001$ (***) . (F) Histological scores of granulation tissue thickness of all groups, significant to control; $p < 0.001$ (***) . (G) Histological scores of angiogenesis of all groups, insignificant to control; $p > 0.05$. All the values are presented as the mean \pm SEM. Arrows represent granulation tissue thickness, stars represent epidermal regenerations, triangles represent angiogenesis.

In the current study, it was shown that the expression of the PDGF, VEGF, and collagen was increased in the *Carduus adpressus* extract group, and in the Madecassol® group in comparison with the control. Even though the expression of these growth factors was slightly decreased in the *Carduus adpressus* extract group

compared with the Madecassol® group, the level of expression was still considerably higher when compared with the control group.

Comparison of the expression of PDGF, VEGF, and collagen formation between the experimental groups are shown in “Figure 3”.

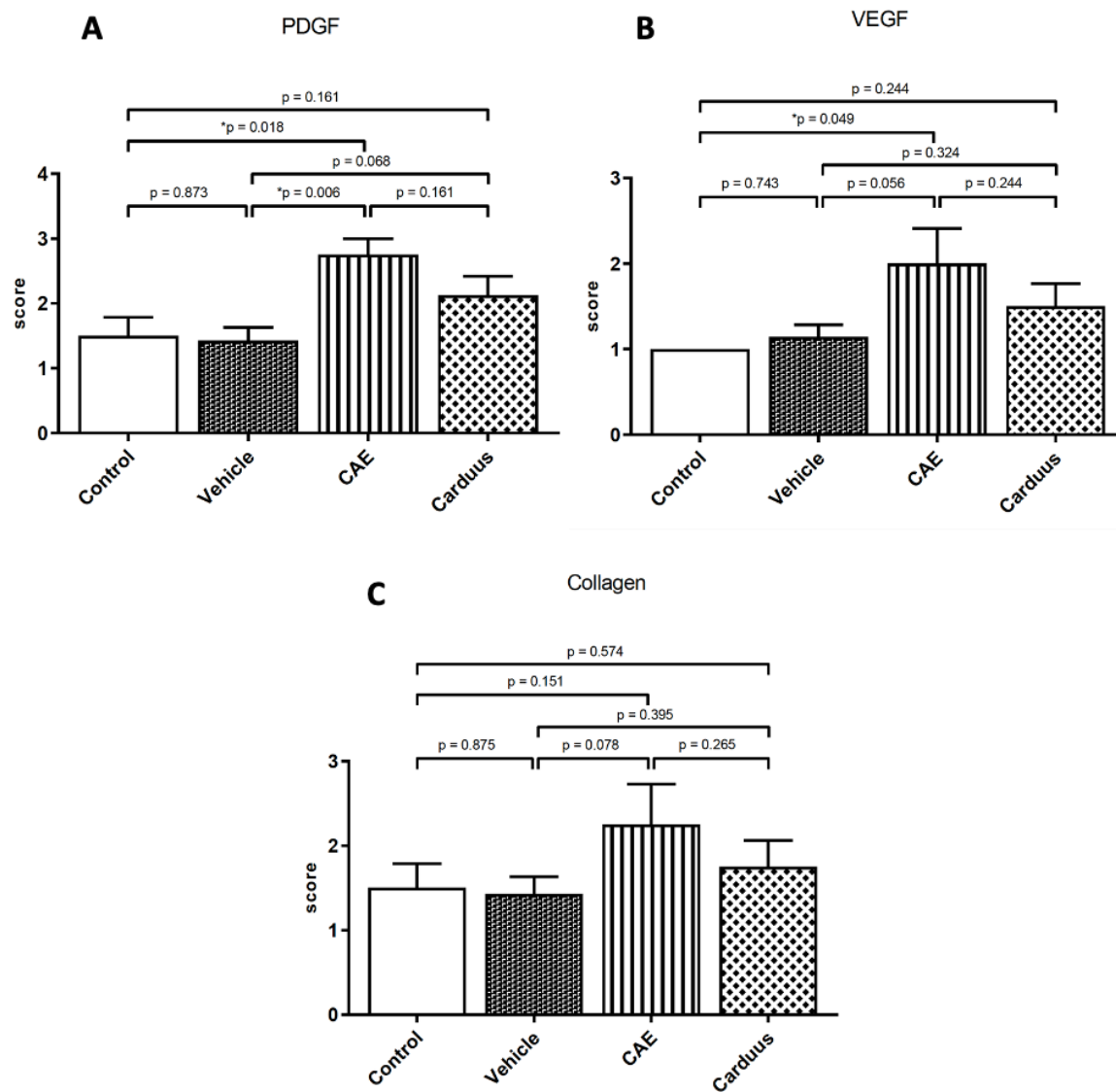


Figure 3. Comparison of immunohistochemistry PDGF wound-healing score among different groups. Statistically insignificant compared to control; $p > 0.05$ (B) Statistically insignificant compared to control; $p > 0.05$ (C) Comparison of immunohistochemistry collagen wound-healing score among different groups. Statistically insignificant compared to control; $p > 0.05$. All the values are presented as the mean \pm SEM.

3. DISCUSSION

The tested microorganisms are commonly known for causing intestinal and upper respiratory infections [9-11]. Especially *S. aureus* is known as one of the major causes of nosocomial infections, and there is an increase in antibiotic resistance among the *S. aureus* strains [12]. Considering the emerging need of discovering novel antibacterial agents against antibiotic-resistance bacterial strains, natural sources have been one of the biggest resources [13,14]. Natural sources such as plant materials have been used as herbal remedies for different purposes including antibacterial activity for centuries. Plants such as *Carduus adpressus* which show

inhibitory activities against several pathogens are promising natural sources for developing novel antibacterial agents.

The wound contraction and epithelization ability of a certain topical agent of the possible drug candidate are mostly studied with excision wound technique [15]. Certain factors play a crucial role in the contraction of an open wound including granulation tissue formation and re-epithelization which are evaluated in the current study to understand the wound-healing ability of *Carduus adpressus* methanolic extract [16]. To this date, it has been shown that topical pharmaceutical drug forms have more efficacy on an open wound when compared with other forms as they have larger availability on the site of the wound when administered [17].

Wound-healing process involves different molecular and cellular events and consists of several phases which must happen in a proper sequence including hemostasis, inflammation, proliferation, and remodeling. Several factors can interfere with the phases of wound-healing including oxygenation, infection, obesity, stress, and hormones [18,19].

One of the most crucial factors that affect the wound-healing process is diabetes. Diabetes affects thousands of people worldwide, and diabetic people are prone to develop non-healing chronic diabetic wounds including chronic foot ulcers [20]. Several multi-complex pathophysiological mechanisms can cause impaired healing of cutaneous wounds as well as diabetic foot ulcers. Wounds in diabetic patients are mostly accompanied by hypoxia [21]. Phases of wound-healing in diabetic organisms can differ in comparison with non-diabetic organisms. The wound-healing process could be trapped in one of the phases or rapid healing could be seen due to the loss of one of the cascades throughout the healing process [22]. Insufficient perfusion and angiogenesis are the major causes of hypoxia which are essentially detrimental to the wound-healing process. Hypoxia can cause an early inflammatory response which leads to an increase in the reactive oxygen species and prolongs the healing of the wound [23].

Some of the dysregulated cellular functions that occur in diabetic wounds are defective T-cell immunity, defects in leukocyte chemotaxis, phagocytosis, bactericidal capacity, and fibroblast dysfunction. Due to these defective cellular processes, bacterial clearance on the site of the wound is delayed and impaired wound-healing is seen in diabetes [24]. Previous studies have investigated that the level of vascular endothelial growth factor (VEGF) and the primary pro-angiogenic factor in wounds are decreased in diabetic wounds which is the reason for the decreased vascularization in diabetes [20,25,26]. Previous *in vivo* studies have shown that restoration of VEGF demonstrated a promising outcome in treating diabetic wounds [27,28].

Angiogenesis involves the development of neutrophils, macrophages, thrombocytes, keratinocytes, and fibroblasts therefore, it has a crucial role of the wound-healing process [29,30]. Delay in the maturation in the granulation tissue is seen along with a persistent inflammatory phase in diabetic wounds which is thought to occur due to ischemia as a result of vascular damage [31].

In addition to the aforementioned growth factors such as VEGF, other cascades also have a crucial role in the wound-healing process including platelet-derived growth factor (PDGF) and the formation of collagen. In diabetic people, these growth factors are mostly dysregulated therefore, impediment in the healing of the wound is seen [19]. During the wound-healing process, granulation tissue plays an important role as a protective barrier against infections by migrating epithelial cells to the wound site. However, the physiological mechanisms are disrupted in diabetic patients. Several growth factors including PDGF, fibroblast growth factor (FGF), epidermal growth factor (EGF), and VEGF are decreased in chronic wounds.

4. CONCLUSION

In conclusion, the current study investigated *in vitro* antibacterial and antioxidant, and *in vivo* wound-healing properties of endemic *Carduus adpressus*. The plant used in the present study has limited research in the literature, therefore our study gave an insight into the biological activities of the plant species. The outcome of the *in vitro* antibacterial and antioxidant assays and *in vivo* wound-healing experiments are remarkable. The antibacterial and antioxidant properties of the plant species are thought to be one of the causes of the strong wound-healing property of the plant species on the diabetic mice model. As the bactericidal function and the function of the T-cell are dysregulated in diabetes, an agent that exerts antibacterial activity could optimize the wound-healing treatment. Similarly, as the reactive oxygen species increase at the wound size in diabetes, antioxidant agents could also optimize the wound-healing treatment. In the current study, *Carduus adpressus* extract demonstrated strong antibacterial and antioxidant properties. It can be said that the remarkable wound-healing activity of the plant species could be due to these properties of the plant species. To the best of our knowledge, depending on the results of the current study, *Carduus adpressus* can be a source in developing novel antibacterial and antioxidant compounds as well as a wound-healing agent in diabetic

patients. Future studies will focus on determining the chemical composition of the MeOH extract and isolating the compounds to decide the bioactive compounds.

5. MATERIALS AND METHODS

5.1 Plant Material

Carduus adpressus was collected during the flowering season from its natural habitat. Plant material was identified, and it was deposited to the Herbarium of the Istanbul Medipol University School of Pharmacy, Pharmacognosy Department, Istanbul, Türkiye with the voucher specimen number IMEF1200.

5.2 Preparation of Plant Extracts

Plant material was air-dried and ground to obtain fine powder for further extraction. Aerial parts of the plant material were extracted with methanol. The methanolic extract was obtained with maceration for 24 hours. The solvent was evaporated with a rotary evaporator (Heidolph, Germany) and the remaining whole extract was stored in a fridge at $-20\text{ }^{\circ}\text{C}$ until further analysis.

5.3 Bacterial Strains

4 standard bacterial strains, 2 of which were Gram-positive and 2 Gram-negative were used in the study to test the antibacterial activity of the whole methanolic extract of *Carduus adpressus*. The Gram-positive bacteria were *Staphylococcus aureus* ATCC 6538 and *Enterococcus faecalis* ATCC 29212, and the Gram-negative bacteria were *Pseudomonas aeruginosa* ATCC 10145 and *Escherichia coli* NRLL B-3008.

5.4 Antibacterial Activity

In vitro antibacterial analysis was performed in duplicate by using broth microdilution assay. Standard protocol for Clinical and Laboratory Standards Institute [32] was followed, and minimum inhibitory concentrations (MIC) of the plant extract and the positive control were determined against the tested microorganisms. Tetracycline was used as a positive control antibiotic. All tested bacteria were sub-cultured in Mueller-Hinton broth at $37\text{ }^{\circ}\text{C}$ for 24 hours, and the cation levels of the Mueller-Hinton broth was adjusted to include 20 mg/L Ca^{2+} and 10 mg/L Mg^{2+} cations. Then, the microorganisms were prepared in sterile saline solution (0.85% NaCl) with 1×10^8 CFU/mL inoculum density and compared with 0.5 MacFarland turbidity standard.

Stock solutions and extract were dissolved and prepared in dimethylsulfoxide (DMSO). Starting concentration of the extract was prepared as $500\text{ }\mu\text{g/mL}$ and serial dilution was done up to column 10. Columns 11 and 12 were used as growth control and sterility control, respectively. The antibacterial activity of the extract was determined in comparison with the positive control Tetracycline, and the minimum inhibitory concentration, where no bacterial growth was observed, was recorded as MIC value. The MIC of the methanolic extract and Tetracycline against the tested microorganisms are shown in "Table 1".

5.5 Antioxidant Activity

2 different assays, DPPH radical scavenging assay, and ABTS radical scavenging assay were performed to determine the total antioxidant capacity of the methanolic extract [33,34].

5.5.1 DPPH Radical Scavenging Assay

The previously described protocol by Blois [35] was followed to determine total antioxidant capacity by DPPH radical scavenging assay. The reaction mix was prepared to contain $100\text{ }\mu\text{M}$ DPPH and methanolic extract. The reaction mix was stored for 30 mins then, the absorbance was read and recorded by using UV-Vis spectrophotometer at 517 nm. Ascorbic acid was used as a positive control. The analysis was performed in duplicate. The radical scavenging activity (RSA) was calculated at IC_{50} with the following formula: $\text{DPPH RSA \%} = [(\text{Absorbance}_{\text{control}} - \text{Absorbance}_{\text{test sample}}) / \text{Absorbance}_{\text{control}}] \times 100$

5.5.2 ABTS Radical Scavenging Assay

The previously described ABTS cation decolorization protocol by Re and colleagues [36] was followed to determine the antioxidant capacity of the plant extract. ABTS was produced with the reaction of 2.45 mM potassium persulfate and 7 mM aqueous ABTS. The obtained mixture was stored at $25\text{ }^{\circ}\text{C}$ in a dark place, for 16 hours before further analysis. On the analysis day, the whole methanolic extract was added to the mixture and the absorbance of the test sample was recorded at 734 nm at $25\text{ }^{\circ}\text{C}$ by using a UV spectrophotometer.

Trolox and ethanol were used as positive control and negative control, respectively. The experiment was performed in duplicate. The results were calculated at IC_{50} by using the following formula:

$$ABTS\ RSA\ \% = [(Absorbance_{control} - Absorbance_{test\ sample}) / Absorbance_{control}] \times 100$$

The results of the ABTS and DPPH radical scavenging assays are shown in "Table 2".

5.6 *In vivo* Wound-Healing Activity

5.6.1 Experimental Animals

The BALB-c mice (26 – 30 g) were used in the study. Test animals were hosted in standard cages with access to a standard nutritionally balanced diet and tap water, *ad libitum*, in a climate room under controlled conditions. The room conditions were adjusted to 23 ± 2 °C temperature and 50 ± 10 % relative humidity, with an inverted 12-hour light cycle (lights off at 8 a.m.).

All the procedures performed on the animals were in strict accordance with the European Council Directive (EU2010/63) guidelines. Ethics Committee of Istanbul Medipol University (No: 38828770-604.01.01-65387) was reviewed and approved all the procedures and protocols performed on the animals in accordance with the Standards for the Care and Use of Laboratory Animal.

5.6.2 Induction of Diabetes Mellitus

In order to induce diabetes mellitus, an intraperitoneal (i.p.) injection of freshly prepared alloxan was injected in an isotonic saline solution into the mice after an overnight (12 hours) fasting period. The injection was repeated 3 times over a 48-hour period. Fasting blood glucose concentration above 200 mg/mL on day 7 after the administration of alloxan was confirmed as diabetic mice [37].

5.6.3 Wound Formation and Experimental Groups

4 experimental groups were generated randomly (n=7).

Group 1: Control group. These animals were left untreated.

Group 2: Vehicle group. The animals were treated with blank gel (no drug content).

Group 3: CAE group. Standard group, the animals were treated with Madecassol® (Bayer, Switzerland) (*Centella asiatica* extract).

Group 4: Test group. The animals have treated with *Carduus adpressus* methanolic extract.

Single intraperitoneal Ketamine/Xylazine (100/10 mg/kg) injection was administered to the mice as an anesthetic. Dorsal hair was removed with an electric razor, exposed skin area was cleaned with a povidone-iodine solution. Bilateral circular full-thickness wounds were formed by a 5 mm punch biopsy on the back of the animals. The related treatments were done once a day for 10 days in each group [38].

5.6.4 Macroscopic Assessment

Day 0 was accepted as the day the wounds were formed, and the wound-healing was observed and evaluated until day 10. The area of the wound was measured on day 0 and day 10 by using ImageJ (National Institutes of Health, Bethesda, MD, USA). The wound contraction rate was calculated with the following formula: % Wound contraction = (Wound Area_{actual} / Wound Area_{initial}) × 100

5.6.5 Histological Assessment

The animals were sacrificed, and a 5 mm margin of the scar tissue and ambient unwounded skin was removed. All the fixation was done in 10% neutral formalin for all the collected samples for further histological evaluation. After 24 hours, the samples were bisected, embedded in paraffin, and sectioned in 5 µm thick layers. The layers were mounted on glass slides, dewaxed and rehydrated with distilled water. Finally, stained with hematoxylin-eosin (H&E) for further examination under a light microscope.

The ranking method described by Galeano et al. was used to assess the wound-healing rates of experimental groups [39]. Regeneration score was determined with the system as followed; 1: Poor epidermal formation ≥ 20%; 2: Incomplete epidermal formation ≥ 40%; 3: Moderate epidermal formation ≥ 60%; 4: Complete epidermal formation ≥ 80%. Scoring of the thickness of the granulation tissue was; 1: thin granulation layer; 2: moderate granulation layer; 3: thick granulation layer; 4: very thick granulation layer.

Evaluation of angiogenesis was done by counting and identifying mature vessels only in the presence of erythrocytes in the lumen. In order to identify the poorly and well-formed capillary vessels, the presence of edema, hemorrhage, congestion thrombosis, and intra/intervascular fibrin formation was evaluated. Angiogenesis scoring system was; 1: 1-2 new capillary vessels formation, high level of hemorrhage, edema, occasional congestion, and thrombosis; 2: 3-4 new capillary vessels formation, occasional congestion, moderate

edema and hemorrhage, intravascular fibrin deposition, and absence of thrombosis; 3: 5-6 new capillary vessels formation; 4: >7 new capillary vessels formation.

5.7 Statistical Analysis

The results were given as mean \pm standard error of the mean (Mean \pm SEM) p values. Statistical analyses were done by using GraphPad Prism 8.0 software. One-way ANOVA was done to analyze the statistical significance between the experimental groups. Values of $p < 0.05$ were considered statistically significant.

Acknowledgements: Declared none.

Author contributions: Concept - A.A.Ş.; Design - A.A.Ş., M.E.O.; Supervision - A.A.Ş.; Resources - A.A.Ş., M.E.O.; Materials - A.A.Ş., Ş.A., M.E.O., A.E.K., B.D., E.G., E.M.Ö., M.Y.G.; Data Collection and/or Processing - A.A.Ş., Ş.A., M.E.O., A.E.K., B.D., E.G., E.M.Ö., M.Y.G.; Analysis and/or Interpretation - A.A.Ş., M.E.O., E.G.; Literature Search - A.A.Ş., Ş.A., E.G.; Writing - A.A.Ş., E.G.; Critical Reviews - A.A.Ş., M.E.O., E.G.

Conflict of interest statement: The researchers would like to declare no conflict of interest.

REFERENCES

- [1] Davis P. Flora of turkey and the east aegean islands. Vol. 5. Edinburgh University Press; 1975.
- [2] Güneş F, Özhatay N. An ethnobotanical study from kars eastern turkey. *Biyolojik Çeşitlilik Ve Koruma*. 2011 Apr 15;4(1):30-41.
- [3] Acet T. A study on antioxidant properties and antimicrobial activity of various extracts of *carduus adpressus*. *J Anatol Environ Anim Sci*. 2019 Dec 30;4(3):409-13. [CrossRef]
- [4] Dimitrova-Dyulgerova I, Zhelev I, Mihaylova D. Phenolic profile and in vitro antioxidant activity of endemic bulgarian *carduus* species. *Pharmacogn Mag*. 2015;11(44):575. [CrossRef]
- [5] Al-Shammari LA, Hassan WHB, Al-Youssef HM. Phytochemical and biological studies of *carduus pycnocephalus* l. *J Saudi Chem Soc*. 2015 Jul;19(4):410-6. [CrossRef]
- [6] Özcan K. Determination of biological activity of *carduus lanuginosus* : an endemic plant in turkey. *Int J Environ Health Res*. 2021 Jan 2;31(1):45-53. [CrossRef]
- [7] Abu-Al-Basal MA. Healing potential of *rosmarinus officinalis* l. on full-thickness excision cutaneous wounds in alloxan-induced-diabetic balb/c mice. *J Ethnopharmacol*. 2010 Sep;131(2):443-50. [CrossRef]
- [8] Devalliere J, Dooley K, Hu Y, Kelangi SS, Uygun BE, Yarmush ML. Co-delivery of a growth factor and a tissue-protective molecule using elastin biopolymers accelerates wound healing in diabetic mice. *Biomaterials*. 2017 Oct;141:149-60. [CrossRef]
- [9] Golob M, Pate M, Kušar D, Dermota U, Avberšek J, Papić B, et al. Antimicrobial resistance and virulence genes in *enterococcus faecium* and *enterococcus faecalis* from humans and retail red meat. *BioMed Res Int*. 2019 May 9;2019:1-12. [CrossRef]
- [10] Manges AR, Geum HM, Guo A, Edens TJ, Fibke CD, Pitout JDD. Global extraintestinal pathogenic *escherichia coli* (expec) lineages. *Clin Microbiol Rev* [Internet]. 2019 Jun 19 [cited 2021 Dec 20];32(3). Available from: <https://journals.asm.org/doi/10.1128/CMR.00135-18> [CrossRef]
- [11] Pang Z, Raudonis R, Glick BR, Lin TJ, Cheng Z. Antibiotic resistance in *pseudomonas aeruginosa*: mechanisms and alternative therapeutic strategies. *Biotechnol Adv*. 2019 Jan;37(1):177-92. [CrossRef]
- [12] Turner NA, Sharma-Kuinkel BK, Maskarinec SA, Eichenberger EM, Shah PP, Carugati M, et al. Methicillin-resistant *staphylococcus aureus*: an overview of basic and clinical research. *Nat Rev Microbiol*. 2019 Apr;17(4):203-18. [CrossRef]
- [13] Aslam B, Wang W, Arshad MI, Khurshid M, Muzammil S, Rasool MH, et al. Antibiotic resistance: a rundown of a global crisis. *Infect Drug Resist*. 2018 Oct. [CrossRef]

- [14] Chassagne F, Samarakoon T, Porras G, Lyles JT, Dettweiler M, Marquez L, et al. A systematic review of plants with antibacterial activities: a taxonomic and phylogenetic perspective. *Front Pharmacol*. 2021 Jan 8;11:586548. [[CrossRef](#)]
- [15] Liu WY, Tzeng TF, Liu IM. Healing potential of zerumbone ointment on experimental full-thickness excision cutaneous wounds in rat. *J Tissue Viability*. 2017 Aug;26(3):202-7. [[CrossRef](#)]
- [16] Kandhare AD, Ghosh P, Bodhankar SL. Naringin, a flavanone glycoside, promotes angiogenesis and inhibits endothelial apoptosis through modulation of inflammatory and growth factor expression in diabetic foot ulcer in rats. *Chem Biol Interact*. 2014 Aug;219:101-12. [[CrossRef](#)]
- [17] Suriyamoorthy S, Subramaniam K, Jeevan Raj Durai S, Wahaab F, Pemila Edith Chitraselvi R. Evaluation of wound healing activity of acacia caesia in rats. *Wound Med*. 2014 Dec;7:1-7. [[CrossRef](#)]
- [18] Cho H, Blatchley MR, Duh EJ, Gerecht S. Acellular and cellular approaches to improve diabetic wound healing. *Adv Drug Deliv Rev*. 2019 Jun;146:267-88. [[CrossRef](#)]
- [19] Guo S, DiPietro LA. Factors affecting wound healing. *J Dent Res*. 2010 Mar;89(3):219-29. [[CrossRef](#)]
- [20] Brem H, Tomic-Canic M. Cellular and molecular basis of wound healing in diabetes. *J Clin Invest*. 2007 May 1;117(5):1219-22. [[CrossRef](#)]
- [21] Tandara AA, Mustoe TA. Oxygen in wound healing: more than a nutrient. *World J Surg*. 2004 Mar 1;28(3):294-300. [[CrossRef](#)]
- [22] Shah SA, Sohail M, Khan S, Minhas MU, de Matas M, Sikstone V, et al. Biopolymer-based biomaterials for accelerated diabetic wound healing: a critical review. *Int J Biol Macromol*. 2019 Oct;139:975-93. [[CrossRef](#)]
- [23] Woo K, Ayello EA, Sibbald RG. The edge effect: current therapeutic options to advance the wound edge. *Adv Skin Wound Care*. 2007 Feb;20(2):99-117. [[CrossRef](#)]
- [24] Loots MAM, Lamme EN, Zeegelaar J, Mekkes JR, Bos JD, Middelkoop E. Differences in cellular infiltrate and extracellular matrix of chronic diabetic and venous ulcers versus acute wounds. *J Invest Dermatol*. 1998 Nov;111(5):850-7. [[CrossRef](#)]
- [25] Gallagher KA, Liu ZJ, Xiao M, Chen H, Goldstein LJ, Buerk DG, et al. Diabetic impairments in no-mediated endothelial progenitor cell mobilization and homing are reversed by hyperoxia and SDF-1 α . *J Clin Invest*. 2007 May 1;117(5):1249-59. [[CrossRef](#)]
- [26] Quattrini C, Jeziorska M, Boulton AJM, Malik RA. Reduced vascular endothelial growth factor expression and intra-epidermal nerve fiber loss in human diabetic neuropathy. *Diabetes Care*. 2008 Jan 1;31(1):140-5. [[CrossRef](#)]
- [27] Galiano RD, Tepper OM, Pelo CR, Bhatt KA, Callaghan M, Bastidas N, et al. Topical vascular endothelial growth factor accelerates diabetic wound healing through increased angiogenesis and by mobilizing and recruiting bone marrow-derived cells. *Am J Pathol*. 2004 Jun;164(6):1935-47. [[CrossRef](#)]
- [28] Kirchner LM, Meerbaum SO, Gruber BS, Knoll AK, Bulgrin J, Taylor RAJ, et al. Effects of vascular endothelial growth factor on wound closure rates in the genetically diabetic mouse model. *Wound Repair Regen*. 2003 Mar;11(2):127-31. [[CrossRef](#)]
- [29] Gonzalez AC de O, Costa TF, Andrade Z de A, Medrado ARAP. Wound healing - a literature review. *An Bras Dermatol*. 2016 Oct;91(5):614-20. [[CrossRef](#)]
- [30] Kandhare AD, Alam J, Patil MVK, Sinha A, Bodhankar SL. Wound healing potential of naringin ointment formulation via regulating the expression of inflammatory, apoptotic and growth mediators in experimental rats. *Pharm Biol*. 2016 Mar 3;54(3):419-32. [[CrossRef](#)]
- [31] Patel S, Srivastava S, Singh MR, Singh D. Mechanistic insight into diabetic wounds: pathogenesis, molecular targets and treatment strategies to pace wound healing. *Biomed Pharmacother*. 2019 Apr;112:108615. [[CrossRef](#)]
- [32] Wikler MA. Methods for dilution antimicrobial susceptibility tests for bacteria that grow aerobically: approved standard. *CLSI NCCLS*. 2006;26(2),15-35.

- [33] Karakaş N, Karadağ AE, Yılmaz R, Demirci F, Okur ME. In vitro cytotoxicity evaluation of marrubium vulgare l. methanol extract. J. Res. Pharm. 2019 Jul; 23(4):711–718. [\[CrossRef\]](#)
- [34] Okur ME, Ayla Ş, Karadağ AE, Çiçek Polat D, Demirci S, Seçkin İ. *Opuntia ficus indica* fruits ameliorate cisplatin-induced nephrotoxicity in mice. Biol. Pharm. Bull. 2020 May; 43(5):831–838. [\[CrossRef\]](#)
- [35] Blois MS. Antioxidant determinations by the use of a stable free radical. Nature. 1958 Apr;181(4617):1199–200. [\[CrossRef\]](#)
- [36] Re R, Pellegrini N, Proteggente A, Pannala A, Yang M, Rice-Evans C. Antioxidant activity applying an improved abts radical cation decolorization assay. Free Radic Biol Med. 1999 May;26(9–10):1231–7. [\[CrossRef\]](#)
- [37] Okur ME, Polat DC, Ozbek H, Yılmaz S, Yoltas A, Arslan R. Evaluation of the antidiabetic property of capparid ovata desf. var. palaestina zoh. extracts using in vivo and in vitro approaches. Endocr Metab Immune Disord - Drug Targets. 2018 Aug 28;18(5):489–501. [\[CrossRef\]](#)
- [38] Okur ME, Ayla Ş, Çiçek Polat D, Günel MY, Yoltaş A, Biçeroğlu Ö. Novel insight into wound healing properties of methanol extract of *capparid ovata* desf. var. *palaestina* zohary fruits. J Pharm Pharmacol. 2018 Sep 6;70(10):1401–13. [\[CrossRef\]](#)
- [39] Galeano M, Altavilla D, Bitto A, Minutoli L, Calò M, Cascio PL, et al. Recombinant human erythropoietin improves angiogenesis and wound healing in experimental burn wounds*. Crit Care Med. 2006 Apr;34(4):1139–46. [\[CrossRef\]](#)

Copyright of Journal of Research in Pharmacy is the property of Marmara University, Faculty of Pharmacy and its content may not be copied or emailed to multiple sites or posted to a listserv without the copyright holder's express written permission. However, users may print, download, or email articles for individual use.