

Atypical Multiple Cutaneous Ulcers in A Patient with Systemic Lupus Erythematosus Treated with Rituximab: Case Report

Ritüksimab Tedavisi Alan Sistemik Lupus Eritematozuslu Bir Hastada Çok Sayıda Atipik Kutanöz Ülserler

Pelin ÜSTÜNER,^a
Mustafa ÖZDEMİR,^a
Ali BALEVİ^a

^aDepartment of Dermatology,
İstanbul Medipol University
Faculty of Medicine, İstanbul

Geliş Tarihi/Received: 09.02.2015
Kabul Tarihi/Accepted: 11.06.2015

Yazışma Adresi/Correspondence:
Pelin ÜSTÜNER
İstanbul Medipol University
Faculty of Medicine,
Department of Dermatology, İstanbul,
TÜRKİYE/TURKEY
pelindogaustuner@gmail.com

ABSTRACT Intravenous rituximab therapy is an effective treatment alternative for systemic lupus erythematosus patients for whom standard therapies have not been effective. We report on a 20-year-old male with intractable systemic lupus erythematosus presenting with cutaneous ulcers that occurred two weeks after rituximab therapy. There were multiple painless ulcers on the patient's abdomen, inguinal and gluteal regions. The histopathological examination revealed ulceration comprising an inflammatory granulation tissue rich in polymorphonuclear leukocytes and eosinophils. The patient was prescribed 16 mg/day methylprednisolone for 3 weeks. One week later, he presented with multiple dyshidrotic vesicular lesions on the palmar surface of his hand and vesicular-ulcerative lesions on the distal pulp of his right thumb. After the discontinuation of the rituximab therapy, the ulcers partially improved using wound dressings. Cutaneous ulcers are very rarely seen in patients with lupus erythematosus and only few cases have been reported. Cutaneous ulceration due to the rituximab treatment has not yet been reported.

Key Words: Lupus erythematosus, systemic; rituximab; skin ulcer

ÖZET İntravenöz ritüksimab tedavisi standart tedavilerin etkili olmadığı sistemik lupus eritematozuslu hastalarda etkili bir tedavi alternatifidir. Ritüksimab tedavisinden hemen iki hafta sonra kutanöz ülserler ile prezente olan, tedaviye yanıtızs sistemik lupus eritematozuslu yirmi yaşında erkek hasta sunuldu. Hastanın karın, kasık ve gluteal bölgelerinde çok sayıda ağrısız ülserler vardı. Histopatolojik incelemede polimorfonükleer lökositler ve eozinofillerden zengin inflamatuvar granülasyon dokusu ve ülserasyon görüldü. Hastaya 16 mg/gün metilprednizolon tedavisi verildi. Bir hafta sonra, hasta elinin palmar yüzeyinde çok sayıda dishidrotik veziküler lezyonlar ve sağ el baş parmağının distal pulpasında vezikülo-ülseratif lezyonlar ile başvurdu. Ritüksimab tedavisinin kesilmesinin ardından ülserler yara örtüleri ile kısmen iyileşti. Lupus eritematozuslu hastalarda kutanöz ülserler oldukça nadir görülmektedir ve sadece birkaç olgu rapor edilmiştir. Ritüksimab tedavisine bağlı kutanöz ülserasyon şimdiye kadar bildirilmemiştir.

Anahtar Kelimeler: Lupus eritematozus, sistemik; ritüksimab; deri ülseri

Türkiye Klinikleri J Dermatol 2016;26(1):32-7

Systemic lupus erythematosus (SLE) is a clinically diverse and potentially life-threatening chronic inflammatory autoimmune disease that can affect almost any organ system, and has high morbidity if untreated.¹ Recently, in patients with this condition there has been an increase in life expectancy and quality of life with an estimated 5-year survival rate of 82%-90% of patients due to the development of modern treatments.¹ The clinical features of SLE develop through auto-antibody formation, immune

complex deposition and cytokine activation.² Although much is still unknown regarding the pathogenesis of SLE, B-cell abnormalities are considered to be central.³ High relapse rates and toxicity associated with conventional treatments point to the need for more focused approaches towards this very heterogeneous disease. In previous clinical studies, it was suggested that the B-cell depleting agent rituximab (RTX) could be a potent SLE treatment.³ However, two randomized controlled trials failed to meet the efficacy endpoints.^{4,5} In addition, cardiac, gastrointestinal, and heterogeneous neurological adverse effects have been reported as a result of the RTX treatment.⁶ Nevertheless, RTX has continued to be used as an off-label alternative mainly in patients refractory to conventional immunosuppressive treatments.³

CASE REPORT

A 20-year-old male was referred to our clinic presenting with multiple painless ulcers that had developed on his abdomen and on his inguinal and gluteal regions two weeks earlier. The SLE diagnosis was made based on the clinical and laboratory criteria developed by the American College of Rheumatology (ACR) in 2010. Despite receiving the recommended doses according to the protocols, the patient had refractory to the conventional SLE treatments; such as hydroxychloroquine, high dose steroids, cyclophosphamide, azathioprine, and mycophenolate mofetil. His current medication consisted of 4 mg/day oral methylprednisolone. He reported no previous trauma, friction, sexual contact or contact with chemical or erosive materials. He had suffered from the symptoms of Raynaud's disease for two years, with bilateral symmetric polyarteritis and arthralgia on his fingers otherwise his medical history was otherwise unremarkable. He had received intravenous RTX (MabThera®) 375 mg/m²/week in another clinic. The treatment scheme was based on the protocols used in patients with rheumatoid arthritis (RA) consisting of an initial dose of 1 g and 1 g after two weeks. Our patient had received two doses of intravenous RTX with no subsequent dose. His CD20+ cell counts were not known.

The dermatological examination revealed a deep ulcer of 2x2 cm covered by a serous-purulent exudate on the right lower quadrant of his abdomen (Figure 1a), a punched-out, painless deep ulcer of 0.5-1 cm on his right inguinal area and multiple ulcers on his medial bilateral gluteal areas (Figure 1b). There were also small superficial erythematous patches surrounding these deep ulcers. The contractions of his finger joints were noteworthy.

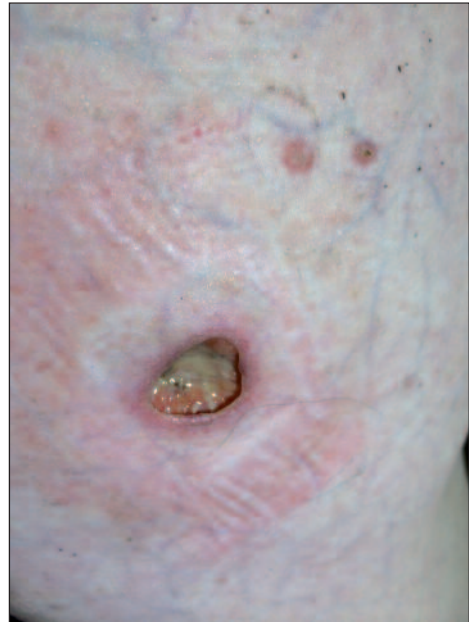

FIGURE 1a: A deep ulcer of 2x2 cm covered with a serous-purulent exudate on the right lower quadrant of the abdomen.

(See color figure at <http://www.turkiyeklinikleri.com/journal/dermatoloji-dergisi/1300-0330/>)

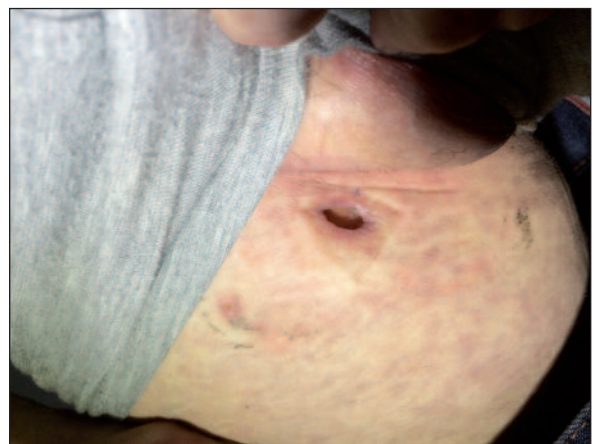

FIGURE 1b: Multiple ulcers on the medial bilateral gluteal areas.

(See color figure at <http://www.turkiyeklinikleri.com/journal/dermatoloji-dergisi/1300-0330/>)

The overall result of the laboratory examination was unremarkable except for the leukopenia, chronic anaemia and ANA positivity in 1/32 titres. Anti-phospholipids (aPL) antibodies, cytoplasmic anti-neutrophil cytoplasmic antibodies (c-ANCA), perinuclear anti-neutrophil cytoplasmic antibodies (p-ANCA) and anti-ds DNA were negative. The VDRL test was negative. Serum Immunoglobulin (Ig) M and G levels were normal. One week after the first visit, the patient returned to the clinic due to the occurrence of multiple dyshidrotic vesicular lesions on the palmar surface of his hands (Figure 1c) and vesicular-ulcerative lesions on the distal pulp of his right thumb (Figure 1d). We also noted a recent millimetric pinpoint ulcer with an erythematous sharp border on the dorsum of his right hand. The differential diagnosis included possible cutaneous tuberculosis, ecthyma gangrenosum, cutaneous vasculitis, aPL antibody syndrome, pyoderma gangrenosum and drug induced ulcers. The patient's written informed consent was obtained for publication. The histopathological examination of the punch biopsy material taken from his abdominal ulcer revealed

ulceration, consisting of an inflammatory granulation tissue rich in polymorphic eosinophilic leukocytes (H-E x200) (Figure 2). The direct immunofluorescence test was negative. The polymerase chain reaction (PCR) examinations of the wound scrubs for cytomegalovirus (CMV), DNA and herpes simplex virus (HSV) Type I and Type II DNA were all negative. CMV Ig M, Ig G and HSV Type I and II Ig M and G were also negative.

After the discontinuation of the RTX therapy, the methylprednisolone dose was increased to 16 mg/day. Prontosan Wound Gel X[®], a sterile, highly viscous hydrogel, was prescribed to treat the deep ulcer on the patient's abdomen and Ag Granuflex[®] hydrocolloid wound dressings were also prescribed for the remaining ulcers. One month later, the ulcers had partially healed (Figure 3); therefore, the methylprednisolone dose was gradually reduced to 4 mg/day. After six months of follow-up, he had no further cutaneous ulcers. The patient was called for a follow-up after a year; unfortunately we were informed that he had died in another hospital following gastrointestinal bleeding.

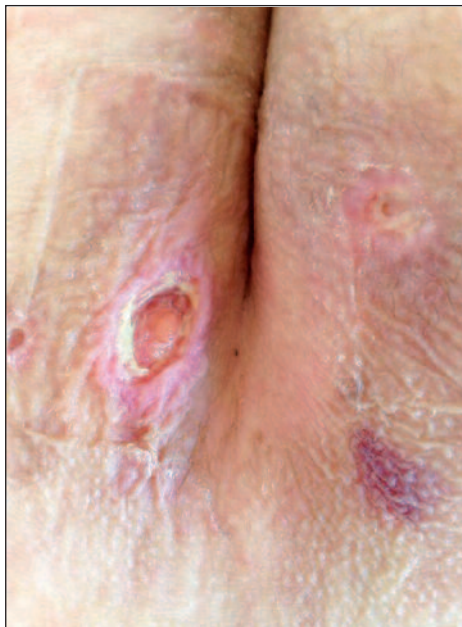

FIGURE 1c: Multiple dyshidrotic vesicular lesions on the palmar surface of the hands.

(See color figure at <http://www.turkiyeklinikleri.com/journal/dermatoloji-dergisi/1300-0330/>)

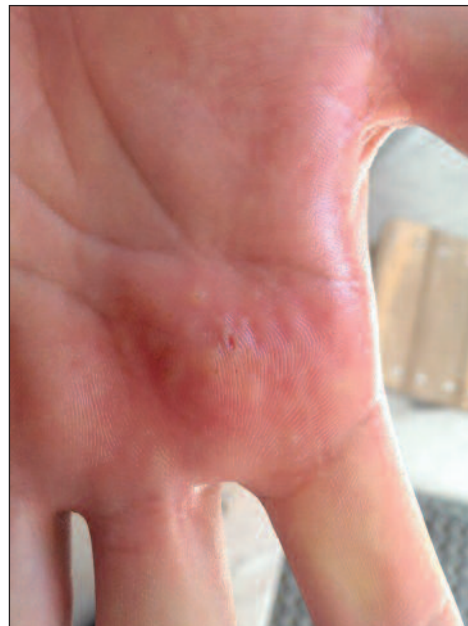

FIGURE 1d: Vesicular-ulcerative lesions on the distal pulp of the right thumb.

(See color figure at <http://www.turkiyeklinikleri.com/journal/dermatoloji-dergisi/1300-0330/>)

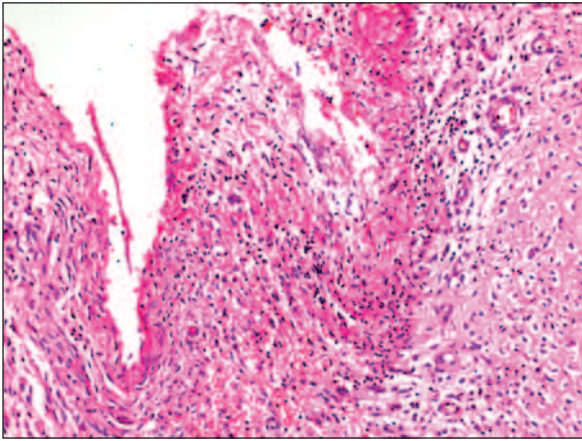


FIGURE 2: Ulceration, inflammatory granulation tissue rich in polymorphonuclear leukocytes and eosinophils (H-E x200).

(See color figure at <http://www.turkiyeklinikleri.com/journal/dermatoloji-dergisi/1300-0330/>)

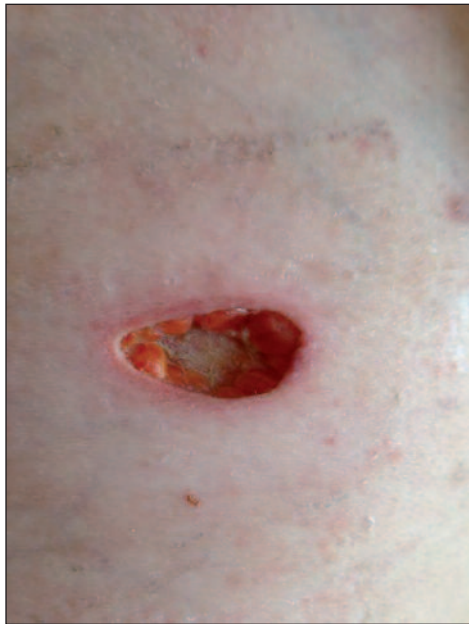

FIGURE 3: The partially healing ulcer one month after therapy..

(See color figure at <http://www.turkiyeklinikleri.com/journal/dermatoloji-dergisi/1300-0330/>)

DISCUSSION

The causes of cutaneous ulcers seen in SLE are variable. Leg ulceration is a rare skin manifestation affecting approximately 5.6% of SLE patients and it is mostly associated with aPL antibodies or leukocytoclastic vasculitis.⁶ Therefore, it has been suggested that aPL antibodies can play a pathogenetic

role in ulcerated skin manifestations of aPL-positive SLE patients. However, in the current case the aPL antibodies were negative. SLE has also been found to be associated with pyoderma gangrenosum (PG) in more than 16 reported cases. It has also been suggested that a predisposition to vascular thrombosis or inflammation in SLE can have a role in PG pathogenesis.⁷ In another study, the prevalence of avascular necrosis was found to be 6% in an SLE study group.⁸ Intractable ulceration has been reported in a patient with lupus erythematosus profundus (LEP) that had been successfully treated with cyclosporine.⁹ Fat necrosis was reported in 20 of 29 LEP cases, 3 thrombosis in cases with histologically severe lupus panniculitis, and vasculitis in some cases of LEP.^{9,10}

Rituximab, also known as a TNF- α inhibitor, is an anti-neoplastic, immunomodulatory and biologic drug that has been approved and is most commonly used in intractable adult RA, psoriatic arthritis, systemic vasculitis anti-neutrophil cytoplasmic antibodies (ANCA), and positive and non-Hodgkin lymphoma.^{2,7} RTX is an anti-CD20 human-murine monoclonal chimeric antibody that causes the selective short-term depletion of matured B-cells through three mechanisms; induction of apoptosis (programmed cell death), complement-dependent cytotoxicity and anti-body dependent cytotoxicity.^{2,11,12}

To date, over 540,000 patients worldwide, have received RTX; with only a small minority reporting serious adverse reactions, and for the great majority of patients, RTX has been reported to be safe and well-tolerated.¹³ However, it has also been suggested that RTX can only be recommended for organ-specific manifestations of SLE, such as arthritis and autoimmune thrombocytopenic purpura and thrombocytopenia.¹⁴⁻¹⁶ The incidence of serious infections has been estimated to be 6.6/100-12.6/100 patient-years. The most common side effects associated with RTX include; mild infusion reactions (35%), neutropenia and infections (10%).^{2,17} Certain cutaneous adverse effects of RTX, such as easy bruising, or bleeding, petechial lesions, painful oral ulcers, redness, blistering, scaly, itchy, or peeling skin have been reported 24 hours after

the infusion.^{4,18,19} These adverse effects can persist for a few weeks or months even if RTX is discontinued. So far cutaneous deep ulcers due to RTX treatment have not been reported. Even though RTX has been successfully used in the treatment of cutaneous ulcerations in diseases, such as refractory cases with LEP, polyarteritis nodosa, polymyositis/dermatomyositis and ANCA-associated vasculitis, the etiological association of rituximab with these ulcers is still unclear and controversial.²⁰⁻²² Therefore, we suggest that these atypical ulcers could be a rare mysterious clinical sign of SLE. We think that the cutaneous ulcers reported in the patient in the current paper may also have occurred as a result of necrobiotic changes in the subcutaneous tissue caused by vascular changes.

In this case, the diagnosis was made according to the clinical setting, the absence of an alternative diagnosis and the partial clinical improvement of the lesion after the initiation of the specific treatment. An ulcer biopsy was also performed to eliminate other conditions presenting with cutaneous ulcers, as follows; malignancy, infections such as sporotrichosis, cutaneous tuberculosis, ecthyma gangrenosum, syphilitic ulceration, amebiasis, HSV Type 2 virus, CMV infection, cutaneous vasculitis, aPL antibody syndrome, avascular necrosis or PG.⁷ Vasculitic diseases such as granulomatosis with polyangiitis, polyarteritis nodosa, mixed cryoglobulinemia, Takayasu's arteritis, leukocytoclastic vasculitis, livedoid vasculopathy. Since the histopathological examination revealed no nuclear atypia or abnormal mitosis, cutaneous malignancies such as squamous cell carcinoma were eliminated. "Lupus profundus is a form of lobular panniculitis characterized by subcutaneous nodules and plaques particularly appearing on the face, trunk and upper proximal extremities."²³ Due to the

absence of typical histopathological findings of lupus profundus such as hyaline necrosis in the lobules of subcutaneous fat tissue, lobular panniculitis accompanied by lymphoplasmocytic infiltration the diagnosis of lupus profundus was quickly eliminated in this case.²³ Besides the negative results obtained from the direct immunofluorescence and lupus band tests also excluded lupus profundus." Furthermore, in our patient the viral markers were all negative, which made it possible to distinguish between the ulcers and herpes according to their clinical features and laboratory results. The ulcers seen in this case also had no symptoms of infection, such as pain, erythema or a local increase in temperature. Moreover, tissue cultures were all negative. The negativity of VDRL, aPL antibody, c-ANCA and p-ANCA tests excluded syphilitic ulcerations and other possible vasculitic diseases from the differential diagnosis. The gastrointestinal bleeding that led to the death of the patient in this case might have been due to either vasculitis that is commonly seen in SLE pathophysiology or the thrombosis of the mesenteric arteries.

In conclusion, RTX has been reported to be an effective treatment alternative for the induction and maintenance of remission in patients with SLE refractory to conventional treatments, particularly in terms of the disease activity, immunologic parameters and steroid-sparing effect. However, we suggest that more high-quality and long-term studies are needed to determine the effect of re-treatment and long-term efficacy and safety of the RTX treatment and reveal the exact cause of atypical ulcerations. We chose to present this case since it is rarely seen. For further research, RTX treatment or other biologic agents should be investigated in SLE patients presenting with cutaneous atypical ulcers without any known etiology.

REFERENCES

- Bonilla-Abadía F, Coronel Restrepo N, Tobón GJ, Echeverri AF, Muñoz-Buitrón E, Castro AM, et al. Rituximab for remission induction and maintenance in refractory systemic lupus erythematosus. *Autoimmune Dis* 2014;2014: 731806.
- Kamal A, Khamashta M. The efficacy of novel B cell biologics as the future of SLE treatment: a review. *Autoimmun Rev* 2014;13(11):1094-101.
- Ekö SL, van Vollenhoven RF. Rituximab and lupus--a promising pair? *Curr Rheumatol Rep* 2014;16(9):444.
- Merrill JT, Neuwelt CM, Wallace DJ, Shahanan JC, Latinis KM, Oates JC, et al. Efficacy and safety of rituximab in moderately-to-severely active systemic lupus erythematosus: the randomized, double-blind, phase II/III systemic lupus erythematosus evaluation of rituximab trial. *Arthritis Rheum* 2010;62(1): 222-33.
- Rovin BH, Furie R, Latinis K, Looney RJ, Ferrenza FC, Sanchez-Guerrero J, et al; LUNAR Investigator Group. Efficacy and safety of rituximab in patients with active proliferative lupus nephritis: the Lupus Nephritis Assessment with Rituximab Study. *Arthritis Rheum* 2012;64(4):1215-26.
- Díaz-Lagares C, Pérez-Alvarez R, García-Hernández FJ, Ayala-Gutiérrez MM, Callejas JL, Martínez-Berriotxo A, et al; BIOGEAS Study Group. Rates of, and risk factors for, severe infections in patients with systemic autoimmune diseases receiving biological agents off-label. *Arthritis Res Ther* 2011; 13(4):R112.
- González-Moreno J, Ruiz-Ruigomez M, Callejas Rubio J, Ríos Fernández R, Ortego Centeno N. Pyoderma gangrenosum and systemic lupus erythematosus: a report of five cases and review of the literature. *Lupus* 2015; 24(2):130-7.
- Sayarlioglu M, Yuzbasioglu N, Inanc M, Kamali S, Cefle A, Karaman O, et al. Risk factors for avascular bone necrosis in patients with systemic lupus erythematosus. *Rheumatol Int* 2012;32(1):177-82.
- Ishiguro N, Iwasaki T, Kawashima M, Kawakami M. Intractable ulceration in a patient with lupus erythematosus profundus successfully treated with cyclosporine. *Int J Dermatol* 2012;51(9):1131-3.
- Park HS, Choi JW, Kim BK, Cho KH. Lupus erythematosus panniculitis: clinicopathological, immunophenotypic, and molecular studies. *Am J Dermatopathol* 2010;32(1):24-30.
- Bezalel S, Asher I, Elbirt D, Stoecker ZM. Novel biological treatments for systemic lupus erythematosus: current and future modalities. *Isr Med Assoc J* 2012;14(8):508-14.
- Chan VS, Tsang HH, Tam RC, Lu L, Lau CS. B-cell-targeted therapies in systemic lupus erythematosus. *Cell Mol Immunol* 2013;10(2): 133-42.
- Rajadhyaksha AG, Mehra S, Nadkar MY. Biologics in SLE: the current status. *J Assoc Physicians India* 2013;61(4):262-7.
- Kimby E. Tolerability and safety of rituximab (MabThera). *Cancer Treat Rev* 2005;31(6): 456-73.
- Dale RC, Brilot F, Duffy LV, Twilt M, Waldman AT, Narula S, et al. Utility and safety of rituximab in pediatric autoimmune and inflammatory CNS disease. *Neurology* 2014;83(2): 142-50.
- Cobo-Ibáñez T, Loza-Santamaría E, Pego-Reigosa JM, Marqués AO, Rúa-Figueroa I, Fernández-Nebro A, et al. Efficacy and safety of rituximab in the treatment of non-renal systemic lupus erythematosus: a systematic review. *Semin Arthritis Rheum* 2014;44(2): 175-85.
- Murdaca G, Colombo BM, Puppo F. Emerging biological drugs: a new therapeutic approach for Systemic Lupus Erythematosus. An update upon efficacy and adverse events. *Autoimmun Rev* 2011;11(1):56-60.
- Chen H, Zheng W, Su J, Xu D, Wang Q, Leng X, et al. Low-dose rituximab therapy for refractory thrombocytopenia in patients with systemic lupus erythematosus-a prospective pilot study. *Rheumatology (Oxford)* 2011;50(9): 1640-4.
- Albert D, Dunham J, Khan S, Stansberry J, Kolasinski S, Tsai D, et al. Variability in the biological response to anti-CD20 B cell depletion in systemic lupus erythematosus. *Ann Rheum Dis* 2008;67(12):1724-31.
- Espírito Santo J, Gomes MF, Gomes MJ, Peixoto L, C Pereira S, Acabado A, et al. Intravenous immunoglobulin in lupus panniculitis. *Clin Rev Allergy Immunol* 2010;38(2-3): 307-18.
- McArdle A, Baker JF. A case of "refractory" lupus erythematosus profundus responsive to rituximab [case report]. *Clin Rheumatol* 2009; 28(6):745-6.
- Unger L, Kampf S, Lütke K, Aringer M. Rituximab therapy in patients with refractory dermatomyositis or polymyositis: differential effects in a real-life population. *Rheumatology (Oxford)* 2014;53(9):1630-8.
- Bologna JL, Jorizzo JL, Schaffer JV. *Dermatology*. 3rd ed. Philadelphia: Elsevier Saunders; 2012. p.1653.