

# Evaluation of Radiopaque Jaw Lesions in a Turkish Population: A Retrospective Study

## Türk Toplumunda Radyopak Çene Lezyonlarının Değerlendirilmesi: Retrospektif Bir Çalışma

✉ Dursun Ali Şirin<sup>1</sup>, ✉ Celalettin Topbaş<sup>1</sup>, ✉ Şeyda Erşahan<sup>2</sup>, ✉ Yelda Erdem Hepşenoğlu<sup>2</sup>

<sup>1</sup>Istanbul Medipol University Faculty of Dentistry, Department of Endodontics, İstanbul, Turkey

<sup>2</sup>University of Health Sciences Turkey, Hamidiye Faculty of Dentistry, Department of Endodontics, İstanbul, Turkey

### ABSTRACT

**Background:** Radiopaque lesions are frequently found in the periapical region. The diagnosis and treatment of these lesions can be challenging to the dentist. The present study presents the similar radiographic features of the lesions to help the clinician narrow the differential diagnosis and to aid in treatment planning. This study aims to evaluate the frequency and distribution of radiopaque lesions in a Turkish population.

**Materials and Methods:** This retrospective study was conducted at the Department of Endodontics, Hamidiye Faculty of Dentistry, University of Health Sciences Turkey, İstanbul, Turkey. Data was obtained from digital panoramic images taken between 2018-2021. A total of 2.002 patients were included. The incidence of specific radiopaque lesions, like idiopathic osteosclerosis, condensing osteitis, odontoma, cementoblastoma, cementoosseous dysplasia, and fibrous dysplasia was evaluated with relation to gender. In addition to these, the frequency of pulp stones was also evaluated. Descriptive statistics and the chi-square test were used to evaluate the data.

**Results:** Of the 1.912 patients diagnosed with radiopaque lesions, 960 (50.2%) were female and 952 (49.8%) were male. Radiopaque lesions were determined on 106 (5.5%) panoramic radiographs. While idiopathic osteosclerosis was found in 58 (3%), condensing osteitis was found in 33 (1.7%), odontoma was found in 1 (0.1%), cementoblastoma was found in 1 (0.1%), cemento-osseous dysplasia was found in 10 (0.5%) and fibrous dysplasia was found in 3 (0.2%) patients. Moreover, a pulp stone was found in 142 (7.4%) patients. No statistically significant difference was found between genders in any of the lesions ( $p>0.05$ ), except for condensing osteitis ( $\chi^2=0.024$ ).

**Conclusion:** The most common radiopaque lesions in the study were idiopathic osteosclerosis and condensing osteitis, while the least common was cementoblastoma and odontoma.

**Keywords:** Jaw, radiopaque lesions, radiographic images

### ÖZ

**Amaç:** Periapikal bölgede radyopak lezyonlar sıklıkla bulunmaktadır. Bu lezyonların teşhisi ve tedavisi diş hekimi için zorlayıcı olabilir. Bu lezyonlar benzer görüntüleme özelliklerine sahip olabilir ve bu çalışmada klinisyenin ayırıcı tanısı daraltmasına ve hasta tedavisini planlamasına yardımcı olmak için temel radyografik özellikler sunulmaktadır. Bu çalışmada, Türk popülasyonunda radyopak lezyonlarının sıklığı ve dağılımının incelenmesi amaçlandı.

**Gereç ve Yöntemler:** Radyopak çene lezyonlarının bu retrospektif çalışması Türkiye'de Sağlık Bilimleri Üniversitesi, Hamidiye Diş Hekimliği Fakültesi Endodonti Anabilim Dalı'nda yapılmıştır. Veriler 2018'den 2021'e kadar dijital panoramik radyografi görüntülerinden alınmıştır. Toplam 2002 hasta dahil edilmiştir. Bu çalışmada cinsiyete ek olarak idiyopatik osteoskleroz, kondensan osteitis, odontoma, sementoblastoma, semento-osseöz displazi ve fibröz displazi gibi radyopak lezyonların görülme sıklığı değerlendirildi. Bunlara ek olarak pulpa taşı sıklığı da değerlendirildi. Verilerin değerlendirilmesinde tanımlayıcı istatistikler ve ki-kare testi kullanıldı.

**Bulgular:** Radyopak lezyon tanısı alan 1,912 hastanın 960'ı (%50,2) kadın, 952'si (%49,8) erkekti. Yüz altı (%5,5) panoramik radyografide radyopak lezyonlar tespit edildi. Elli sekizinde (%3) idiyopatik osteoskleroz, 33'ünde kondensan osteitis (%1,7), 1'inde



**Address for Correspondence:** Şeyda Erşahan, University of Health Sciences Turkey, Hamidiye Faculty of Dentistry, Department of Endodontics, İstanbul, Turkey

Phone: +90 532 405 40 88 E-mail: seydaersahan@hotmail.com **ORCID ID:** orcid.org/0000-0002-0354-5108

**Received:** 30.12.2021 **Accepted:** 11.01.2022

## ÖZ

odontoma (%0,1), 1'inde sementoblastoma (%0,1), 10'unda sementoossez displazisi (%0,5) ve 3'ünde fibröz displazi (%0,2) bulundu. Dahası 142'sinde pulpa taşı (%7,4) bulundu. Kondensing osteitis ( $X^2=0,024$ ) dışında hiçbir lezyonda cinsiyetler arasında istatistiksel olarak anlamlı fark bulunmadı ( $p>0,05$ ).

**Sonuç:** Çalışmada en sık radyopak lezyonlar idiyopatik osteoskleroz ve kondens osteitis iken en az görüleni sementoblastoma ve odontoma idi.

**Anahtar Kelimeler:** Çene, radyopak lezyonlar, radyografik görüntüler

## Introduction

Numerous radiopaque and radiolucent lesions are seen in the jaws. An accurate diagnosis is mandatory for correct treatments of dental infections (1). Granulomas, radicular cysts and periapical abscesses are the most common radiolucent lesions that are seen during radiographic examination (1). On the other hand, radiopaque lesions are observed around the apex of the teeth, too and their correct diagnosis is important, as they can be of odontogenic or non-odontogenic origin (2).

Numerous previous studies (3), including studies from Turkey (4), have investigated the frequency of radiolucent lesions. Although the epidemiological profile of radiopaque lesions has been investigated in different populations in the past, few studies have examined such lesions in Turkey (5,6,7). Although the incidence of radiopaque lesions in the jawbone is less than radiolucent lesions (8,9); investigating the epidemiological data of these lesions is very important in the correct diagnosis. Such studies could help the clinician carry out a differential diagnosis for these lesions. Since the geographical distribution may cause differences, there is a need to examine this issue in our country. Therefore, the aim of the present study was to retrospectively investigate the incidence of radiopaque lesions in a Turkish population by using panoramic radiography.

## Materials and Methods

This retrospective study was conducted by evaluating 1.912 randomly selected digital panoramic radiographic images of patients who came to University of Health Sciences Turkey, Hamidiye Faculty of Dentistry, Department of Endodontics between 2019-2021. Nine-hundred sixty radiographs belonged to females and 952 to male subjects (female:male ratio 1:1). Male and female patients aged 18-65 years were included in the study. The study sample consisted Turkish patients with permanent dentition. Any radiographs with primary or mixed dentition were excluded. This study is approved by the Institutional Review Board of University of Health Sciences Turkey (E-46418926-050.99-89060). As this study is a retrospective study, written consent was

not obtained from the participants. Images were obtained by using Orthopantomograph OP200 D (Instrumentarium Dental, Tuusula, Finland), operating at 70 kVp and 4.9 mA with 14.1 s exposure time in standard mode. Digital panoramic images were evaluated at different times by a researcher with five years of experience in digital panoramic image evaluation. In this study, the presence of radiopaque lesions on panoramic radiographs was evaluated retrospectively. Among these lesions, idiopathic osteosclerosis, condensing osteitis, odontoma, cementoblastoma, cementoosseous dysplasia and fibrous dysplasia (FD) were evaluated. Other lesions were not included in the study. In this study, the relationship between the presence of radiopaque lesions and gender was also investigated.

## Statistical Analysis

All statistical analyses were performed using the SPSS 27.0 statistical software (SPSS Inc., IL, USA). Frequency and percentage were used for descriptive statistics. The chi-square test was used to compare the qualitative data. The result was considered statistically significant when the p-value was  $<0.05$ .

## Results

Of the 1.912 patients included in the study, 960 (50.2%) were female and 952 (49.8%) were male.

In this study, radiopaque lesions were found in 106 (5.5%) of 1912 patients. Sixty-four (3.3%) of these lesions were found in women and 42 (2.1%) were found in men. Idiopathic osteosclerosis (Figure 1a) was seen in a total of 58 (3.0%) patients, 30 (3.1%) female and 28 (2.9%) male (Table 1). There was no difference between men and women in terms of idiopathic osteosclerosis ( $p>0.05$ ) (Table 1).

Cementoosseous dysplasia (Figure 1b) was seen in 10 (0.5%) patients; 8 (0.8%) female and 2 (0.2%) male. There was no statistical difference between men and women in terms of cementoosseous dysplasia ( $p>0.05$ ) (Graphic 1 and Table 1). Odontoma (Figure 1c) was found in 1 male patient (0.1%) and cementoblastoma in 1 female patient (0.1%). There was no difference between men and women in terms of odontoma ( $p>0.05$ ) (Graphic 1 and Table 1).

Moreover, a pulp stone (Figure 1c) was found in 142 (7.4%) patients. No statistically significant difference was found between genders.

Condensing osteitis was seen in 33 (1.7%) patients, 23 (2.4%) female and 10 (1.1%) male (Figure 1d). Condensing osteitis lesions were found to be higher in women compared to men ( $p < 0.05$ ) (Graphic 1 and Table 1).

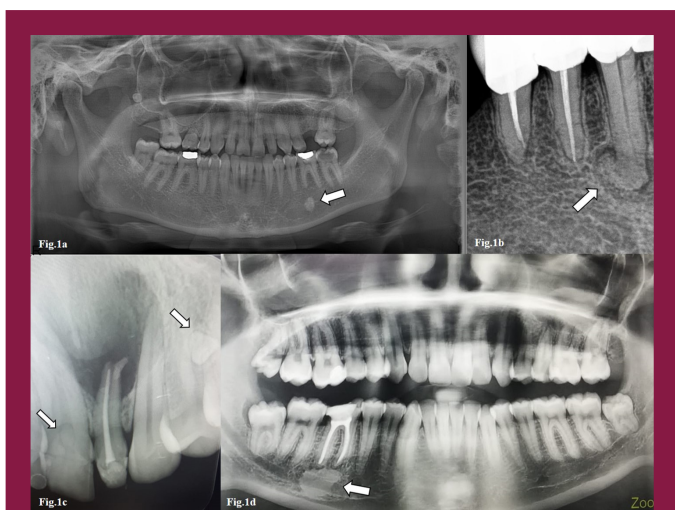
Cementoblastoma was seen in 1 (0.05%) patient; 1 (0.1) female and 0 (0.1%) male. There was no statistical difference between men and women in terms of cementoblastoma ( $p > 0.05$ ) (Graphic 1 and Table 1).

FD was seen in 3 (0.2%) patients; 2 (0.2%) female and 1 (0.1%) male (Graphic 1). There was also no statistical difference between men and women in terms of FD ( $p > 0.05$ ) (Graphic 1 and Table 1). It was remarkable that there was no statistically significant difference in the incidence of radiopaque lesions between the genders, except for condensing osteitis ( $p > 0.05$ ).

## Discussion

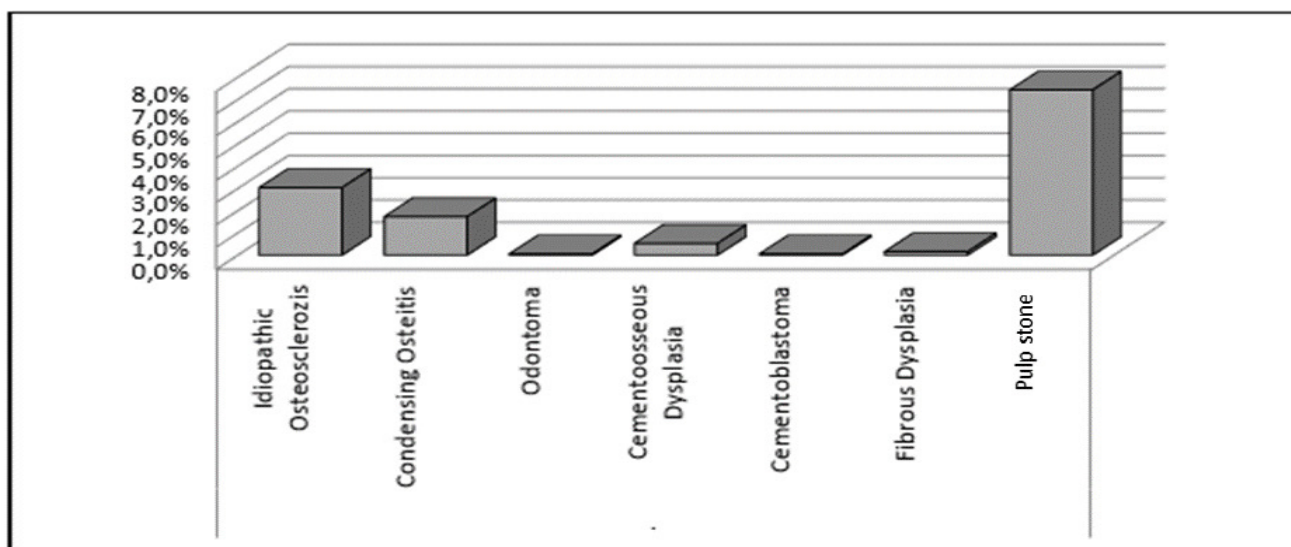
This retrospective study found the prevalence of radiopaque jaw lesions in a Turkish population to be 5.5%. This value is in the same range with the literature, which is between 2% and 9.7% (8,9,10,11).

The present study demonstrated that idiopathic osteosclerosis was the most common radiopaque lesion in the Turkish population. Idiopathic osteosclerosis is a term used to describe a highly dense area of bone that is not associated with an inflammatory, neoplastic or systemic disease. They do not have any obvious etiological agents (12). They are usually asymptomatic, they do not cause cortical expansion, and they are detected incidentally on routine radiographs (13,14). The frequency of idiopathic osteosclerosis (3%) in this investigation falls within the range found by other studies, which vary from 1.96 to 7.6% (12,13,15,16). Although Miloglu et al. (16) and Avramidou et al. (15) found that the incidence of idiopathic osteosclerosis was higher in women, Williams and Brooks (13), Halse and Molven (12) and Dedeoğlu and Arıkan (17) did not find any differences between the genders in their study. In our study, no statistical difference was found between the genders.



**Figure 1.** A composite figure of commonly seen radiopaque lesions is given in Figure 1. Fig.1a) An example of idiopathic osteosclerosis; Fig.1b) An example of cementoosseous dysplasia; Fig.1c) An example of odontoma and pulp stone; Fig.1d) An example of condensing osteitis

**Graphic 1.** The distribution of radiopaque jaw lesions in a Turkish population



**Table 1. The distribution of subgroups of radiopaque lesions according to gender**

		Female		Male		p	
		n	%	n	%		
<b>Idiopathic osteosclerosis</b>	(-)	930	96.9%	924	97.1%	0.815	X <sup>2</sup>
	(+)	30	3.1%	28	2.9%		
<b>Condensing osteitis</b>	(-)	937	97.6%	942	98.9%	<b>0.024</b>	X <sup>2</sup>
	(+)	23	2.4%	10	1.1%		
<b>Odontoma</b>	(-)	960	100.0%	951	99.9%	0.498	X <sup>2</sup>
	(+)	0	0.0%	1	0.1%		
<b>Cementoosseous dysplasia</b>	(-)	952	99.2%	950	99.8%	0.059	X <sup>2</sup>
	(+)	8	0.8%	2	0.2%		
<b>Cementoblastoma</b>	(-)	959	99.9%	952	100.0%	1.000	X <sup>2</sup>
	(+)	1	0.1%	0	0.0%		
<b>Fibrous dysplasia</b>	(-)	958	99.8%	951	99.9%	1.000	X <sup>2</sup>
	(+)	2	0.2%	1	0.1%		
<b>Pulp stone</b>	(-)	886	92.3%	884	92.9%	0.637	X <sup>2</sup>
	(+)	74	7.7%	68	7.1%		

X<sup>2</sup>: Chi-square test (Fischer's Exact)

There is no apparent need for any intervention in idiopathic osteosclerosis (12).

The second most common lesion in the present study was condensing osteitis. They are focal sclerotic lesions that develop at the root apex due to low-grade chronic apical infection in teeth with a nonvital pulp (13,18). There are many factors in the etiology of condensing osteitis such as deep caries, extensive restorations, inadequate root canal treatments, orthodontic forces, dental eruption, and fixed prostheses (19). It appears as a well-defined dense radiopaque halo around the apices of a nonvital tooth. The incidence of condensing osteitis was found between 4-8% in studies conducted (17,19,20). The prevalence of condensing osteitis was found 1.7% in this study, in line with the previous studies. Although Williams and Brooks (13), Halse and Molven (12) and Verzak et al. (21) did not find any differences between the genders in their study, Miloglu et al. (16) found that the incidence of condensing was higher in women. Similarly, a significant difference was found between the genders in the present study. Root canal treatment or extraction has been recommended for the tooth with this lesion (22). After endodontic treatment the sclerotic area usually returns to normal bone density in nearly 70% of cases, however changes to the alveolar bone may still remain visible on radiographs even after extraction of the associated tooth (22).

Cemento-osseous dysplasia is a lesion of unknown origin, consisting of the periodontal ligament and cement or cement-like tissues in the areas of the jaw bones with

tooth roots (23). The lesions occur periapically in vital teeth, which distinguishes them from condensing osteitis. These lesions can be seen as radiolucency, mixed, and radiopaque on radiographs, according to its stages. The radiolucent lesions seem like periapical infections; but, the tooth is vital. The mixed and radiopaque lesions have a well-defined radiolucent rim around the radiopaque areas (24). At this stage, the clinician must be careful not to make a misdiagnosis (25). Diagnosis is often difficult, and clinical and histological examinations may be required for accurate diagnosis. Taking a biopsy of cemento-osseous dysplasia lesions is contraindicated as the avascular cemental masses are susceptible to osteomyelitis (24). The prevalence of cemento-osseous dysplasia is between 0.24% and 5.9% (25,26). One study found that cemento-osseous lesions were seen more often in women (27). The incidence of cemento-osseous lesion was found as 0.5% in this study. Similarly, it was observed with a higher incidence in women, although not significant. No treatment is required and only periodic examination by radiographs are enough. Biopsy, extraction, periodontal surgery, and implant surgery are contraindicated due to the increased risk of osteomyelitis (24).

FD is a benign disease characterized by the replacement of normal bone by abnormally mineralized fibrous tissue. FDs appear radiolucent in the early period, while they appear radiopaque and typically as ground glass in the later period (23). In FD, which is known to be continuous with the surrounding bone, the margins are not clear, and they expand (28). In two previous studies, the incidence of FD

was found to be 1.87% and 0.09, respectively (17,29). In our study, the incidence was found as 0.2%. The management of FD is conservative. Lesions not causing deformity can be followed. Treatment is necessary only for problems caused by a local increase in the size of the bone. Partial resections can be performed for lesions involving large and multiple bones and deformities (30).

Odontomas are very common benign odontogenic tumors. The lesion includes abnormally developed dentin and enamel components. Trauma, infection, hereditary anomalies, and odontoblastic alterations can be responsible for the etiology of odontomas. They usually appear as small or multiple radiopaque lesions on panoramic radiographs. Odontomas are generally asymptomatic, but they can cause the delay of the eruption of a tooth or tooth retention. The incidence of odontoma is accepted to be between 0.14-0.8% (31). In our study, the incidence of odontoma was found to be 0.1%. Although the growth of odontomas is limited, they need to be surgically removed because of their potential of bone collapse, problems with permanent tooth eruption, and their cystic nature (32).

Cementoblastoma is a rare benign odontogenic tumor. Clinically, it presents with pain and swelling of the buccal and lingual alveolar processes. Teeth are usually vital (33). It can be seen as a round radiopaque mass surrounded by a radiolucent rim on radiographs. Sometimes, root resorption and tooth displacement can be seen with this lesion (33). Prevalence of cementoblastoma was found in 0.1% of patients in the current study. If diagnosed in the early period, root canal treatment and apical resection are sufficient for treatment, while extraction may be considered in advanced cases (34).

Pulp stones are a form of pulp calcifications. But, the etiology of pulp stones is not clear. Pulp irritations such as long-term mastication forces, occlusal trauma, bruxism, periodontal pathology, orthodontic forces, and chronic pulp inflammation can be accounted for in the etiology (35). According to a systematic review, the frequency of pulp stones is about 36.5% (36), however its frequency in the Turkish population was found to be 7.4%. This difference can be explained largely by the differences between methodologies. In that previous study, only molar teeth were assessed. However, in the present study, all teeth including anteriors, premolars, and molars were evaluated. Pulp stones might be a challenge during root canal treatment and may obliterate the entrance of the canals.

### Study Limitations

These results should be evaluated with caution due to the sample limitations. As the study sample was only contains the patients attending Health Sciences University, results

regarding the frequency of radiopaque lesions cannot be extrapolated to the general Turkish population. Panoramic radiographs were evaluated in the present study. Due to its three-dimensional nature, CBCT has advantages over two-dimensional panoramic imaging. Since radiographs convert 3-D information into a 2-D image, lesion margins and extent cannot be rightly evaluated. Further CBCT imaging is required to assess the detailed morphological characteristics of the lesion.

### Conclusion

This study showed that the prevalence of radiopacities in a Turkish population are relatively rare, occurring in 5.5% of the population. This study also demonstrated that idiopathic osteosclerosis and condensing osteitis were the most commonly seen radiopaque lesions in the Turkish population.

### Ethics

**Ethics Committee Approval:** Approval for the study was granted by the Ethics Committee of the University of Health Sciences Turkey, Scientific Research (E-46418926-050.99-89060).

**Informed Consent:** As this study is a retrospective study, written consent was not obtained from the participants.

**Peer-review:** Externally peer-reviewed.

### Authorship Contributions

Surgical and Medical Practices: D.A.Ş., C.T., Concept: D.A.Ş., C.T., Ş.E., Y.E.H., Design: D.A.Ş., C.T., Ş.E., Y.E.H., Data Collection or Processing: D.A.Ş., C.T., Analysis or Interpretation: Ş.E., Y.E.H., Literature Search: Ş.E., Y.E.H., Writing: D.A.Ş., C.T., Ş.E., Y.E.H.

**Conflict of Interest:** No conflict of interest was declared by the authors.

**Financial Disclosure:** The authors declared that this study received no financial support.

### References

1. Neville BW, Damm DD, Allen CM, Chi AC. Oral and maxillofacial pathology. 4th ed. St. Louis: Elsevier; 2016. [Crossref]
2. Bueno MR, De Carvalho AA, Castro PHS, Pereira KC, Borges FT, Estrela C. Mesenchymal chondrosarcoma mimicking apical periodontitis. J Endod. 2008;34:1415-1419. [Crossref]
3. MacDonald D. Lesions of the jaws presenting as radiolucencies on cone-beam CT. Clin Radiol. 2016;71:972-985. [Crossref]
4. Karabas HC, Ozcan I, Tekkesin MS, Tasyapan SA, Guray B, Atapek MM. Evaluation of radiolucent lesions associated with impacted teeth: A retrospective study. Curr Med Imaging. 2020;16:1332-1339. [Crossref]
5. Kosti E, Lambrianidis T, Chatzivasvas P, Molyvdas I. Healing of a radiolucent periradicular lesion with periradicular radiopacity. J Endod. 2004;30:548-550. [Crossref]

6. Slutzky-Goldberg I, Heling I. Healing of a fibrous dysplastic lesion in a permanent molar after endodontic therapy. *J Endod.* 2007;33:314-317. [\[Crossref\]](#)
7. Piattelli A, Perfetti G, Carraro A. Complex odontoma as a periapical and interradicular radiopacity in a primary molar. *J Endod.* 1996;22:561-563. [\[Crossref\]](#)
8. Geist JR, Katz JO. The frequency and distribution of idiopathic osteosclerosis. *Oral Surg Oral Med Oral Pathol Oral Radiol Endod.* 1990;69:388-393. [\[Crossref\]](#)
9. Petrikowski CG, Peters E. Longitudinal radiographic assessment of dense bone islands of the jaws. *Oral Surg Oral Med Oral Pathol.* 1997;83:627-634. [\[Crossref\]](#)
10. Eliasson S, Ljungheimer C. Periapical condensing osteitis and endodontic treatment. *Oral Surg Oral Med Oral Pathol.* 1984;57:195-199. [\[Crossref\]](#)
11. Marmary Y, Kutiner G. A radiographic survey of periapical jawbone lesions. *Oral Surg Oral Med Oral Pathol.* 1986;61:405-408. [\[Crossref\]](#)
12. Halse A, Molven O. Idiopathic osteosclerosis of the jaws followed through a period of 20-27 years. *Int Endod J.* 2002;35:747-751. [\[Crossref\]](#)
13. Williams TP, Brooks SL. A longitudinal study of idiopathic osteosclerosis and condensing osteitis. *Dentomaxillofac Radiol.* 1998;27:275-278. [\[Crossref\]](#)
14. Yusof MY, Dasor MM, Ariffin F, Reduwan NH, Kamil WN, Mah MC. Idiopathic osteosclerosis mimicry of a tooth: case report. *Aust Dent J.* 2020;65:308-312. [\[Crossref\]](#)
15. Avramidou FM, Markou E, Lambrianidis T. Cross-sectional study of the radiographic appearance of radiopaque lesions of the jawbones in a sample of Greek dental patients. *Oral Surg Oral Med Oral Pathol Oral Radiol Endod.* 2008;106:38-43. [\[Crossref\]](#)
16. Miloglu O, Yalcin E, Buyukkurt MC, Acemoglu H. The frequency and characteristics of idiopathic osteosclerosis and condensing osteitis lesions in a Turkish patient population. *Med Oral Patol Oral Cir Bucal.* 2009;14:640-645. [\[Crossref\]](#)
17. Dedeoğlu N, Arıkan B. Evaluation of radiopaque lesions of the jaw bones on digital panoramic radiography in a Turkish subpopulation: a retrospective study. *J Dent Fac Atatürk Uni.* 2021;31:154-159. [\[Crossref\]](#)
18. Farrokh F, Ruhani MR, Zarandi A. Frequency and pattern of idiopathic osteosclerosis and condensing osteitis lesions in panoramic radiography of Iranian patients. *Dent Res J (Isfahan).* 2016;1:322. [\[Crossref\]](#)
19. Altun O, Dedeoğlu N, Umar E, Yolcu Ü, Acar AH. Condensing osteitis lesions in Eastern Anatolian Turkish population. *Oral Surgery, Oral Medicine, Oral Radiology.* 2014;2:17-20. [\[Crossref\]](#)
20. Secgin CK, Günhan O, Gulsahı A. Benign fibroosseöz lezyonlar. *Acta Odontol Turc.* 2016;33:95-101.
21. Verzak Ž, Čelap B, Modrić VE, Sorić P, Karlović Z. The prevalence of idiopathic osteosclerosis and condensing osteitis in Zagreb population. *Acta Clin Croat.* 2012;51:573-577. [\[Crossref\]](#)
22. Zegarelli E, Kutscher A, Hyman G. *Diagnosis of the mouth and jaws*, 2nd ed. Philadelphia: Lea & Febiger, 1978: 236-239. [\[Crossref\]](#)
23. Gumru B, Akkitap MP, Devenci S, Idman E. A retrospective cone beam computed tomography analysis of cemento-osseous dysplasia. *J Dent Sci.* 2021;16:1154-1161. [\[Crossref\]](#)
24. Eversole R, Su L, ElMofty S. Benign fibro-osseous lesions of the craniofacial complex. A review. *Head Neck Pathol.* 2008;2:177-202. [\[Crossref\]](#)
25. Senia ES, Sarao MS. Periapical cemento-osseous dysplasia: a case report with twelve-year follow-up and review of literature. *Int Endod J.* 2015;48:1086-1099. [\[Crossref\]](#)
26. Ozgur A, Kara E, Arpacı R, Arpacı T, Esen K, Kara T, Duce MN, et al. Nonodontogenic mandibular lesions: differentiation based on CT attenuation. *Diagn Interv Radiol.* 2014;20:475-480. [\[Crossref\]](#)
27. Cavalcanti PH, Nascimento EH, Pontual ML, et al. Cemento-osseous dysplasias: imaging features based on cone beam computed tomography scans. *Braz Dent J.* 2018;29:99-104. [\[Crossref\]](#)
28. McCarthy EF. Fibro-Osseous lesions of the maxillofacial bones. *Head Neck Pathol.* 2013;7:5-10. [\[Crossref\]](#)
29. Ebenezer V, Ramalingam BA. Cross-sectional survey of prevalence of odontogenic tumours. *J Maxillofac Oral Surg.* 2010;9:369-374. [\[Crossref\]](#)
30. Nelson BL, and Thompson LDR. Compound odontoma. *Head Neck Pathol.* 2010;4:290-291. [\[Crossref\]](#)
31. Açıkgöz A, Çelenk P, Kayıpmaç S. Odontomaların görülme sıklığı (radyografik çalışma). *Ondokuz Mayıs Üniv Diş Hek Fak Derg.* 1999;1. [\[Crossref\]](#)
32. Hidalgo-Sánchez O, Leco-Berrocal MI, Martínez-González JM. Metaanalysis of the epidemiology and clinical manifestations of odontomas. *Med Oral Patol Oral Cir Bucal.* 2008;13:E730-734. [\[Crossref\]](#)
33. Neelakandan RS, Deshpande A, Krithika C, Bhargava D. Maxillary cementoblastoma: a rarity. *Oral Maxillofac Surg.* 2012;16:119-121. [\[Crossref\]](#)
34. Bhaskar SN. *Radiographic interpretation for the dentist*. 3rd ed. St. Louis: Mosby; 1979.
35. Alaajam R, Saleh AA, Alghamdi NS, Ain TS, Algarni YA, Abubaker M. Incidence and distribution of pulp stones among Southern Saudi Arabian sub-population. *SAGE Open Med.* 2021;9:20503121211062796. [\[Crossref\]](#)
36. Jannati R, Afshari M, Moosazadeh M, Allahgholipour S, Eidy M, Hajihoseini M. Prevalence of pulp stones: A systematic review and meta-analysis. *J Evid Based Med.* 2019;12:133-139. [\[Crossref\]](#)