

The change of anterior chamber angle parameters after cataract surgery in diabetic patients

Alper Halil Bayat  and Cetin Akpolat 

Ther Adv Ophthalmol

2021, Vol. 13: 1–8

DOI: 10.1177/
25158414211034717

© The Author(s), 2021.
Article reuse guidelines:
[sagepub.com/journals-
permissions](https://sagepub.com/journals-permissions)

Abstract

Purpose: The purpose of this study is to investigate the change of anterior chamber angle morphology after cataract surgery in patients with type 2 diabetes mellitus (DM2) using anterior segment optical coherence tomography (AS-OCT).

Methods: In this prospective and comparative study, 57 eyes of the patients with cataract were investigated. The patients were divided into two groups. The DM2 group included cataractous type 2 diabetic patients without diabetic retinopathy ($n = 30$) and the non-DM2 group included nondiabetic participants with cataract ($n = 27$). The AS-OCT examinations were performed at baseline and 1 month after the cataract surgery. The corrected distance visual acuity (CDVA), intraocular pressure (IOP), angle-opening distance at 500 μm (AOD-500) and trabecular iris space area at 500 μm (TISA-500), and scleral spur angle (SSA) in temporal quadrant were analyzed.

Results: The mean age, sex, and axial length values were similar in both groups ($p > 0.05$ for all). The CDVA was significantly improved in both groups ($p < 0.001$). The mean AOD-500, TISA-500, and SSA were increased and the mean IOP was decreased after cataract surgery in both groups ($p < 0.001$ for all). There were not any statistically significant intergroup differences in CDVA, IOP, and AS-OCT measurements between the DM2 and non-DM2 groups ($p > 0.05$ for all).

Conclusion: Cataract surgery showed significant increases in mean anterior chamber angle parameters and reductions in IOP values in both diabetic and nondiabetic patients without intergroup significant differences. These results suggested the safety and effectiveness of cataract surgery, especially regarding anterior chamber angle parameters and so IOP changes.

Keywords: anterior chamber angle parameters, anterior segment optical coherence tomography, cataract surgery, diabetes mellitus

Received: 20 February 2021; revised manuscript accepted: 6 July 2021.

Introduction

Cataract is the most common reason for preventable vision loss in the world.¹ The increased aqueous outflow is thought to be an important effect of cataract surgery plus posterior chamber intraocular lens (PC-IOL) implantation in intraocular pressure (IOP) drop.^{2,3} This IOP reduction may be due to changes in the anterior segment parameters, including anterior chamber depth (ACD) and anterior chamber angle (ACA) measurements.^{3,4}

It is known that diabetic patients have shallower anterior chambers and thicker crystalline lenses.⁴ Moreover, diabetic participants have been found to have significantly higher IOP measurements than nondiabetic participants in population-based studies.⁵ There may be an inverse correlation between preoperative and postoperative IOP readings after cataract surgery.⁶ So, diabetic patients might present with greater IOP decreases than nondiabetic participants in the postoperative period. Hyperglycemia-induced fibronectin overexpression

Correspondence to:
Alper Halil Bayat
Department of
Ophthalmology, Esenler
Hospital, Medipol
University, Birlik Mah
Bahçeler cad. no:5 Esenler
34320, Istanbul, Turkey.
[alper.bayat@medipol
.edu.tr](mailto:alper.bayat@medipol.edu.tr)
Cetin Akpolat
Department of
Ophthalmology, Sisli
Hamidiye Etfal Training
and Research Hospital,
University of Health
Sciences, Istanbul, Turkey

in the trabecular meshwork, however, can limit this ocular hypotensive effect by increasing aqueous humor outflow resistance.⁷

The analysis of the anterior segment parameters plays an important role in the ocular examination. The assessment of the anterior segment is limited via using slit-lamp bio-microscopy. So, additional modalities should be used to evaluate the anterior segment parameters, including ACA measurements. There are several techniques for ACA imaging, including ultrasound bio-microscopy, Goldmann 3-mirror lens, Pentacam rotating Scheimpflug camera, and Orbscan scanning topography and anterior segment optical coherence tomography (AS-OCT). High-resolution noncontact, easy, rapid, and repeatable properties are the advantages that provide the clinicians to use AS-OCT recently and commonly for the evaluation of anterior segment parameters.⁸ Qualitative and quantitative analysis of ACA parameters, including the angle-opening distance at 500 μm anterior to the scleral spur (AOD-500), trabecular iris space area at 500 μm anterior to the scleral spur (TISA-500), and scleral spur angle (SSA), which are also predictive markers of IOP reduction following cataract surgery were analyzed by AS-OCT.^{6,9}

Being a common procedure in clinical practice indicates the importance of cataract surgery on anterior segment angle parameter changes using high-resolution noncontact and easily applicable AS-OCT technology. For that purpose, we aimed to compare the impact of cataract surgery on ACA parameters in nonglaucomatous diabetic cataractous patients *versus* healthy cataractous participants. In addition, possible predictive factors inducing postoperative greater IOP drop were assessed.

Methods

This prospective study was conducted in accordance with the tenets of the Declaration of Helsinki. The Ethics Committee of İstanbul Medipol University approved the study (protocol number 34; approval date 20 August 2020). The study period was between September 2020 and January 2021. Signed consent forms were obtained from all patients before the cataract surgery.

Participants

A total of 57 cataractous patients with visual impairment were enrolled in this study. The grade

of cataract was expressed according to the lens opacities classification system III (LOCS III) scoring.¹⁰ Right eyes were included in the study and the patients were assessed in two groups. Cataractous patients with type 2 diabetes mellitus (DM2) comprised the DM2 group ($n = 30$, without diabetic retinopathy) and the remaining 27 cataractous patients served as the non-DM2 group. The patients in the DM2 group did not have any systemic and ocular disease other than DM2 and cataract, respectively, whereas the cataractous patients in the non-DM2 group did not have any systemic disease. Inclusion criteria were as follows: age greater than 18 years; adherence to the ocular procedures and cataract surgery; open-angle, visually significant cataract; a corrected distance visual acuity (CDVA) worse than 20/40; and an intraocular pressure (IOP) of 21 mm Hg or less. Patients with axial length >26.00 and <18.00 mm, zonule defects, narrow or closed angle, exfoliation, peripheral anterior synechiae, corneal opacity, traumatic cataract, lens dislocation, inflammatory eye disease, a cup-to-disk ratio greater than 0.6 fundus abnormalities, glaucomatous optic neuropathy, signal strength $<6/10$, glaucoma, previous ocular surgery, and ocular trauma were excluded from the study. All patients underwent a detailed preoperative and postoperative ocular evaluation, including CDVA (in decimal), IOP measurement (mmHg), biomicroscopic anterior and posterior segment examination, gonioscopy, and AS-OCT measurements. IOP measurements were performed by a single and masked observer using a calibrated and pneumatic noncontact tonometry (Topcon) with consecutive three measurements after the AS-OCT measurements. CDVA, IOP, and OCT measurements in the preoperative period and postoperative period at month 1 were compared between intra- and intergroup.

Measurement protocol

All preoperative (baseline, 1 week before the phacoemulsification surgery) and postoperative (1 month after the surgery) were performed by a different masked and experienced researcher under standard dim light conditions. No topical drop, including nonsteroidal anti-inflammatory drug (NSAID), was used before the surgery or AS-OCT measurements. Repeatable scans with signal strength of $\geq 6/10$ were included in the study. AS-OCT measurements were manually performed by another single, masked, and experienced researcher under standard dim light conditions. New spectral-domain OCT Goniometry

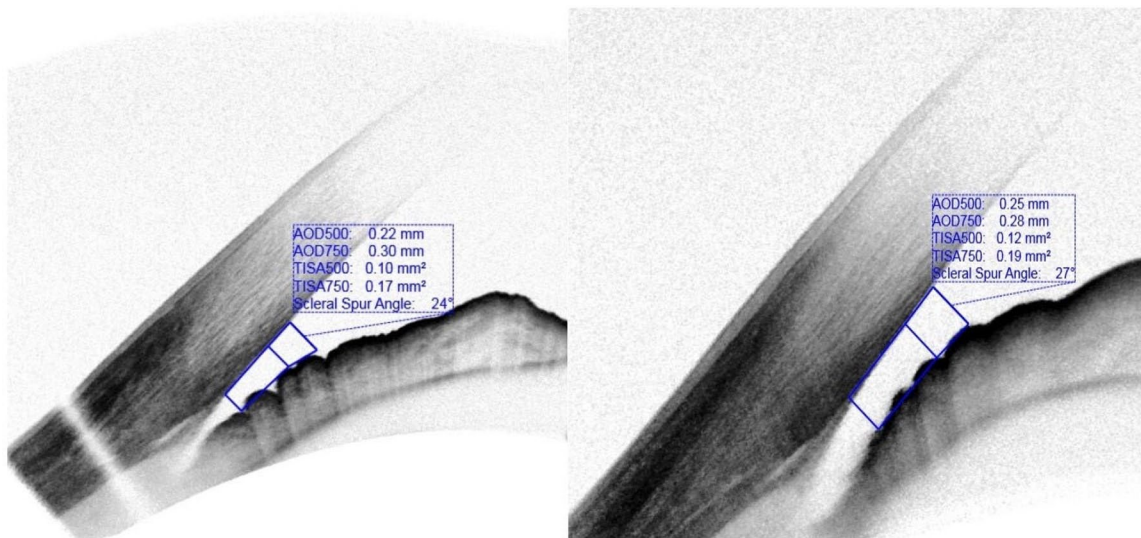


Figure 1. A sample of the changes in anterior angle parameters after cataract surgery.

(Cirrus HD-OCT 5000/500; Carl Zeiss Meditec, Inc., Dublin, CA, USA), a noncontact method, with high-definition (HD) angle in 6×2.9 mm and exquisite detail of the iridocorneal angle was used for ACA measurements. The patients were instructed to fix an internal fixation target during the scan process. Although similar good results are achieved from both temporal and nasal sides, a tendency of temporal side selection in the literature oriented us to take all AS-OCT measurements from the temporal side of the right eyes.¹¹ These AS-OCT measurements included the AOD-500, TISA-500, and SSA.

The researcher constructed a 500- μ m and scleral spur centered circle. The intersection point on the anterior surface of the iris was determined. The AOD-500 was identified as the linear distance from the point of the inner corneoscleral wall (500 μ m anterior to the scleral spur) to the iris. The TISA-500 was described as the trapezoidal area with the following borders: the inner corneoscleral wall (superiorly), the iris surface (inferiorly), the AOD-500 (anteriorly), and a perpendicular route between the scleral spur, the surface of the inner scleral wall and the oppositely located iris (posteriorly) (Figure 1). Following the marking of the scleral spur, the AS-OCT software automatically measured the at AOD-500, TISA-500, and SSA.

Surgical procedure

The method for cataract surgery was phacoemulsification using the Alcon Constellation Vision System

device (Alcon Laboratories, Inc., Fort Worth, TX, USA). The procedure was performed for the right eyes by the same experienced surgeon under sterile conditions and topical anesthesia. After performing the corneal side incisions, main corneal tunnel and the capsulorhexis, the nucleus material was excreted by phacoemulsification. Following the aspiration of epinucleus and cortex, an aspheric foldable intraocular lens (IOL) was implanted into the capsular bag. The surgical procedure was completed after the injection of intracameral antibiotic and confirmation of adequate ACD with normal globe tonus. Topical ophthalmic steroids and antibiotics were prescribed for postoperative treatment. The patients had control visits at postoperative day 1, week 1, and month 1. Considerable peri- or postoperative complications were planned to be recorded, and fortunately no remarkable peri- or postoperative complications were observed. Topical moxifloxacin and prednisolone were prescribed 5 times a day for 2 weeks in the postoperative period.

Statistical analysis

The included data were analyzed using SPSS 21.0 software (IBM Corp., Armonk, NY, USA). The constant variables were described as the mean \pm standard deviation. The Kolmogorov–Smirnov test was used to test the distribution normality. Paired- and independent-samples *t* tests were used for data statistical analysis. Correlation analysis was assessed using the Pearson correlation test. The statistical significance set point was considered in the case of *p* value was <0.05 . The

Table 1. Intergroup and intragroup comparisons of IOP, AOD-500, TISA-500, and SSA in AS-OCT measurements between type 2 diabetic patients (DM2 group) and nondiabetic participants (non-DM2 group).

	Preoperative	Postoperative ^a	<i>p</i> ^b
IOP (mmHg)			
DM2 group (<i>n</i> = 30)	14.83 ± 1.70	13.43 ± 1.50	<0.001 ^c
Non-DM2 group (<i>n</i> = 27)	14.44 ± 1.84	12.81 ± 1.32	<0.001 ^c
<i>p</i> values ^d	0.496	0.264	
AOD-500 (mean ± SD, mm)			
DM2 group (<i>n</i> = 30)	0.51 ± 0.04	0.76 ± 0.07	<0.001 ^c
Non-DM2 group (<i>n</i> = 27)	0.51 ± 0.03	0.75 ± 0.08	<0.001 ^c
<i>p</i> values ^d	0.946	0.723	
TISA-500 (mean ± SD, mm ²)			
DM2 group (<i>n</i> = 30)	0.19 ± 0.03	0.29 ± 0.03	<0.001 ^c
Non-DM2 group (<i>n</i> = 27)	0.20 ± 0.03	0.30 ± 0.04	<0.001 ^c
<i>p</i> values ^d	0.382	0.593	
SSA (mean ± SD, °)			
DM2 group (<i>n</i> = 30)	27.30 ± 5.96	33.03 ± 5.62	<0.001 ^c
Non-DM2 group (<i>n</i> = 27)	29.18 ± 4.26	35.22 ± 3.64	<0.001 ^c
<i>p</i> values ^d	0.073	0.085	
AOD-500, angle-opening distance at 500 μm anterior to the scleral spur; AS-OCT, anterior segment optical coherence tomography; DM2, type 2 diabetes mellitus; IOP, intraocular pressure; SD, standard deviation; SSA, scleral spur area; TISA-500, trabecular iris space area distance at 500 μm anterior to the scleral spur. ^a The final AS-OCT measurements were 1 month after the cataract surgery in both groups. ^b Statistical analysis with paired-samples <i>t</i> test. ^c Statistically significant. ^d Statistical analysis with independent-samples <i>t</i> test.			

calculation of the minimum sample size was performed using the G*Power package program. Because no compatible report was reviewed in the literature, the effect size was considered as 0.5 and the minimum sample size was calculated as 25. The statistical power was calculated by using a confidence interval of 95% and an overall two-sided type I error rate of 0.05. The power calculation of the sample size was 0.72.

Results

The mean age of the patients was 66.56 ± 6.20 (57–72) years in the diabetic group and 65 ± 6.48

(55–70) years in the control group (*p* = 0.356). There were 14 female and 16 male patients in the DM2 group, and 13 female and 14 male patients in the non-DM2 group (*p* = 0.911). All patients in the DM2 group had controlled DM2 with oral antidiabetic treatments. All diabetic patients had the diagnosis of DM2 less than 10 years and a value of HbA1c less than 7.0 (%). The average stage of cataract was 2.46 ± 0.64 and 2.28 ± 0.65 in the DM2 and non-DM2 groups, respectively (*p* = 0.307). The mean axial length was 23.29 ± 1.25 mm (19.20–24.86) in the DM2 group and 22.75 ± 1.31 mm in the non-DM2 group (*p* = 0.412). The mean IOL power was 22.18 ± 2.02 and 22.36 ± 1.92 in the diabetic and control groups, respectively (*p* = 0.738).

The mean preoperative CDVA improved from 0.36 ± 0.02 to 0.68 ± 0.04 in the DM2 group (*p* < 0.001) and from 0.38 ± 0.01 to 0.67 ± 0.05 in the non-DM2 group (*p* < 0.001). The mean preoperative IOP significantly decreased in both DM2 and non-DM2 groups (*p* < 0.001 for both). The mean preoperative and postoperative intergroup CDVA and IOP analysis showed similar results between the DM2 and non-DM2 groups (*p* > 0.05 for all).

All mean preoperative AOD-500, TISA-500, and SSA values increased significantly in the postoperative period in both DM2 and non-DM2 groups (*p* < 0.001 for all) (Figure 1). All mean preoperative and postoperative intergroup AOD-500, TISA-500, and SSA comparisons, however, represented statistically insignificant outcomes (*p* > 0.05 for all) (Table 1).

In the DM2 group, IOP change showed a significant negative correlation with preoperative IOP (*r* = -0.602, *p* < 0.001; Figure 2). SSA change was correlated with preoperative SSA (*r* = -0.446, *p* = 0.001; Figure 3). AOD-500 change was not correlated with preoperative AOD-500 (*r* = 0.162, *p* = 0.302). TISA-500 change did not also show significant correlation with preoperative TISA-500 (*r* = -0.296, *p* = 0.516).

Similar correlations were observed in the non-DM2 group. IOP change was significantly correlated with preoperative IOP (*r* = -0.372, *p* = 0.004, Figure 4). SSA change showed a significant correlation with preoperative SSA (*r* = -0.388, *p* = 0.002, Figure 5). AOD-500 change and TISA-500 change were not correlated with preoperative AOD-500 (*r* = 0.108, *p* = 0.236) and TISA-500 (*r* = -0.145, *p* = 0.322), respectively.

Discussion

Quantitative and qualitative analysis of the ACA parameters have been assessed by various imaging techniques.¹² Noncontact measured images with high-resolution, easy, fast, reliable, and reproducible features make AS-OCT a common imaging modality in the field of ophthalmology.¹³

This study compared the effect of phacoemulsification on the ACA parameters measured by AS-OCT and IOP measurements between cataractous patients with DM2 and healthy cataractous participants. The intergroup analysis showed similar results in diabetic and nondiabetic patients in both perioperative and postoperative periods. The intragroup outcomes revealed a significant decrease in mean postoperative IOP and increases in AS-ACA parameters in the postoperative period when compared with the preoperative period. Only IOP and SSA changes showed significant correlations with preoperative IOP and SSA values, respectively.

Preoperative IOP-decreasing predictive factors can provide a considerable contribution to the decision-making process of cataract surgery, especially in open-angled patients with glaucoma and ocular hypertension. Anterior segment-specific factors, including anterior chamber anatomy (volume, depth, and angle), crystalline lens or PC-IOL factors (position, thickness, and vault), and iris (cross-sectional area and convex shape), are key predictive factors for postoperative IOP alteration.^{14,15} Unfortunately, the clinical value and association of these variables remain controversial.

Statistically significant higher IOP measurements in diabetic patients might be due to corneal thickness increase and corneal stiffness resulted from protein cross-linking caused by advanced glycosylated end-products.¹⁶ Meanwhile, a high corneal resistance may also be accompanied by an increased trabecular meshwork stiffness, which may lead to greater resistance to aqueous humor outflow and so higher IOP values.¹⁷ Stress remodeling of the trabecular meshwork due to ultrasonic vibrations of phacoemulsification may not be observed in diabetic patients because of the delayed remodeling caused by hyperglycemia-induced fibronectin overexpression.¹⁸ This may also result in lower IOP drop changes in diabetic patients. We, however, found similar preoperative and postoperative IOP values between the diabetic and nondiabetic participants. This can be explained by relatively small sample size and wide

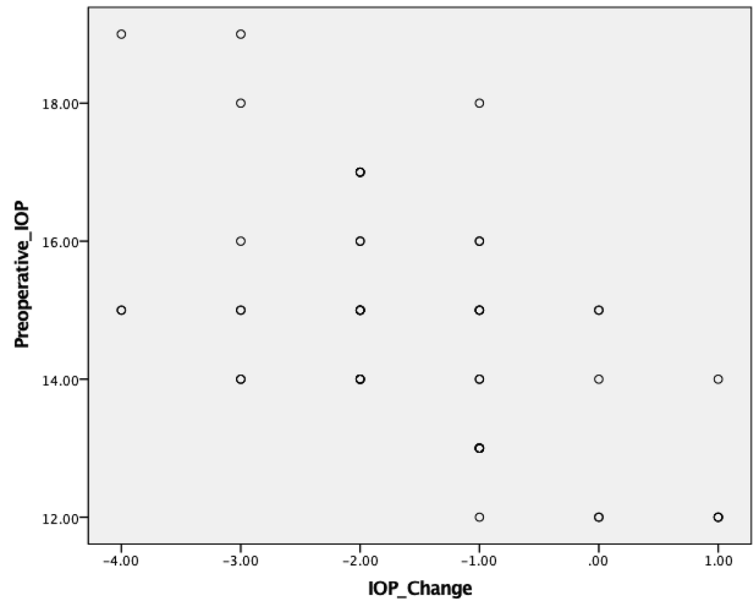


Figure 2. Scatterplot representing the linear correlation between postoperative IOP change and preoperative IOP in the DM2 group. DM2, type 2 diabetes mellitus; IOP, intraocular pressure. Pearson correlation test was used for correlation analysis.

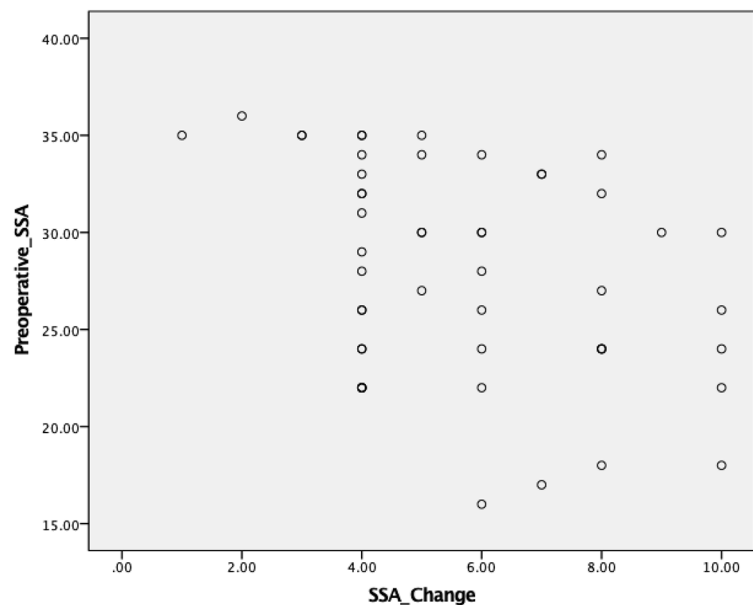


Figure 3. Scatterplot representing the linear correlation between postoperative SSA change and preoperative SSA in the DM2 group. DM2, type 2 diabetes mellitus; SSA, scleral spur angle. Pearson correlation test was used for correlation analysis.

IOP measurement standard deviations. In some studies, IOP to ACD, IOP to lens volume, and IOP to angle ratios were related to postoperative IOP alteration in univariate analysis, but this

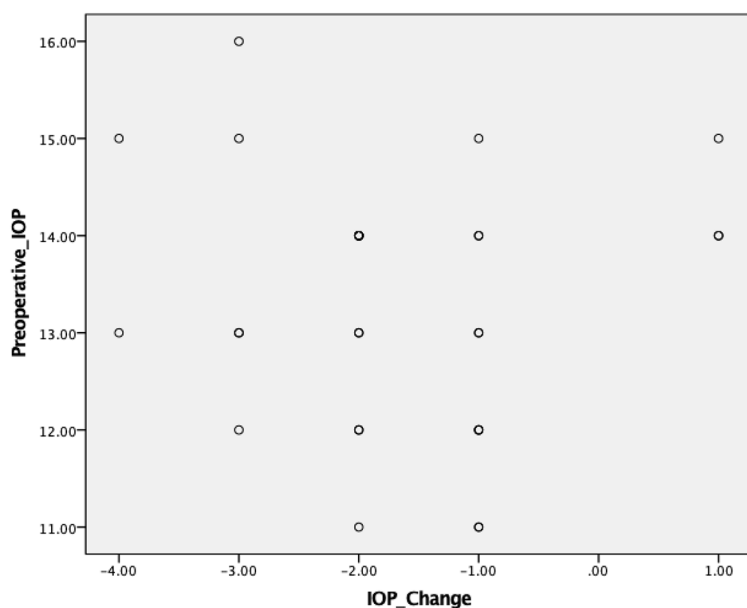


Figure 4. Scatterplot representing the linear correlation between postoperative IOP change and preoperative IOP in nondiabetic participants. IOP, intraocular pressure. Pearson correlation test was used for correlation analysis.

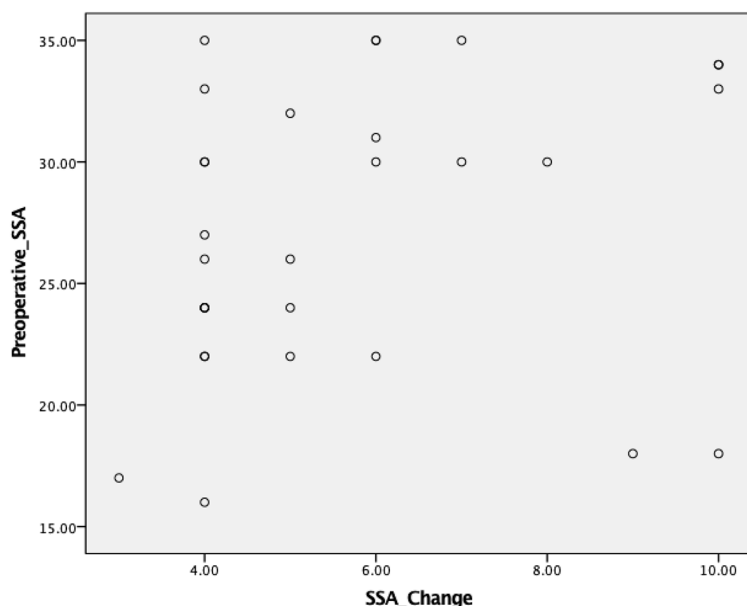


Figure 5. Scatterplot representing the linear correlation between postoperative SSA change and preoperative SSA in nondiabetic participants. SSA, scleral spur angle. Pearson correlation test was used for correlation analysis.

impact was not observed in multivariate analysis.^{3,15} Preoperative IOP was the only significant predictive factor of postoperative IOP alteration in the multivariate assessment.^{19,20}

The anterior segment of diabetic patients may differ from nondiabetic participants. Diabetic patients may have shallower anterior chambers due to an increased crystalline lens thickness.²¹ Although no studies have been found reporting AOD-500, TISA-500, and SSA differences in the AS-OCT measurements between diabetic and nondiabetic patients, this study did not reach a statistical significance regarding the differences of these variables between diabetic and nondiabetic participants. We, however, technically could not assess the impact of lens vault or thickness on the ACA parameters.

A recent study concluded that nonglaucomatous, cataractous, and open-angled eyes from both DM2 and nondiabetic patients represented similar anterior segment alterations and IOP drops following uneventful phacoemulsification, and this IOP-decreasing impact was strongly correlated with preoperative IOP.²² In contrast to our results, this study revealed that mean preoperative ACA in the DM2 group was significantly lower than non-DM2 group ($30.2 \pm 5.5^\circ$ versus $33.0 \pm 5.9^\circ$, respectively, $p = 0.022$). Similar to our findings, the authors observed that mean ACA was significantly greater than mean preoperative value at 1 and 6 months of follow-up in both DM2 and non-DM2 groups ($p < 0.001$, paired t test), and they did not note intergroup differences at the final visit.

Eventless phacoemulsification procedure may allow widening of the ACA, rise the ACD, and improve the pupil blockade, and thus the aqueous humor outflow might increase.²³ Meanwhile, a comparative study showed that aphakia caused by complicated cataract surgery also led to significant rises in ACD, AOD-500, AOD-750, TISA-500, and TISA-750 when compared with normal fellow eyes.²⁴ Another study demonstrated approximately 2 times increases in ACA indicators, including AOD-500, AOD-750, TISA-500, and TISA-750 following cataract surgery.²⁵ This was similar to the results of another study, concluding the change of the ACA parameters after cataract extraction of the patients with angle-closure glaucoma.²⁶ Similarly, our results represented an increasing tendency in ACA measurements following phacoemulsification procedure in both diabetic and nondiabetic patients.

The strengths of the study included prospective and comparative nature, a relatively unique subject that provides data for clinicians regarding the

safety of cataract surgery for ACA parameters and the same practicing experienced surgeon. Limitations to the study included relatively small sample size, short-term results, single preoperative and postoperative visits for IOP measurement, the inclusion of only the Turkish population, and the exclusion of advanced stages of diabetic retinopathy and cataract.

In conclusion, cataract surgery in both diabetic and nondiabetic patients can provide a significant decrease of IOP and increase in the ACA parameters measured using AS-OCT in the postoperative period. Preoperative and postoperative mean IOP and ACA measurements of diabetic patients were similar to nondiabetic patients. Regarding the ACA measurements, this study concluded that the cataract extraction procedure provided a similar and safe outcome on postoperative IOP measurements for diabetic and nondiabetic patients.

Conflict of interest statement

The authors declared no potential conflicts of interest with respect to the research, authorship, and/or publication of this article.

Funding

The authors received no financial support for the research, authorship, and/or publication of this article.

ORCID iDs

Alper Halil Bayat  <https://orcid.org/0000-0003-1827-968X>

Cetin Akpolat  <https://orcid.org/0000-0002-7443-6902>

References

- Zanon-Moreno V, Marco-Ventura P, Lleo-Perez A, *et al.* Oxidative stress in primary open-angle glaucoma. *J Glaucoma* 2008; 17: 263–268.
- Melancia D, Abegão Pinto L and Marques-Neves C. Cataract surgery and intraocular pressure. *Ophthalmic Res* 2015; 53: 141–148.
- Moghimi S, Abdi F, Latifi G, *et al.* Lens parameters as predictors of intraocular pressure changes after phacoemulsification. *Eye* 2015; 29: 1469–1476.
- Kocatürk T, Zengin MÖ, Çakmak H, *et al.* The ocular biometric differences of diabetic patients. *Eur J Ophthalmol* 2014; 24: 786–789.
- Krueger RR and Ramos-Esteban JC. How might corneal elasticity help us understand diabetes and intraocular pressure? *J Refract Surg* 2007; 23: 85–88.
- Coh P, Moghimi S, Chen RI, *et al.* Lens position parameters as predictors of intraocular pressure reduction after cataract surgery in glaucomatous versus nonglaucomatous eyes. *Invest Ophthalmol Vis Sci* 2016; 57: 2593–2599.
- Sato T and Roy S. Effect of high glucose on fibronectin expression and cell proliferation in trabecular meshwork cells. *Invest Ophthalmol Vis Sci* 2002; 43: 170–175.
- McKee H, Ye C, Yu M, *et al.* Anterior chamber angle imaging with swept-source optical coherence tomography: detecting the scleral spur, Schwalbe's line, and Schlemm's canal. *J Glaucoma* 2013; 22: 468–472.
- Hsu CH, Kakigi CL, Lin SC, *et al.* Lens position parameters as predictors of intraocular pressure reduction after cataract surgery in non-glaucomatous patients with open angles. *Invest Ophthalmol Vis Sci* 2015; 56: 7807–7813.
- Grewal DS, Brar GS and Grewal SPS. Correlation of nuclear cataract lens density using Scheimpflug images with lens opacities classification system III and visual function. *Ophthalmology* 2009; 116: 1436–1443.
- Ang M, Baskaran M, Werkmeister RM, *et al.* Anterior segment optical coherence tomography. *Prog Retin Eye Res* 2018; 66: 132–156.
- Doganay S, Bozgul Firat P, Emre S, *et al.* Evaluation of anterior segment parameter changes using the Pentacam after uneventful phacoemulsification. *Acta Ophthalmol* 2010; 88: 601–606.
- Römkens HCS, Beckers HJM, Frusch M, *et al.* Reproducibility of anterior chamber angle analyses with the swept-source optical coherence tomography in young, healthy Caucasians. *Invest Ophthalmol Vis Sci* 2014; 55: 3999–4004.
- Simsek A, Bilgin B, Çapkin M, *et al.* Evaluation of anterior segment parameter changes using the Sirius after uneventful phacoemulsification. *Korean J Ophthalmol* 2016; 30: 251–257.
- Yang HS, Lee J and Choi S. Ocular biometric parameters associated with intraocular pressure reduction after cataract surgery in normal eyes. *Am J Ophthalmol* 2013; 156: 89–94.
- Scheler A, Spoerl E and Boehm AG. Effect of diabetes mellitus on corneal biomechanics and measurement of intraocular pressure. *Acta Ophthalmol* 2012; 90: e447–e451.

17. Tamm ER, Braunger BM and Fuchshofer R. Intraocular pressure and the mechanisms involved in resistance of the aqueous humor flow in the trabecular meshwork outflow pathways. *Prog Mol Biol Transl Sci* 2015; 134: 301–314.
18. Wang N, Chintala SK, Fini ME, *et al.* Ultrasound activates the TM ELAM-1/IL-1/NF- κ B response: a potential mechanism for intraocular pressure reduction after phacoemulsification. *Invest Ophthalmol Vis Sci* 2003; 44: 1977–1981.
19. Mansberger SL, Gordon MO, Jampel H, *et al.* Reduction in intraocular pressure after cataract extraction: the ocular hypertension treatment study. *Ophthalmology* 2012; 119: 1826–1831.
20. Sengupta S, Venkatesh R, Krishnamurthy P, *et al.* Intraocular pressure reduction after phacoemulsification versus manual small-incision cataract surgery. *Ophthalmology* 2016; 123: 1695–1703.
21. Bayat AH, Özturan ŞG, Çakır A, *et al.* Corneal endothelial morphology and anterior segment parameters in children with type 1 diabetes mellitus. *Turk J Pediatr* 2020; 62: 468–473.
22. Beato JN, Reis D, Esteves-Leandro J, *et al.* Intraocular pressure and anterior segment morphometry changes after uneventful phacoemulsification in type 2 diabetic and nondiabetic patients. *J Ophthalmol* 2019; 2019: 9390586.
23. Nongpiur ME, He M, Amerasinghe N, *et al.* Lens vault, thickness, and position in Chinese subjects with angle closure. *Ophthalmology* 2011; 118: 474–479.
24. Demir G, Sucu ME, Yildirim Y, *et al.* The effects of complicated cataract surgery on iris structure and anterior chamber angle. *J Fr Ophthalmol* 2019; 42: 829–833.
25. Vu AT, Bui VA, Vu HL, *et al.* Evaluation of anterior chamber depth and anterior chamber angle changing after phacoemulsification in the primary angle close suspect eyes. *Open Access Maced J Med Sci* 2019; 7: 4297–4300.
26. Kim M, Park KH, Kim TW, *et al.* Changes in anterior chamber configuration after cataract surgery as measured by anterior segment optical coherence tomography. *Korean J Ophthalmol* 2011; 25: 77–83.