



Diagnosis and management of congenital vallecular cyst: An institutional experience

Serap Şahin Önder¹, Gözde Günay¹, Aslı Şahin-Yılmaz¹, Özgül Gergin²

¹Department of Otorhinolaryngology, University of Health Sciences, Ümraniye Training and Research Hospital, Istanbul, Turkey

²Department of Otorhinolaryngology, Medipol University Hospital, Istanbul, Turkey

ABSTRACT

Objectives: This study aims to evaluate the clinical presentation, diagnosis, and management of infants with a congenital vallecular cyst (VC).

Patients and Methods: Four infants (2 males, 2 females; mean age: 45±17 days; range, 28 to 63 days) who were operated or followed for a congenital VC were retrospectively analyzed between January 2016 and March 2020. Data including patient demographics, major symptoms (cyanosis, inspiratory stridor, suprasternal retraction, difficulty feeding), diagnostic methods, type of coexisting anomalies, surgical procedures, and length of follow-up and recurrence were recorded.

Results: All patients presented with varying degrees of respiratory symptoms including inspiratory stridor and suprasternal retraction. The diagnosis was made based on awake flexible fiberoptic laryngoscopy (FFL) in all four infants. Two patients were treated with endoscopic cyst excision. One case underwent endoscopic cyst excision and supraglottoplasty, while the other was followed without surgery. All surgeries were successful, as none of the patients experienced recurrence.

Conclusion: Although congenital VCs are extremely rare, they should be considered among the differential diagnosis of congenital stridor. A detailed examination with FFL should be performed for diagnosis. Based on our findings, transoral endoscopic excision of VCs is a safe, effective, and feasible procedure as a surgical treatment to prevent recurrence.

Keywords: Congenital, cyst excision, infant, vallecular cyst.

Congenital vallecular cysts (VC) arise from the lingual surface of the epiglottis and histologically contain respiratory epithelium with mucous glands, lined externally with squamous epithelium.^[1] They are reported to be embryological malformations or may occur due to ductal occlusion of the mucous glands.^[2] Patients with congenital VC can present with feeding difficulties, inspiratory stridor, and varying degrees of upper airway obstruction. In most cases, symptoms manifest within the

first week of life.^[3] When a newborn presents with an intermittent apnea which can appear in different positions, VCs should be considered in the differential diagnosis.^[4]

Diagnoses VCs require a high index of clinical suspicion. Differential diagnoses of cystic lesions of the vallecula include lingual thyroid, thyroglossal duct cysts, lymphatic malformations, and cystic tumors such as teratomas.^[1] The management of decompensated pediatric patients with suspected upper

Received: July 21, 2020 Accepted: November 23, 2020 Published online: January 16, 2021

Correspondence: Serap Şahin Önder, MD. SBÜ Ümraniye Eğitim ve Araştırma Hastanesi Kulak Burun Boğaz Kliniği, 34764 Ümraniye, İstanbul, Turkey.
e-mail: serapsahinonder@gmail.com

Doi: <http://dx.doi.org/10.5606/Tr-ENT.2020.18291>

Citation:

Şahin Önder S, Günay G, Şahin-Yılmaz A, Gergin Ö. Diagnosis and management of congenital vallecular cyst: An institutional experience. Tr-ENT 2020;30(3):81-86.

Table 1. Demographic and clinical characteristics of patients

Patient	Sex	Age at presentation	Presenting symptoms	Diagnosis	Treatment	Endoscopic findings	Follow-up period	Follow-up age outcome
1	Male	1 month	Mild inspiratory stridor, no failure to thrive	TFFL, MRI	Observation without surgery	Vallecular cyst	15 months	Asymptomatic
2	Female	2 months	Severe inspiratory stridor, failure to thrive	TFFL	Endoscopic cyst excision and supraglottoplasty	Vallecular cyst, posterior displacement of epiglottis, type 1 laryngomalacia	18 months	Asymptomatic, no recurrence
3	Female	3 months	Severe inspiratory stridor, failure to thrive	TFFL	Endoscopic cyst excision	Vallecular cyst, posterior displacement of epiglottis	15 months	Asymptomatic, no recurrence
4	Male	2 months	Severe inspiratory stridor, no failure to thrive	TFFL	Endoscopic cyst excision	Vallecular cyst, posterior displacement of epiglottis	4 months	Asymptomatic, no recurrence

FFL: Flexible fiberoptic laryngoscopy; MRI: Magnetic resonance imaging.

airway obstruction requires definitive airway protection.^[4] Surgical treatment of VCs includes cyst aspiration, endoscopic excision, endoscopic marsupialization, and de-roofing with carbon dioxide (CO₂) laser or microdebrider.^[5]

In the present study, we aimed to evaluate the clinical presentation, diagnosis, and management of infants with a congenital VC.

PATIENTS AND METHODS

Four infants (2 males, 2 females; mean age: 45±17 days; range, 28 to 63 days) who were operated or followed for a congenital VC at a tertiary care hospital were retrospectively analyzed between January 2016 and March 2020. One of the patients (Patient 2) had coexisting type 1 laryngomalacia. All patients had respiratory symptoms within the first month of life. All infants underwent awake flexible fiberoptic laryngoscopy (FFL) at the initial consultation. During endoscopy, VCs were identified as smooth localized masses arising from and distorting the lingual surface of the epiglottis, thereby causing posterior displacement of epiglottis. Three patients were treated with the same surgical procedure, while one patient was followed without surgery. A written informed consent was obtained from each parent and/or legal guardians. The study protocol was approved by the Ümraniye Training and Research Hospital Ethics Committee (20/02/2020-4654). The study was conducted in accordance with the principles of the Declaration of Helsinki.

Data including patient demographics, major symptoms (cyanosis, inspiratory stridor, suprasternal retraction, difficulty feeding), diagnostic methods, type of coexisting anomalies, surgical procedures, and length of follow-up and recurrence were recorded.

Three patients underwent the same surgical procedure. Surgical excision was performed under general anesthesia via an endoscopic transoral approach. Direct laryngoscopy and tracheoscopy were performed to rule out the presence of a possible additional airway disease. Following orotracheal intubation, the laryngoscope was inserted to expose the epiglottis and tongue base. Under transoral endoscopic guidance, excision of the VC was

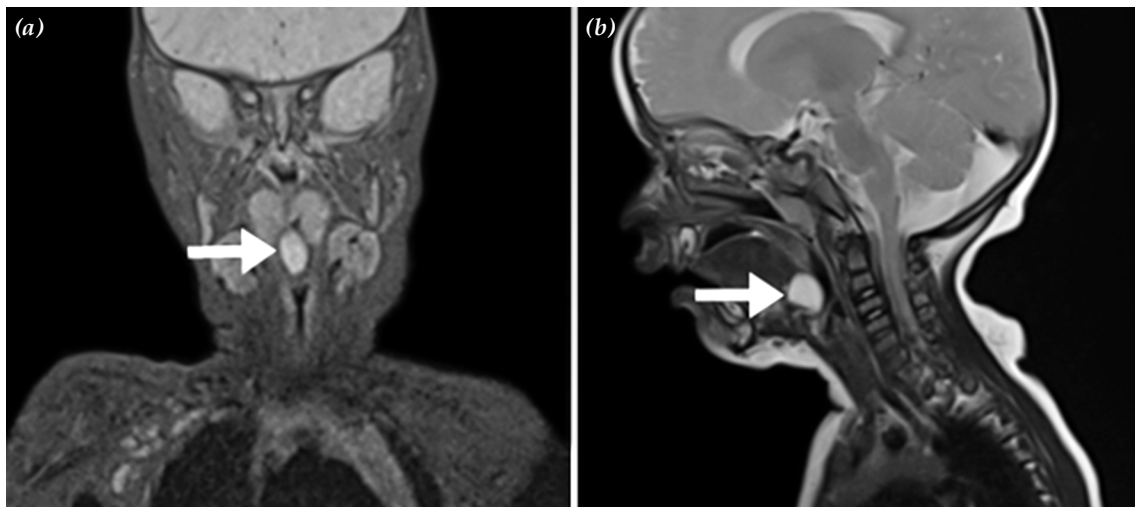


Figure 1. Imaging of midline vallecular cysts (arrows) in Patient 1. (a) Coronal T₂-weighted magnetic resonance imaging. (b) Sagittal T₂-weighted magnetic resonance imaging showing a 13×12-mm hyperdense cyst mass at the base of the tongue.

achieved with cold steel ensuring the removal of the lining. Surgical specimens were subjected to a routine pathological examination. Additionally, Patient 2 underwent supraglottoplasty.

RESULTS

Four patients were diagnosed with congenital VC causing severe airway obstruction. Table 1 shows the demographic characteristics of the patients, degree of respiratory symptoms, type of coexisting anomalies, length of follow-up, and recurrence.

All patients had varying degrees of respiratory symptoms including cyanosis, inspiratory stridor, and suprasternal retraction. All of them were symptomatic at birth. The diagnosis was done with awake FFL in all patients. The same surgical procedure was utilized to treat three patients, while one patient was followed without surgery. In all patients, histological analysis showed an external layer of squamous epithelium alongside respiratory epithelium and mucus glands on the inner surface of the cyst.

Patient 1 was a one-month-old male infant with a history of a noisy respiration since birth. The patient had a mild stridor without cyanosis or feeding problems. Flexible endoscopic examination revealed the presence of a cystic

mass at the vallecular space. Magnetic resonance imaging (MRI) of the neck confirmed an oval shaped cystic lesion at the base of tongue consistent with a VC (Figure 1). The patient was reexamined monthly. Although the symptoms subsided, the patient remained under a close follow-up.

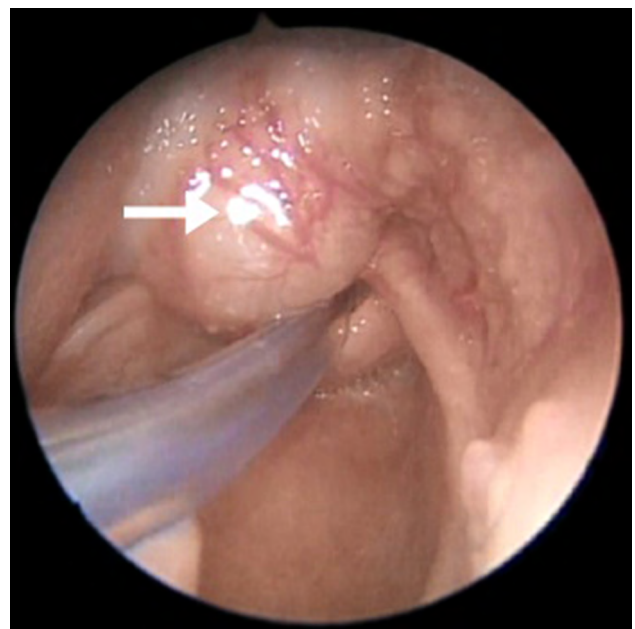


Figure 2. An intraoperative view of transoral endoscopy showing left-sided vallecular cysts (arrow) in Patient 2.

Patient 2 was a two-month-old female referred to our department with severe stridor, cyanotic episodes, and poor feeding. Flexible endoscopy showed a VC with posterior displacement of the epiglottis and floppy arytenoids obstructing the laryngeal inlet (Figure 2). The patient underwent surgery seven days after the initial examination. Excision of the cyst was performed with using laryngeal scissors. The excess floppy arytenoid mucosa, corniculate, and cuneiform cartilages were partially resected. The shortened aryepiglottic folds were sectioned. No pathology was detected in the subglottic region. The intubated patient was transferred to the neonatal intensive care unit (NICU) and extubated on postoperative Day 3. As the left superior pulmonary atelectasis occurred, she was observed for five consecutive days in the NICU. Then, she was transferred to our department and discharged on postoperative Day 9. At one month of follow-up, endoscopic findings were found to be normal and there were no feeding or breathing complaints.

Patient 3 was a three-month-old female infant referred to our department with noisy breathing and choking episodes. There was no history of cyanosis or severe obstructive respiratory symptoms. Flexible endoscopy showed posterior displacement of the epiglottis. Despite being treated with acid suppression therapy for a duration of one-month, severe respiratory distress and failure to thrive was reported. Flexible endoscopy showed an almost hemispherical cyst situated at the vallecula. Surgical procedure without epiglottoplasty was performed at four months of age. The patient was extubated promptly after surgery. Her symptoms resolved immediately after the operation. At one month of follow-up, the posterior displacement of the epiglottis improved and, therefore, no epiglottoplasty was needed.

Patient 4 was a two-day-old male infant referred to the pediatric emergency room with feeding difficulties and was irritable and teary. Chest X-ray showed no irregularities. After inhaler bronchodilator and oxygen therapy, there was no significant improvement in his symptoms. The patient was subsequently referred to our department to undergo an examination for possible airway disease.

Flexible endoscopy showed a cystic mass arising from the tongue base, causing retroflexion of the epiglottis. Surgical procedure without epiglottoplasty was performed at one month of age. He was extubated immediately and respiratory symptoms improved after surgery. At one month of follow-up, the posterior displacement of the epiglottis improved and, therefore, no epiglottoplasty was needed.

DISCUSSION

Congenital VCs are rare, but can cause life-threatening airway obstruction in infants. Amongst patients with congenital VC, the most common symptom is inspiratory stridor.^[6] The degree of respiratory distress can vary owing to the size of cystic mass, extension into the airway, and accompanying pathologies such as laryngomalacia.^[7] Respiratory symptoms are frequently documented in newborns, and feeding difficulties and failure to thrive can be observed in patients with late diagnosis.^[8] In addition, VCs can cause sudden upper airway obstruction in the misdiagnosed cases.^[5] In this series, Patient 2 and 4 revealed severe inspiratory stridor. Patient 3 presented with noisy breathing at first and was underdiagnosed. Patient 1 was referred with only mild inspiratory stridor.

Review of the literature suggests that, 64% of the cases, laryngomalacia co-exists with VCs.^[7,9] A possible explanation for this can be that the progressive enlargement of the cyst resulting from the alternation in the airway dynamics elevates inspiratory negative pressure, thereby causing supraglottic prolapse and a secondary form of laryngomalacia.^[10] Coexisting laryngomalacia exacerbates symptoms, complicates the treatment, increases the length of hospital stays, and necessitates intensive care for patients with VC and laryngomalacia.^[11] As previously reported, Patient 2 had shortened aryepiglottic folds and excess floppy arytenoid mucosa alongside posterior displacement of epiglottis resulting from VC. In Patients 3 and 4, endoscopic examination revealed posterior displacement of epiglottis without shortened aryepiglottic folds and excess floppy arytenoid mucosa. These patients underwent endoscopic excision of the cyst without epiglottoplasty.

Postoperative endoscopic examination of Patients 3 and 4 revealed improvements in posterior displacement of epiglottis, eliminating the need for additional epiglottoplasty. Additional supraglottoplasty was required only in Patient 2 due to laryngomalacia which obstructed the laryngeal inlet. Two similar case scenarios were previously reported in which the authors performed supraglottoplasty following VC resection.^[12,13] Of 28 patients with congenital VC included in a study carried out by Tsai et al.,^[11] only one patient underwent additional supraglottoplasty after marsupialization due to persistent life-threatening symptoms. Most patients with type 3 laryngomalacia exhibited improved symptoms after endoscopic cyst excision. However, in type 1 laryngomalacia, endoscopic cyst excision procedure was not as rapid in improving the condition of patients, due to persisting arytenoid prolapsus.^[12] Taken together, we can conclude that, in cases of coexisting type 1 laryngomalacia in whom the symptoms are severe and persistent, supraglottoplasty should be performed as the optimal course of treatment.

In the differential diagnosis of vallecular masses, it is a must to examine the region directly (usually either fiberoptic nasal endoscopy or rigid laryngoscopy/bronchoscopy is performed in the operating room). In some cases, if the epiglottis is distorted and posteriorly displaced, it may not be possible to visualize vallecular masses in infants and children using flexible endoscopy. In our series, when Patient 3 was initially examined with flexible endoscopy, we were unable to recognize the vallecular mass. As the patient's symptoms increased in severity despite medical treatment, another flexible endoscopic examination was required and a vallecular spherical cyst was identified. Subsequently, the patient underwent surgical cyst excision.

Computed tomography (CT) and MRI can be utilized to differentiate between VCs and other vascular lesions, such as hemangioma and vascular rings. Furthermore, CT and MRI are useful in identifying the size, location, and extension of cyst. When an MRI is performed under sedation, it is critical to have an experienced team consisting of neonatal nurses,

MRI technoradiologists, and anesthesiologists. The team should be aware that sedation may cause hypoxemia, bradycardia, hypotension, and laryngospasm.^[14] In this case series, MRI was performed in only Patient 1 and revealed an oval shaped cystic lesion at the base of tongue. Endoscopic methods that secure airway and identify other pathologies are preferred to imaging studies which require sedation and a proficient team.

Patients with VCs can prove challenging to anesthesia teams, and preparation guidelines should be adhered to. They should be reminded of difficult intubations, as the epiglottis can be posteriorly situated and distorted by the cyst. Surgery remains the primary course of treatment for VCs. Surgical treatment options include needle aspiration, transoral endoscopic excision or marsupialization and de-roofing with CO₂ laser or microdebrider.^[15] Leibowitz et al.^[16] initially treated three of 11 VC patients by applying the needle aspiration method. However, these three patients suffered from recurrences eventually requiring a de-roofing procedure. Needle aspiration method is not recommended due to the high recurrence rate, although it may be used to secure the airway in case of sudden upper airway obstruction.^[17] Tsai et al.^[11] reported 28 patients who underwent endoscopic CO₂ laser marsupialization and concluded that the procedure was an effective and safe treatment for VCs.

Furthermore, in published case series by Ku^[17] and Gutiérrez et al.,^[18] no patients had recurrence following CO₂ laser excision and marsupialization (n=4 and n=8, respectively). Leibowitz et al.^[16] also reported a retrospective review of 11 patients with congenital VCs who underwent different procedures including incision & drainage, laser de-roofing, and complete excision. The authors observed recurrence in three patients and concluded that recurrence rate did not appear to depend on whether the cyst was excised completely or marsupialized. In the present study, three of the four patients underwent transoral endoscopic excision without a meticulous removal of all external lining epithelium. The symptoms of all our three patients who underwent surgery improved dramatically and no recurrence was observed.

The limitation of this study is the fact that it is retrospective study with limited number of subjects.

In conclusion, congenital VC is a rare pathology. Its diagnosis requires a high index of clinical suspicion. The symptoms are almost identical to any upper airway obstruction pathologies. Therefore, differential diagnosis is diverse. A distorted and posteriorly located epiglottis is common in laryngomalacia, but it is noteworthy that a cystic mass at the root of the tongue can also replace the epiglottis. Our study results suggest that transoral endoscopic excision is a safe, effective, and feasible surgical procedure to prevent the recurrence of VC.

Declaration of conflicting interests

The authors declared no conflicts of interest with respect to the authorship and/or publication of this article.

Funding

The authors received no financial support for the research and/or authorship of this article.

REFERENCES

1. Raftopoulos M, Soma M, Lowinger D, Eisman P. Vallecular cysts: a differential diagnosis to consider for neonatal stridor and failure to thrive. *JRSM Short Rep* 2013;4:29.
2. Romak JJ, Olsen SM, Koch CA, Ekbom DC. Bilateral vallecular cysts as a cause of Dysphagia: case report and literature review. *Int J Otolaryngol* 2010;2010:697583.
3. Khashu M, Osiovich H, Kozak F, Pelligra G, Hirsh D, Smyth J. Congenital epiglottic cyst presenting with severe airway obstruction at birth. *J Perinatol* 2006;26:71-2.
4. Oelsen JM, Hewett KM, Discolo CM, Jackson BF. Congenital Vallecular Cyst as a Cause of Neonatal Stridor and Apnea. *Pediatr Emerg Care* 2018;34:e152-e154.
5. Li Y, Irace AL, Dombrowski ND, Perez-Atayde AR, Robson CD, Rahbar R. Vallecular cyst in the pediatric population: Evaluation and management. *Int J Pediatr Otorhinolaryngol* 2018;113:198-203.
6. Tuncer U, Aydoğan LB, Soyulu L. Vallecular cyst: a cause of failure to thrive in an infant. *Int J Pediatr Otorhinolaryngol* 2002;65:133-5.
7. Yao TC, Chiu CY, Wu KC, Wu LJ, Huang JL. Failure to thrive caused by the coexistence of vallecular cyst, laryngomalacia and gastroesophageal reflux in an infant. *Int J Pediatr Otorhinolaryngol* 2004;68:1459-64.
8. Gogia S, Agarwal SK, Agarwal A. Vallecular cyst in neonates: case series-a clinicosurgical insight. *Case Rep Otolaryngol* 2014;2014:764860.
9. Prowse S, Knight L. Congenital cysts of the infant larynx. *Int J Pediatr Otorhinolaryngol* 2012;76:708-11.
10. Cheng SS, Forte V, Shah VS. Symptomatic congenital vallecular cyst in a neonate. *J Pediatr* 2009;155:446.
11. Tsai YT, Lee LA, Fang TJ, Li HY. Treatment of vallecular cysts in infants with and without coexisting laryngomalacia using endoscopic laser marsupialization: fifteen-year experience at a single-center. *Int J Pediatr Otorhinolaryngol* 2013;77:424-8.
12. Wong KS, Li HY, Huang TS. Vallecular cyst synchronous with laryngomalacia: presentation of two cases. *Otolaryngol Head Neck Surg* 1995;113:621-4.
13. McClurg FL, Evans DA. Laser laryngoplasty for laryngomalacia. *Laryngoscope* 1994;104:247-52.
14. Snyder EJ, Zhang W, Jasmin KC, Thankachan S, Donnelly LF. Gauging potential risk for patients in pediatric radiology by review of over 2,000 incident reports. *Pediatr Radiol* 2018;48:1867-74.
15. Hsieh WS, Yang PH, Wong KS, Li HY, Wang ECR, Yeh TF. Vallecular cyst: An uncommon cause of stridor in newborn infants. *Eur J Pediatr* 2000;159:79-81.
16. Leibowitz JM, Smith LP, Cohen MA, Dunham BP, Guttenberg M, Elden LM. Diagnosis and treatment of pediatric vallecular cysts and pseudocysts. *Int J Pediatr Otorhinolaryngol* 2011;75:899-904.
17. Ku AS. Vallecular cyst: report of four cases--one with co-existing laryngomalacia. *J Laryngol Otol* 2000;114:224-6.
18. Gutiérrez JP, Berkowitz RG, Robertson CF. Vallecular cysts in newborns and young infants. *Pediatr Pulmonol* 1999;27:282-5.