

# Acute deep vein thrombosis in a patient with mild COVID-19 infection: An unusual case report

 Sena Tolu<sup>1</sup>,  Aylin Rezvani<sup>1</sup>,  Atalay Karakaya<sup>2</sup>,  Abdulkadir Eren<sup>3</sup>,  Pelin Basim<sup>4</sup>

<sup>1</sup>Medipol University Faculty of Medicine, Department of Physical Medicine and Rehabilitation, Istanbul, Turkey

<sup>2</sup>Medipol University Faculty of Medicine, Department of Cardiovascular Surgery, Istanbul, Turkey

<sup>3</sup>Medipol University Faculty of Medicine, Department of Radiology, Istanbul, Turkey

<sup>4</sup>Medipol University Faculty of Medicine, Department of General Surgery, Istanbul, Turkey

Copyright © 2020 by authors and Annals of Medical Research Publishing Inc.

## Abstract

An outbreak of a new type coronavirus (COVID-19) disease firstly emerged in Wuhan City, China in December 2019, rapidly spreads across the globe. COVID-19 predisposes a procoagulant state in severe COVID-19 cases with a significant increase in the incidence of venous thromboembolism, including both pulmonary embolism and deep vein thrombosis that appear to be associated with excessive inflammation, hypoxia, immobilization, and diffuse intravascular coagulation. As the thromboembolic risk of COVID-19 patients at home is not known, a risk assessment model for thrombosis may also be considered in these patients. Herein, we present a patient with mild COVID-19 infection who developed acute deep vein thrombosis.

**Keywords:** COVID-19, deep vein thrombosis, thromboprophylaxis

## INTRODUCTION

An outbreak of a new type coronavirus (COVID-19) disease firstly emerged in Wuhan City, China in December 2019, rapidly spreads across the globe, with 3.5 million confirmed cases and nearly 243.500 deaths worldwide (as at May 2020 data) (1,2). Although most of the critical symptoms arising in the course of this viral illness are of respiratory origin, COVID-19 associated coagulopathy with a prominent elevation of D-dimer and fibrin-fibrinogen degradation products can lead to multiorgan failure in critically ill patients (3). The prothrombotic character of COVID-19 infection with a high risk of venous and arterial thromboembolism appears to be associated with excessive inflammation, hypoxia, immobilization, and diffuse intravascular coagulation (3-5). Because of the risk of thromboembolism and disseminated intravascular coagulation, studies have been conducted to validate the anticoagulant therapy mainly with low molecular weight heparin (LMWH) in hospitalized patients (6-9). There are recently released algorithms for anticoagulant therapy in inpatient settings, especially for critically ill patients (5-7). From Turkey, a recommendation guide regarding DVT prophylaxis and treatment approaches for the uninfected population, and follow-up of outpatients diagnosed with

acute DVT during the COVID-19 outbreak were published (9). Few data are available on the rate and characteristics of thromboembolic events in ambulatory patients with COVID-19. The purpose of reporting this case is to highlight that deep vein thrombosis (DVT), a commonly reported thrombotic process in hospitalized patients with severe COVID-19, may need vigilance and prophylaxis due to its life-threatening consequences in outpatients with COVID-19.

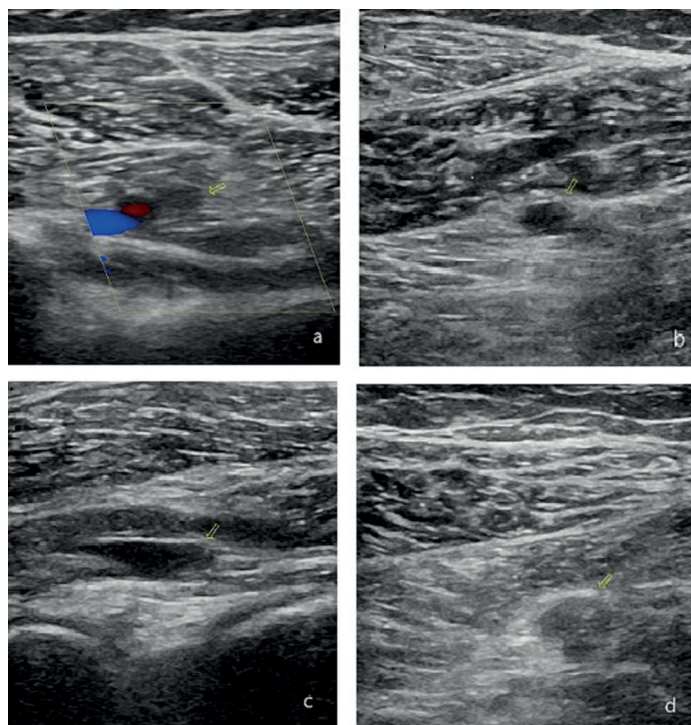
## CASE REPORT

A 31-year-old male patient presented to the Physical Medicine and Rehabilitation outpatient clinic with complaints of excessive pain and swelling of the left lower leg for the last three days. Two weeks before admission, he was diagnosed with COVID-19 infection and was treated by oseltamivir phosphate 75 mg BID for five days and hydroxychloroquine sulfate 400mg BID on day 1, followed by 200mg BID on day 2-5. One week after recovery, he noted a painful and swollen left calf. On examination, the patient had a severely painful calf in the left knee and ankle plantar flexion with no other abnormalities in musculoskeletal evaluation. The review of other systems and his past medical history was unremarkable with

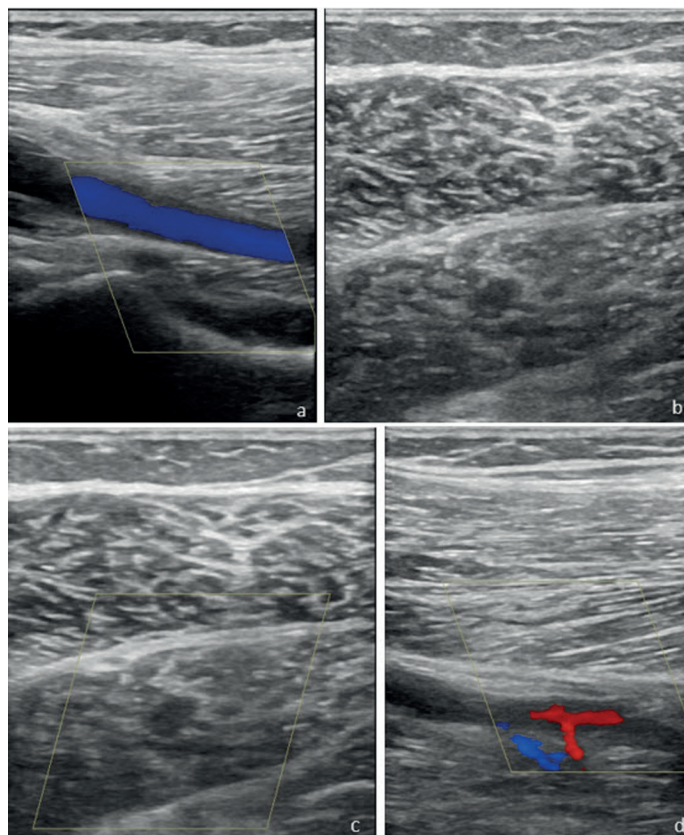
**Received:** 03.05.2020 **Accepted:** 28.09.2020 **Available online:** 23.10.2020

**Corresponding Author:** Sena Tolu, Medipol University Faculty of Medicine, Department of Physical Medicine and Rehabilitation, Istanbul, Turkey, **Email:** dr.sena2005@gmail.com

any obvious sign of trauma. He was on no medications at the moment. He had no risk factors that would make him prone to thrombosis. His vital signs were within normal limits, with no tachycardia, fever, or respiratory distress. A lower extremity venous Doppler ultrasound revealed an occlusive thrombus in left popliteal and deep perforating veins by detecting the non-compressibility of the thrombosed vein with disturbed blood flow due to complete occlusion. Complete blood count was normal. Coagulation test screening showed significantly elevated D-dimer and fibrinogen levels, 3765 ng/ml, and 910 mg/dl respectively. As the findings were consistent with DVT (Figure 1), he was consulted with Cardiovascular Surgery clinic and thrombolytic therapy (LMWH, 6000 IU twice daily ) was administered for 10 days. On the 10th day of the therapy, the patient's calf pain had decreased along with a significant reduction in diameter difference of lower extremities. The patient was transitioned to rivaroxaban, 20 mg/d, for long term use, at least 3 months. At his 3rd week follow-up, there remained no clinical signs of DVT and Doppler ultrasound showed a partial recanalization of popliteal and perforating veins (Figure 2). Coagulation tests depicted a gradual improvement, with a D-dimer level of 388 ng/ml and fibrinogen level 216 mg/dl within normal ranges. The patient has been currently still under Cardiovascular Surgery clinical follow-up with no active complaint. A written informed consent was obtained from the patient.



**Figure 1.** (a) Absence of flow in deep perforating veins and in slight flexion, (b) hypoechoic thrombus in the deep perforating vein lumen, (c) hypoechoic thrombus in the popliteal vein lumen, (d) hypoechoic thrombus in the popliteal vein lumen



**Figure 2.** (a) Flow coding is observed in the popliteal vein after treatment, (b) Thrombus is still seen in some places in deep perforating veins, (c) Stream coding is not observed in CDUS examination, (d) In deep perforating veins, recanalized flow codes are observed from place to place.

## DISCUSSION

COVID-19 infection is associated with a wide variety and misleading spectrum of symptoms and complications including a significant tendency to coagulopathy. The interim guidance released by The International Society of Thrombosis and Haemostasis (ISTH) proposed a conventional prophylactic daily enoxaparin dose of 4000 IU to prevent VTE for hospitalized patients and especially critically ill patients with COVID-19 (7). The initial coagulopathy of COVID-19 presents with a significant increase in D-Dimer and fibrinogen levels and seems to be an important indicator of prognosis and mortality. The established practice of using thromboprophylaxis for critically ill patients with COVID-19 can contribute to help the critical burden of coagulopathy in intensive care units (ICU). However mild or asymptomatic cases of COVID-19 may face a similar risk of thromboembolism even with a more insidious progression especially if the patient has no known prothrombotic risk factors (6). This emerging evidence challenges with the prediction of the high risk of thromboembolism in ICU because of the patient (age, obesity, cancer, sepsis, respiratory and heart failure) and ICU-specific (sedation, immobilization, vasopressors and central venous catheters) factors. Endothelial damage, microvascular thrombosis, and occlusion, or even autoimmune mechanisms were accounted as additional

mechanisms contributory to thromboembolism (8).

Günertem et al. recently published a recommendation guide including the thromboprophylaxis and management of uninfected people diagnosed with acute DVT during the COVID-19 outbreak (9). However, there has been no recommendation for outpatients with mild COVID-19 infection without any risk factors in the literature. While thromboprophylaxis for all patients seems not effective, a risk prediction model for DVT and treatment and follow-up algorithms may be developed for outpatients in home-quarantine. Monitoring the D-dimer plasma level may be useful to recognize the increased risk of thromboembolism in outpatients with COVID-19. A more aggressive individualized follow-up strategy might be also required in some selected ambulatory cases according to risk factors. Increasing patient recognition of serious adverse effects of COVID-19 infection, such as DVT, may be helpful in the early detection of thrombotic events.

*Conflict of interest: The authors declare that they have no competing interest.*

*Financial Disclosure: There are no financial supports.*

*Patient informed consent : Written informed consent was obtained from the patient for the publication of the case report and the accompanying images.*

## REFERENCES

1. Huang C, Wang Y, Li X, et al. Clinical features of patients infected with 2019 novel coronavirus in Wuhan, China. Lancet 2020;395:497–506.

2. WHO Updates, Daily Dashboard. Available at: <https://covid19.who.int>. accessed date May 06, 2020.
3. Kollias A, Kyriakoulis KG, Dimakakos E, et al. Thromboembolic risk and anticoagulant therapy in COVID-19 patients: emerging evidence and call for action [published online ahead of print, 2020 Apr 18]. Br J Haematol 2020;10.1111/bjh.16727.
4. Zhou F, Yu T, Du R, et al. Clinical course and risk factors for mortality of adult inpatients with COVID-19 in Wuhan, China: a retrospective cohort study. Lancet 2020;395:1054–62.
5. Bikdeli B, Madhavan MV, Jimenez D, et al. COVID-19 and thrombotic or thromboembolic disease: implications for prevention, antithrombotic therapy, or follow-up. JACC, 2020,
6. Tang N, Bai H, Chen X, et al. Anticoagulant treatment is associated with decreased mortality in severe coronavirus disease 2019 patients with coagulopathy. J Thromb Haemost 2020;18:1094-9.
7. Thachil J, Tang N, Gando S, et al. ISTH interim guidance on recognition and management of coagulopathy in COVID 19. J Thromb Haemost 2020;18:1023-6.
8. Kollias A, Kyriakoulis KG, Dimakakos E, et al. Thromboembolic risk and anticoagulant therapy in COVID-19 patients: emerging evidence and call for action. Br J Haematol 2020;10.1111/bjh.16727.
9. Günertem E, Akay T, Aliyev A, et al. Treatment and prophylaxis strategies for deep vein thrombosis during COVID-19 outbreak. Turk J Vasc Surg 2020;29(x):i-v.