

# Treatment of genital herpes using olive leaf extract

Nahid Lorzadeh<sup>1</sup>  | Yasaman Kazemirad<sup>2</sup> | Nastran Kazemirad<sup>3</sup>

<sup>1</sup>Department of Obstetrics and Gynecology, Faculty of Medicine, Lorestan University of Medical Sciences, Khorramabad, Iran

<sup>2</sup>Faculty of Dentistry, Medipol University, Istanbul, Turkey

<sup>3</sup>Faculty of Medicine, Tehran University of Medical Sciences, Tehran, Iran

## Correspondence

Nahid Lorzadeh, Lorestan University of Medical Sciences, Khorramabad, Iran.  
Email: dr.n.lorzadeh@gmail.com

## Abstract

Genital herpes is one of the sexually transmitted diseases that is reported with a greater incidence of primary and secondary recurrence. In this study, olive leaf extract was used for its antiviral properties to treat the infection. The randomized-clinical trials using such a therapeutic approach are required in this field.

## KEYWORDS

acyclovir, antiviral, genital herpes, infection, olive leaf extract

## 1 | INTRODUCTION

Genital herpes is one of the most commonly reported sexually transmitted infections (STI) that is associated with a greater incidence of recurrence and does not respond to conventional treatments. Type I and II viruses are involved in the pathogenesis of the disease where it affects lips, face, and genitals.<sup>1</sup>

The infection begins with irritation and itching followed by pain up to 24 hours, after which the virus widespread to sensory nerves.<sup>2</sup> Due to the weakening of the immune system, the virus in the sensory nerves returns to the surface of the skin to cause reinfection. Factors that can worsen the infection include stress, fatigue, cold wind, burn, loss of immunity, infection, fever, and cold, to name few.<sup>3</sup> The symptoms usually last 4-7 days after the first contact with the virus carrying virus or virus-containing secretions.<sup>4</sup> The most common symptom of the disease is the appearance of small blisters in the genital area that when puncture, produce painful ulcers. Some people may find only red or prominent lesions, and some are likely to be presented with painful urination.<sup>5</sup> In women, vaginal vesiculate secretions may also be observed. Urination, with clear watery secretions from the urethra, is often a known complication of the infection. Ulceration usually occurs 4-7 days after the first infection, and the symptoms are similar to that of cold, such as fever, sore throat, and lumbago swelling.<sup>6</sup>

Conventional treatment for herpes includes antiviral drugs, which inhibit the replication of viral RNA.<sup>4</sup> These drugs include acyclovir, ganciclovir, valaciclovir, and penciclovir. The overuse of drugs has led to drug resistance.<sup>7</sup> On the other hand, they are not cost-effective, owing to the long course of treatment.<sup>8</sup> Currently, two herbal remedies, Melissa and Myrtoplex, are used in Iran.<sup>9</sup> Herbal medicine is currently under investigation for its effectiveness in the treatment of the herpes virus. Studies have indicated that plants and derived compounds can be used to treat herpes viruses.<sup>10,11</sup>

Olive extracts are reported to be effective against various pathological conditions. Polyphenolic compounds, including oleuropein (OLE) and hydroxytyrosol (HT), are active ingredients in olive leave extracts. In this report, we present a case of acyclovir-resistant herpes that was reported to our center, due to the severity of the symptoms. Olive leaf extract ointment led to the patient recovery in 48 hours.

## 2 | OLIVE LEAF EXTRACTION METHOD

Olive leaves were collected in Mid-November and dried at ambient room temperature, and the powdered extract was stored in dark until further usage. The powder was dissolved in 100 mL of extraction solvent that was made of 80% ethanol

This is an open access article under the terms of the Creative Commons Attribution-NonCommercial-NoDerivs License, which permits use and distribution in any medium, provided the original work is properly cited, the use is non-commercial and no modifications or adaptations are made.

© 2020 The Authors. *Clinical Case Reports* published by John Wiley & Sons Ltd.

at 60°C. The mixture was filtered using Whatman filter paper NO: 1. The extract was evaporated at room temperature under vacuum conditions. The leaves were obtained at the best possible time of the year, which had the highest amount of active ingredients; washed, dried, and hydroalcoholic extract was extracted. The extract analysis using the HPLC showed that the active ingredient, oleuropein, was 0.475 mg/g of the total extract. The ointment was prepared in 2% and was provided to the patient.

### 3 | CASE REPORT

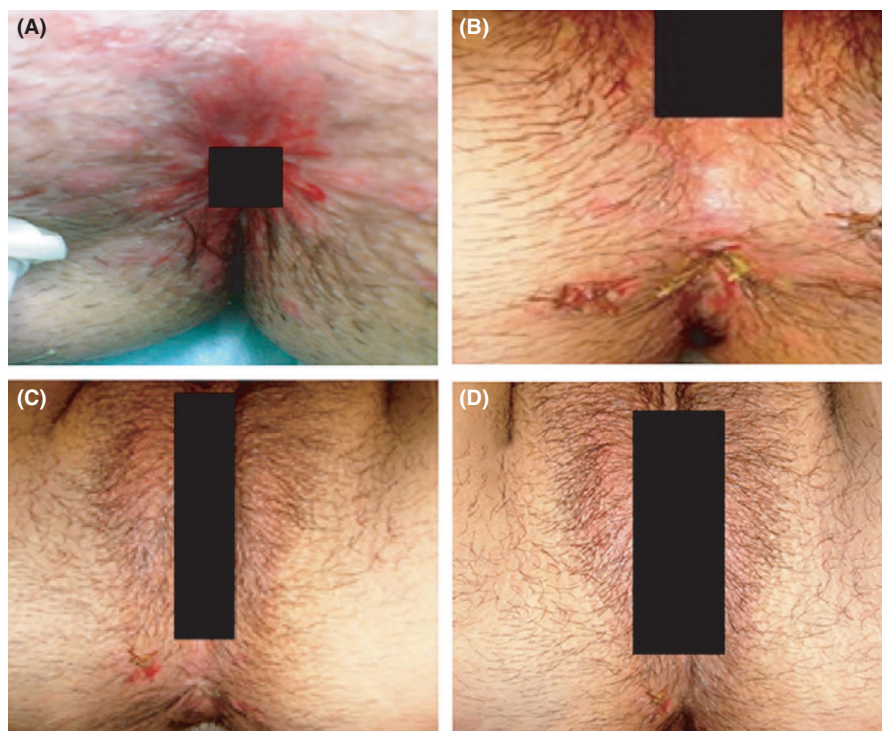
The patient was a married 19-year-old woman with multiple mucocutaneous, round polycyclic lesions in the perineal region, dysuria and had severe burning sensations and pain, especially during defecation and her vulva was inflamed with swollen and tender inguinal lymph node. She reported that the appearance of the lesion started a week before her referral. Her husband (only sexual partner) did not have any such lesions, and she did not have any travel history for past 6 months. She visited her gynecologist for pap test 4 months ago. No other body part had lesions or rashes. The patient was healthy otherwise and did not have any medical or surgical history. The patient was referred to Asali Women's Hospital. During this period, the patient underwent multiple visits to general practitioners and general surgery specialists with a primary diagnosis of anal fissure. Her blood chemistry did not show any abnormality in exception to increased white blood cell counts: 15 000/mm<sup>3</sup>. During her referral to dermatologist, she was diagnosed with herpes infection from lesion

biopsy, PCR test, and serologic tests for herpes glycoprotein (ELISA) and was treated with acyclovir ointment. At this time, her husband was not tested positive for the infection. Nonetheless, the patient did not respond to the treatment and was known to be a case of acyclovir-resistant herpes infection. She was thereby, treated with the localized application of topical olive leaf extract, twice a day, owing to the lesion biopsy reports. The response to this treatment was evaluated on day 3 and 6, and 2 weeks after treatment. Following 3 days of the treatment, the pain and wounds completely disappeared whereas the lesions of the perineal and rectal areas were completely recovered on day 6, and after 2 weeks of follow-up, no relapse was observed (Figure 1).

Written consent of the patient was obtained from the patient for this study.

### 4 | DISCUSSION

Herpes infection is one of the most common STI, worldwide. Acyclovir ointment and creams are usually used for the treatment of the infection. However, cases of acyclovir resistance and related agents have been reported widely, as a result of thymidine kinase deficiency. Hence, alternative drugs are used for the treatment. Some researchers, in addition to direct antiviral effects, seek to boost the immune system against these viruses. Recently, *Olea Europae* plant with antibacterial, antifungal, and antiviral effects has been reported for immune-boosting effects to treat HSV infection.<sup>12,13</sup> Similarly, imiquimod, as an immune-modifier, is also used for the purpose.<sup>14</sup>



**FIGURE 1** A, Indicates a first-day lesion before treatment. B, indicates a third-day post-treatment lesion. C, indicates a lesion on day 6 after treatment. D, indicates a lesion 2 wk after treatment

In vivo studies have shown the efficacy of olive leaves extract against HSV-1.<sup>15</sup> The application of olive leaf extract is also indicated for the treatment of HSV.<sup>16</sup> In a patent, it has been pointed out that the olive leaf extract in six patients with herpes genitalis eliminated lesions in three of them after 48 hours and in a patient after 72 hours. The remaining two patients showed 66% improvement.<sup>17</sup> Oleuropein is one of the active phenolic compounds in olive leaves that is known for the treatment of cancer, microbes, viruses, and hyperlipidemia. It is effective against rotavirus, hepatitis, parvovirus, influenza virus, herpes, and human immunodeficiency viruses. Furthermore, anti-inflammatory and analgesic effects are also reported.<sup>18</sup>

In this case, we have reported the treatment of herpes simplex virus infection using olive leaf extract in an acyclovir-resistant patient. It was seen that the ointment with the 2% of the extract can control itching, bleeding, and pain. It was also effective against the lesions, similar to acyclovir. These outcomes are likely to direct cost-effective methods for treating herpes using herbal medicine with low-to-no adverse effects. Therefore, further clinical studies are recommended in the area.

## 5 | CONCLUSION

Olive leaf extracts are the potential antiviral compounds that can be used to treat genital herpes.

### CONFLICT OF INTEREST

The authors deny any conflict of interest in any terms or by any means during the study.

### AUTHOR CONTRIBUTIONS

Dr NL: conceptualized and designed the study, drafted the initial manuscript, and reviewed and revised the manuscript. Dr NK: designed the data collection instruments, collected data, carried out the initial analyses, and reviewed and revised the manuscript. Dr YK: coordinated and supervised data collection, and critically reviewed the manuscript for important intellectual content.

### ETHICAL APPROVAL

All procedures performed in this study involving human participants were in accordance with the ethical standards of the institutional and/or national research committee and with the 1964 Helsinki Declaration and its later amendments or comparable ethical standards.

### CONSENT FOR PUBLICATION

Not applicable.

### DATA AVAILABILITY STATEMENT

Data sharing is not applicable to this article as no datasets were generated or analyzed during the current study.

### ORCID

Nahid Lorzadeh  <https://orcid.org/0000-0003-1492-8582>

### REFERENCES

- Lorzadeh N, Sepavand F, Soleimaninezhad M, Kazemirad N. The effect of extract of oak gall for vaginal tightening and rejuvenation in women with vaginal relaxation. *Open J Obstet Gynecol*. 2016;6(13):879-887.
- Akbariasbagh F, Lorzadeh N, Azmoodeh A, Ghaseminejad A, Mohamadpoor J, Kazemirad S. Association among diameter and volume of follicles, oocyte maturity, and competence in intracytoplasmic sperm injection cycles. *Minerva Ginecol*. 2015;67(5):397-403.
- Whitley RJ, Roizman B. Herpes simplex virus infections. *Lancet*. 2001;357(9267):1513-1518.
- Lorzadeh N, Ghasem Nejad A, Mohamad Pour J. The effect of metformin on outcome of intrauterine insemination (IUI) in insulin non-resistant infertile women with polycystic ovarian syndrome. *Iran J Obstet Gynecol Infertil*. 2014;17(128):1-11.
- Lorzadeh N, Kazemirad S, Lorzadeh M, Najafi S. Comparison of the effect of oral and intravenous fluid therapy on women with oligohydramnios. *Res J Obstet Gynecol*. 2008;1(1):25-29.
- Lorzadeh N, Samimi S, Birjandi M. Association of fetal gender with maternal serum  $\beta$ -hCG and testosterone in normotensive and preeclamptic pregnancies. *Iran J Obstet Gynecol Infertil*. 2010;13(1):13-19.
- Whitley RJ, Kimberlin DW, Roizman B. Herpes simplex viruses. *Clin Infect Dis*. 1998;541-553.
- Khan MTH, Ather A, Thompson KD, Gambari R. Extracts and molecules from medicinal plants against herpes simplex viruses. *Antiviral Res*. 2005;67(2):107-119.
- Lorzadeh N, Sepavand F, Soleimaninezhad M, Kazemi RN. The effect of extract of internal layer of quercus (OAK GAL) in contraction of vaginal smooth muscles in women with vaginal relaxation. 2016.
- Chattopadhyay D, Khan MTH. Ethnomedicines and ethnomedicinal phytophores against herpesviruses. *Biotechnol Annu Rev*. 2008;14:297-348.
- Chattopadhyay D, Naik TN. Antivirals of ethnomedicinal origin: structure-activity relationship and scope. *Mini Rev Med Chem*. 2007;7(3):275-301.
- Sudjana AN, D'Orazio C, Ryan V, et al. Antimicrobial activity of commercial *Olea europaea* (olive) leaf extract. *Int J Antimicrob Agents*. 2009;33(5):461-463.
- Lee O-H, Lee B-Y. Antioxidant and antimicrobial activities of individual and combined phenolics in *Olea europaea* leaf extract. *Biores Technol*. 2010;101(10):3751-3754.
- Perkins N, Nisbet M, Thomas M. Topical imiquimod treatment of acyclovir-resistant herpes simplex disease: case series and literature review. *Sex Transm Infect*. 2011;87(4):292-295.
- Motamedifar M, Nekooeian A, Moatari A. The effect of hydroalcoholic extract of olive leaves against herpes simplex virus type 1. *Iran J Med Sci*. 2015;32(4):222-226.

16. Hsu PP. Natural medicines comprehensive database. *J Med Libr Assoc.* 2002;90(1):114.
17. Fredrickson WR. Method and composition for antiviral therapy. 2002. Google Patents.
18. Omar SH. Oleuropein in olive and its pharmacological effects. *Sci Pharm.* 2010;78(2):133-154.

**How to cite this article:** Lorzadeh N, Kazemirad Y, Kazemirad N. Treatment of genital herpes using olive leaf extract. *Clin Case Rep.* 2021;9:986–989. <https://doi.org/10.1002/ccr3.3723>