

Effects of dexamethasone treatment on serous retinal detachment in ranibizumab-resistant diabetic macular edema

Alper Halil Bayat  and Mustafa Nuri Elçioğlu

Ther Adv Ophthalmol

2020, Vol. 12: 1–7

DOI: 10.1177/
2515841420971936

© The Author(s), 2020.
Article reuse guidelines:
sagepub.com/journals-
permissions

Abstract

Purpose: To evaluate outcome of intravitreal dexamethasone implant (IDI) treatment on serous retinal detachment (SRD) in patients with ranibizumab-resistant diabetic macular edema (DME).

Materials and methods: Forty-eight eyes of 48 patients with DME resistant to ranibizumab were enrolled in this retrospective and comparative study. Patients were divided into two groups according to presence of serous retinal detachment: (1) SRD or (2) non-SRD groups. All patients had at least three monthly ranibizumab injections, after which they were treated with IDI. The best-corrected visual acuity (BCVA), central retinal thickness (CRT), use of antiglaucomatous drugs, and presence of cataract progression were noted at 1, 3, and 6 months post-IDI treatment.

Results: There was not any statistically significant difference in terms of baseline characteristics of the patients. The mean CRT was declined in both groups at 1, 3, and 6 months ($p < 0.001$). After IDI treatment, the mean BCVA was improved in both groups at 1, 3, and 6 months ($p < 0.001$). When groups were compared, the change in CRT was higher in the SRD group ($p = 0.018$), while there was no statistically significant difference between groups in terms of BCVA changes ($p = 0.448$).

Conclusion: The presence of SRD resulted in higher anatomical gain. SRD had no effects on visual changes after dexamethasone treatment in patients with ranibizumab-resistant DME.

Keywords: dexamethasone implantation, diabetic macular edema, optical coherence tomography, ranibizumab, serous retinal detachment

Received: 15 May 2020; revised manuscript accepted: 16 October 2020.

Introduction

Diabetic macular edema (DME) is the main cause of vision loss in diabetic patients.¹ Ten years after diabetes mellitus was first diagnosed, 20% of the patients were found to be affected by DME.² In recent years, the development of different technologies, such as optical coherence tomography (OCT), can demonstrate the presence of DME. Several patterns of DME, such as serous macular detachment (SRD), cystoid macular edema (CME), and diffuse retinal thickening (DRT), have been identified on OCT images.^{3–6} DME can also be a mixture of these three patterns. SRD is different from others due to its pathogenesis, which is caused by breakdown of the outer

blood-retinal barriers. DRT and CME are mainly caused by dysfunction of the inner blood-retinal barriers.^{7–10} Due to differences in pathogenic mechanisms, DME can be divided in two groups: (1) SRD and (2) non-SRD (DRT CME).

Several studies have shown that the DME patterns can affect treatment outcomes. Liu and colleagues compared intravitreal triamcinolone acetonide with intravitreal bevacizumab in DME patients with SRD. In that study, the triamcinolone acetonide group has better functional and anatomical response than bevacizumab group.¹¹ They said this outcome was associated with anti-inflammatory effects of triamcinolone acetonide.

Correspondence to:
Alper Halil Bayat
Department of
Ophthalmology, Esenler
Hospital, Medipol
University, Birlik mah.
Bahçeler cad. No:5,
Esenler, 34083 İstanbul,
Turkey
alperhalil76@hotmail.com
Mustafa Nuri Elçioğlu
Department of
Ophthalmology,
Okmeydanı Training
and Research Hospital,
University of Health
Sciences, İstanbul, Turkey

Shimura and colleagues studied patients with DME who were treated with ranibizumab. In their study, SRD patients had worse functional and anatomical outcomes with ranibizumab treatment than non-SRD patients.¹² Demircan and colleagues¹³ demonstrated that dexamethasone implantation was more useful than ranibizumab in DME with SRD. However, all of the these studies had patients who had treatment-naïve DME. In the current study, we aimed to explain the influence of SRD on the outcome of intravitreal dexamethasone implant (IDI) in patients with ranibizumab-resistant DME.

Methods

This retrospective and comparative study was performed accordance with Declaration of Helsinki. Written informed consents were obtained from all patients. All necessary authorizations were obtained from the Institutional Review Board of Okmeydanı Research and Training Hospital, İstanbul, Turkey with number 751.

Forty-eight eyes of 48 patients with DME resistance to ranibizumab were enrolled in this study. Patients were divided in two groups according to presence of SRD observed on OCT scans: (1) SRD and (2) non-SRD groups. All patients had at least three monthly ranibizumab injections. Reduction of less than 20% central retinal thickness (CRT) on SD-OCT 1 month after third ranibizumab injections was defined as resistant to ranibizumab therapy and treated with intravitreal dexamethasone treatment. Best-corrected visual acuity (BCVA), CRT use of antiglaucomatous drugs, and presence of cataract progression were noted at 1, 3, and 6 months post-IDI treatment. Inclusion criteria were consisted of several parameters: (1) OCT > 250 μm , (2) age > 18 years old, (3) at least three monthly ranibizumab injections, and (4) ranibizumab resistance. Patients with several conditions were excluded as follows: (1) a history of glaucoma, (2) steroid induced ocular hypertension, (3) vitrectomy, (4) other vitreoretinal diseases and retinopathies, (5) corneal opacity, and (6) laser photocoagulation within 6 months prior to study enrollment.

All of the patients had standard ophthalmic examinations pre- and post-treatment (1-, 3-, and 6-month follow-ups and final visit). The examinations included slit-lamb microscopy, BCVA, tonometry, spectral domain OCT (SD-OCT), and indirect ophthalmoscopy. BCVA was measured

with the Snellen chart, and the decimal visual acuity was converted to the logarithm of the minimal angle of resolution (logMAR) units for statistical analyses. The OCT was performed on an SD-OCT (Spectralis, Heidelberg Engineering, Heidelberg, Germany). The CRT was computed 1 mm central diameter area by using OCT mapping software.

All injections were performed in the operating room under aseptic condition with topical anesthesia (0.4% benoxinate). A dexamethasone implant (0.7 mg) (Ozurdex, Allergan Inc. Bayer, Berlin, Germany) was injected with a 22-gauge applicator through the pars plana at 3.5–4 mm posterior of limbus. After injections topical moxifloxacin were given as therapy for one week. After IDI, the patients did not receive any additional treatment for 6 months. IDI was performed 1 month after last ranibizumab injection.

Statistical analyses were performed using the SPSS software version 21. Descriptive analyses were presented using means and standard deviations for normally distributed variables. The change in CMT and BCVA by the time of investigation was performed using repeated measures analysis of variance (ANOVA). A Greenhouse–Geisser correction was used when the sphericity assumption was violated. The Kruskal–Wallis test was conducted to compare non-parametric parameters among the groups. A one-way ANOVA was used to compare parametric parameters among the groups. A p -value < 0.05 was considered to show a statistically significant result.

Results

Twenty-two eyes in the SRD group and 26 eyes in the non-SRD group were examined. The mean age of the patients was 61.4 ± 9.1 years in the SRD group and 64.8 ± 8.9 in the non-SRD group ($p = 0.229$). The mean number of previous ranibizumab injections was 5 ± 1.8 and 5.0 ± 2.8 in the SRD and non-SRD groups, respectively ($p = 0.883$). There was no statistically significant difference between groups in terms of initial BCVA, CMT, glycosylated hemoglobin (HbA1c) levels, and gender ($p = 0.185, 0.148, 0.209,$ and 0.662 , respectively). The baseline characteristics of the patients are shown in Table 1.

The mean initial CRT was $503 \pm 114 \mu\text{m}$ in SRD group and $446 \pm 89 \mu\text{m}$ in the non-SRD group ($p = 0.883$). The mean CRT declined to $270 \pm 56, 257 \pm 54,$ and $309 \pm 107 \mu\text{m}$ in the SRD group

Table 1. The baseline characteristics of the patients.

Parameters	SRD group	Non-SRD group	<i>p</i> value
Age (years)	61.4 ± 9.1	64.8 ± 8.9	0.299
Gender			
Female	11 (50%)	11 (42.4%)	
Male	11 (50%)	15 (57.6%)	0.662
CRT prior to ranibizumab	476 ± 118 µm	466 ± 135 µm	0.821
BCVA prior to ranibizumab	0.78 ± 0.45 logMAR	0.68 ± 0.47 logMAR	0.544
Mean number of ranibizumab injections	5 ± 1.8	5.1 ± 2.8	0.883
CRT prior to IDI	503 ± 114 µm	446 ± 89 µm	0.148
BCVA prior to IDI	0.72 ± 0.47 logMAR	0.97 ± 0.64 logMAR	0.185
Usage of insulin	14 (63%)	15 (57%)	0.678
Mean HbA1c values	7.44 ± 2.08	8.33 ± 1.68	0.209
Mean follow-up time (months)	22.67 ± 6.32	27.31 ± 11.02	0.11

BCVA, best-corrected visual acuity; CRT, central retinal thickness; IDI, intravitreal dexamethasone implantation; SRD, serous retinal detachment.

and 328 ± 63, 296 ± 69, and 353 ± 101 µm in the non-SRD group at 1, 3, and 6 months, respectively ($p < 0.001$). When the groups were compared, the change in CRT was higher in the SRD group ($p = 0.018$). The changes in CRT are displayed in Figure 1 and summarized in Table 2.

The mean BCVAs in the SRD and non-SRD groups were 0.72 ± 0.47 and 0.97 ± 0.64 logMAR, respectively ($p = 0.185$). After IDI treatment, the mean BCVA was 0.62 ± 0.45, 0.56 ± 0.42, and 0.59 ± 0.53 logMAR at 1, 3, and 6 months, respectively, in the SRD group, while it was 0.67 ± 0.52, 0.61 ± 0.51, and 0.65 ± 0.58 logMAR in the non-SRD group at the same time points ($p < 0.001$). There was no statistically significant difference between groups in terms of BCVA changes ($p = 0.448$). The changes in BCVA are displayed in Figure 2 and summarized in Table 2.

OCT samples of the patients in SRD and non-SRD groups were displayed in Figures 3 and 4, respectively.

Two eyes in the SRD group and three eyes in the non-SRD group had to use anti-glaucomatous drugs because of an intraocular pressure elevation.

One eye in each group had cataract progression at the end of the 6-month follow-up.

Discussion

In the current study, we found that IDI was effective in both SRD and non-SRD patterns of DME resistance to ranibizumab treatment with respect to both anatomical and functional gain. SRD patients were found to have faster responses to IDI than non-SRD patients, and the SRD patients presented a better anatomical gain. In terms of visual acuity changes, there was no statistically significant difference between SRD and non-SRD patients.

Previous studies have shown different types of DME patterns, such as SRD, DRT, and CME on OCT scans.³⁻⁶ Each pattern of DME may have a different pathogenesis. For example, SRD is defined as fluid accumulation in the subretinal space as a result of retinal pigment epithelium dysfunction and damage to the external limiting membrane.^{9,10} DRT results from ischemia-induced intracytoplasmic swelling of Müller cells, and if Müller cells have necrosis with cavity formation, CME results.^{7,8}

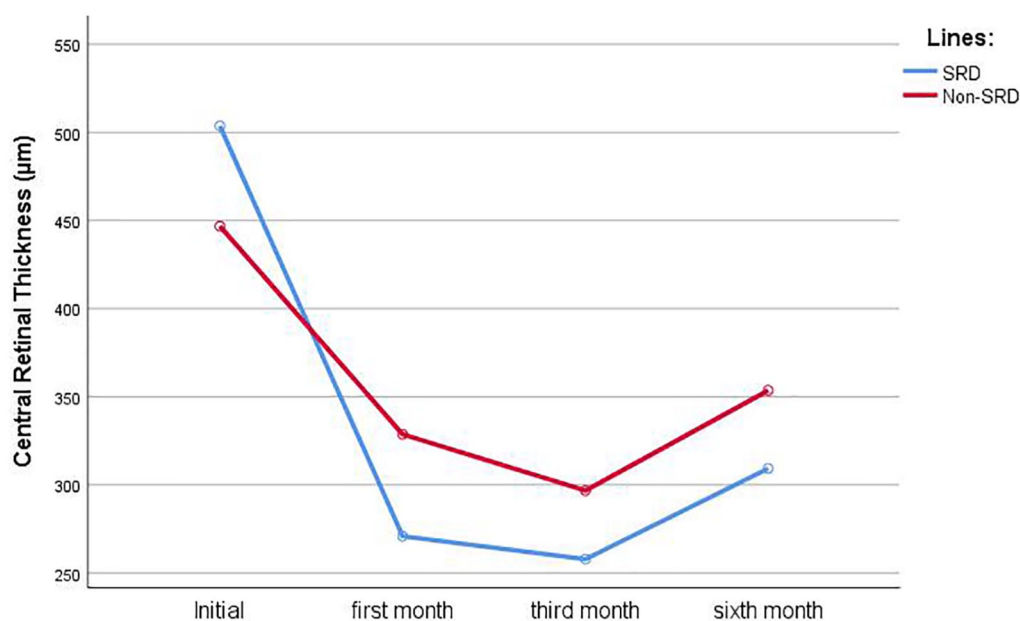


Figure 1. The changes in CRT with time after intravitreal dexamethasone implantation. CRT, central retinal thickness; SRD, serous retinal detachment.

Table 2. Comparison of monthly changes in CRT and BCVA between groups.

Parameter	SRD group	Non-SRD group	p value
Initial CRT	503 ± 114 µm	446 ± 89 µm	0.148
First month CRT	270 ± 56 µm	328 ± 63 µm	0.009*
Third month CRT	257 ± 54 µm	296 ± 69 µm	0.096
Sixth month CRT	309 ± 107 µm	353 ± 101 µm	0.244
Initial BCVA	0.72 ± 0.47 logMAR	0.97 ± 0.64 logMAR	0.185
First month BCVA	0.62 ± 0.45 logMAR	0.67 ± 0.52 logMAR	0.770
Third month BCVA	0.56 ± 0.42 logMAR	0.61 ± 0.51 logMAR	0.742
Sixth month BCVA	0.59 ± 0.53 logMAR	0.65 ± 0.58 logMAR	0.775

BCVA, best-corrected visual acuity; CRT, central retinal thickness; SRD, serous retinal detachment.
*Statistically significant.

Several studies in the current literature aim to explain the effects of treatment modalities on SRD and non-SRD patients. Kim and colleagues studied patients with different DME types who underwent bevacizumab treatment. They reported that bevacizumab injections were more effective in DRT patients than those with SRD or CME.¹⁴ In agreement with their results, Shimura and colleagues¹² also reported that bevacizumab has the lowest effects in the SRD type of DME.

Seo and colleagues⁵ reported that DRT patients had good responses to ranibizumab injections, while the SRD group had the worst visual acuity. They demonstrated that SRD patients had poorer visual gain because of damage to ellipsoid zone integrity. Ozdemir and colleagues¹⁵ reported that SRD was a good predictive factor for DME during intravitreal triamcinolone acetonide treatment. In a recent study, Demircan and colleagues compared ranibizumab and dexamethasone in

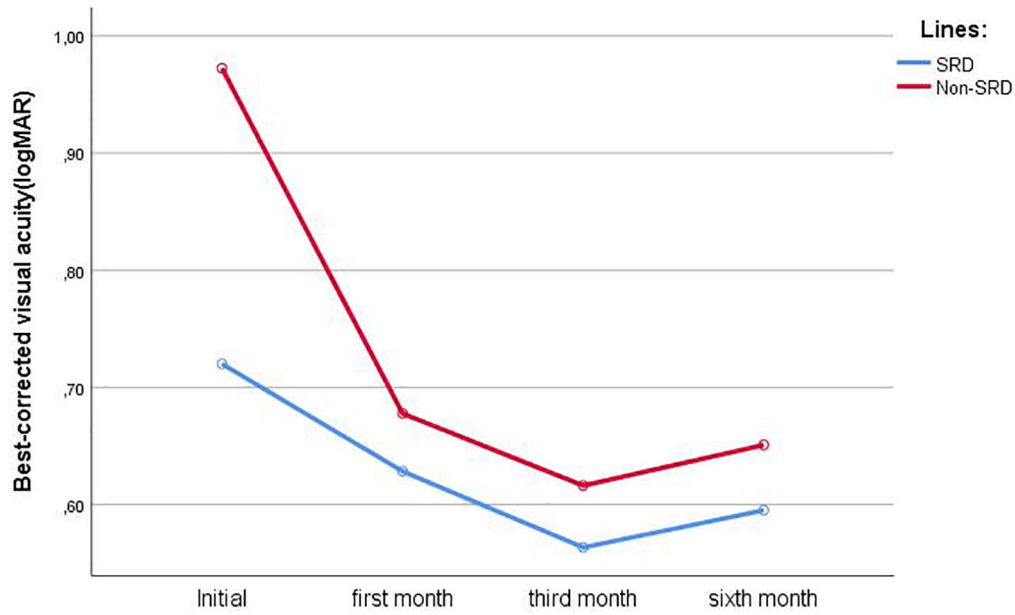


Figure 2. The changes in BCVA with time after intravitreal dexamethasone implantation. BCVA, best-corrected visual acuity; SRD: serous retinal detachment.

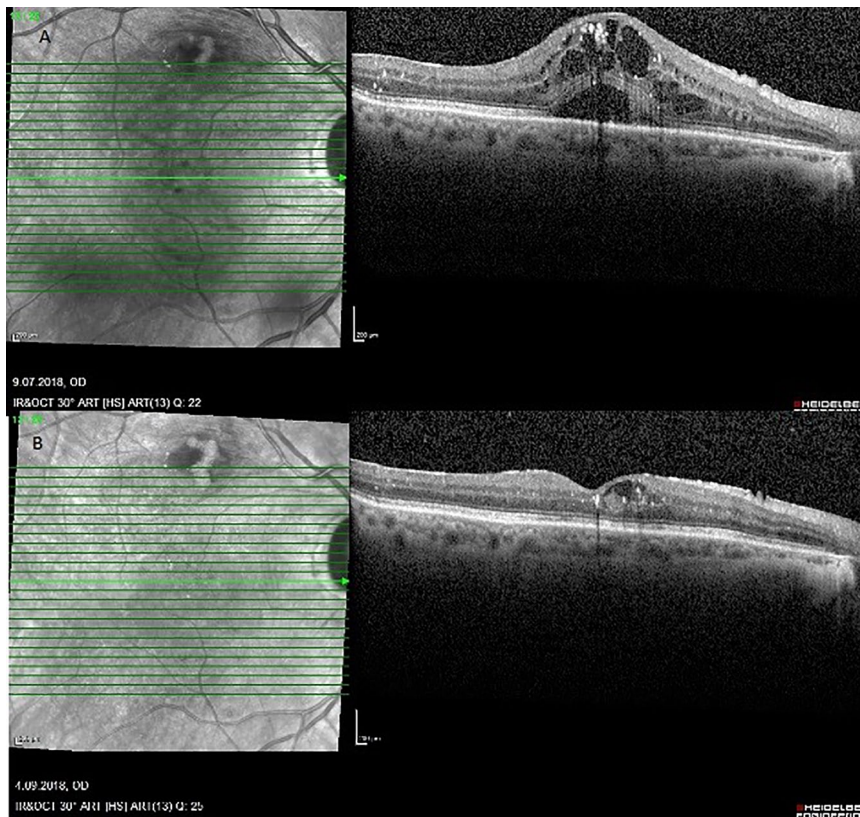


Figure 3. Optical coherence tomography images of a patient with serous retinal detachment before and after intravitreal dexamethasone implantation.

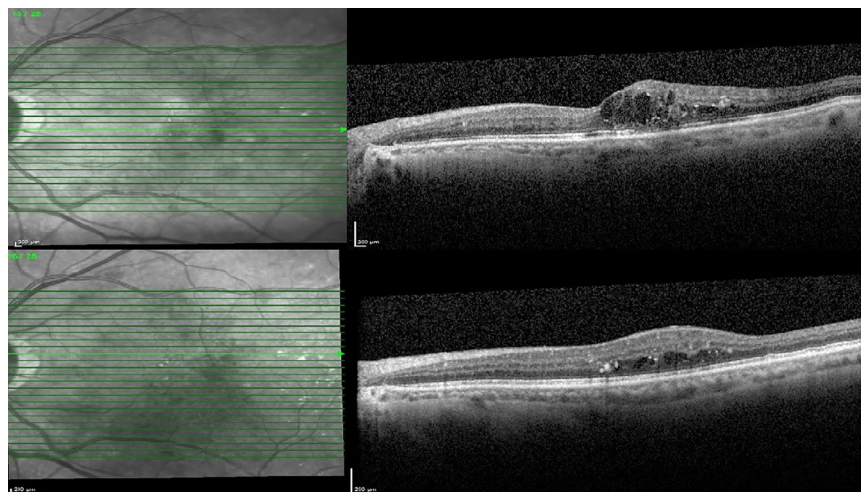


Figure 4. Optical coherence tomography images of a patient without serous retinal detachment before and after intravitreal dexamethasone implantation.

DME with SRD at the 1 month follow-up period. They reported that IDI was found to be more effective in reduction of CRT and SRD height.¹³ However, their study was done only at the 1-month follow-up period. Our study has a 6-month follow-up time, and IDI was found to be effective in CRT reduction at the end of the 6 months. Previous studies have shown that IDI has maximum effects at two months while its effects decrease slowly from months 4 to 6.¹⁶ Thus, in order to explain the effects of IDI, the 6-month follow-up point is necessary. Our study has the advantage over longer times compared to Demircan and colleagues. In another recent study, Ozdemir and colleagues studied 24 eyes of patients with SRD related to DME. They reported that IDI caused an increase in BCVA and a reduction in SRD and CRT.¹⁷ However, their study lacked a control group. In our study, we had a control group (non-SRD patients) and found that although IDI was effective in visual acuity changes, there were no statistically significant differences between SRD and non-SRD patients.

All of these studies had treatment-naïve DME patients. In the current literature, there is only one study that aims to explain effects of dexamethasone implantation with ranibizumab-resistant DME based on OCT patterns. Kaldırım and colleagues studied 35 eyes of 31 patients with ranibizumab-resistant DME. They reported that the SRD group had better BCVA than DRT and CME groups, but the difference was not statistically significant at 4 months. At the end of the 6 months, DRT groups had better BCVA than

other groups because they administered anti-vascular endothelial growth factor (VEGF) agents at 4 months.¹⁸ As mentioned above, in order to better understand the effects of IDI, a 6-month follow-up point is necessary.¹⁶ In the current study, we observed IDI effects on SRD and non-SRD patients over the 6-month follow-up time.

Kim and colleagues¹⁹ reported that SRD or CME patients had higher concentrations of inflammatory cytokines, such as interleukins (ILs)-6 and -8 and platelet-derived growth factor, in the aqueous humor of DME rather than DRT patients. These differences can explain why steroids were found to be more effective in SRD patients, while anti-VEGF agents were found to be more effective in non-SRD patients.¹²⁻¹⁴

There are some limitations to our study, such as retrospective dosing and small sample size. In order to better explain effects of SRD on dexamethasone treatment in patients with DME, a larger sample size and prospective dosing studies are needed.

In conclusion, the presence of SRD resulted in higher anatomical gain, but it had no effects on visual acuity changes with respect to dexamethasone treatment in patients with ranibizumab-resistant DME.

Conflict of interest statement

The authors declared no potential conflicts of interest with respect to the research, authorship, and/or publication of this article.

Funding

The authors received no financial support for the research, authorship, and/or publication of this article.

ORCID iD

Alper Halil Bayat  <https://orcid.org/0000-0003-1827-968X>

References

- Romero-Aroca P. Managing diabetic macular edema: the leading cause of diabetes blindness. *World J Diabetes* 2011; 2: 98–104.
- Early Treatment Diabetic Retinopathy Study Research Group: photocoagulation for diabetic macular edema: ETDRS report no.4. *Int Ophthalmol Clin* 1987; 27: 265–272.
- Otani T, Kishi S and Maruyama Y. Patterns of diabetic macular edema with optical coherence tomography. *Am J Ophthalmol* 1999; 127: 688–693.
- Kim BY, Smith SD and Kaiser PK. Optical coherence tomographic patterns of diabetic macular edema. *Am J Ophthalmol* 2006; 142: 405–412.
- Seo KH, Yu SY, Kim M, *et al.* Visual and morphologic outcomes of intravitreal ranibizumab for diabetic macular edema based on optical coherence tomography patterns. *Retina* 2016; 36: 588–595.
- Giocanti-Auregan A, Hrarat L, Qu LM, *et al.* Functional and anatomical outcomes in patients with serous retinal detachment in diabetic macular edema treated with ranibizumab. *Invest Ophthalmol Vis Sci* 2017; 58: 797–800.
- Yanoff M, Fine BS, Brucker AJ, *et al.* Pathology of human cystoid macular edema. *Surv Ophthalmol* 1984; 28: 505–511.
- Daruich A, Matet A, Moulin A, *et al.* Mechanisms of macular edema: beyond the surface. *Prog Retin Eye Res* 2018; 63: 20–68.
- Vujosevic S, Torresin T, Berton M, *et al.* Diabetic macular edema with and without subfoveal neuroretinal detachment: two different morphologic and functional entities. *Am J Ophthalmol* 2017; 181: 149–155.
- Kaya M, Kaya D, Idiman E, *et al.* A novel biomarker in diabetic macular edema with serous retinal detachment: serum chitinase-3-like protein 1. *Ophthalmologica* 2019; 241: 90–97.
- Liu Q, Hu Y, Yu H, *et al.* Comparison of intravitreal triamcinolone acetonide versus intravitreal bevacizumab as the primary treatment of clinically significant macular edema. *Retina* 2015; 35: 272–279.
- Shimura M, Yasuda K, Yasuda M, *et al.* Visual outcome after intravitreal bevacizumab depends on the optical coherence tomographic patterns of patients with diffuse diabetic macular edema. *Retina* 2013; 33: 740–747.
- Demircan A, Ozkaya A, Alkin Z, *et al.* Comparison of the effect of ranibizumab and dexamethasone implant on serous retinal detachment in diabetic macular edema. *J Fr Ophthalmol* 2018; 41: 733–738.
- Kim M, Lee P, Kim Y, *et al.* Effect of intravitreal beva-cizumab based on optical coherence tomography patterns of diabetic macular edema. *Ophthalmologica* 2011; 226: 138–144.
- Ozdemir H, Karacorlu M and Karacorlu SA. Regression of serous macular detachment after intravitreal triamcinolone acetonide in patients with diabetic macular edema. *Am J Ophthalmol* 2005; 140: 251–255.
- Chang-Lin JE, Attar M, Acheampong AA, *et al.* Pharmacokinetics and pharmacodynamics of a sustained release dexamethasone intravitreal implant. *Invest Ophthalmol Vis Sci* 2011; 52: 80–86.
- Ozdemir MH, Elbay A, Kirik F, *et al.* Regression of serous macular detachment after intravitreal dexamethasone implant in patients with diabetic macular edema. *J Ocul Pharmacol Ther* 2019; 35: 558–564.
- Kaldırım H, Yazgan S, Atalay K, *et al.* Intravitreal dexamethasone implantation in patients with different morphological diabetic macular edema having insufficient response to ranibizumab. *Retina* 2018; 38: 986–992.
- Kim M, Kim Y and Lee SJ. Comparison of aqueous concentrations of angiogenic and inflammatory cytokines based on optical coherence tomography patterns of diabetic macular edema. *Indian J Ophthalmol* 2015; 63: 312–317.

Visit SAGE journals online
[journals.sagepub.com/
home/oed](https://journals.sagepub.com/home/oed)

 SAGE journals