

# Repair of Radial Artery with Autogenous Cephalic Vein Graft Interposition After Closure of Arteriovenous Fistula in a Young Renal Transplantation Patient: Case Report

## Genç Renal Transplantlı Hastada Arteriyovenöz Fistül Kapatılması Sonrası Otolog Sefalik Ven Grefti ile Radyal Arter Onarımı

Arda ÖZYÜKSEL,<sup>a</sup>  
Sinan Sabit KOCABEYOĞLU,<sup>b</sup>  
Erdem ÇETİN,<sup>c</sup>  
Ertekin Utku ÜNAL<sup>b</sup>

<sup>a</sup>Clinic of Cardiovascular Surgery,  
Medipol University Hospital,  
İstanbul

<sup>b</sup>Clinic of Cardiovascular Surgery,  
Türkiye Yüksek İhtisas Training and  
Research Hospital,  
Ankara

<sup>c</sup>Clinic of Cardiovascular Surgery,  
Diyarbakır Memorial Hospital,  
Diyarbakır

Geliş Tarihi/Received: 31.12.2012  
Kabul Tarihi/Accepted: 17.03.2013

Yazışma Adresi/Correspondence:  
Sinan Sabit KOCABEYOĞLU  
Türkiye Yüksek İhtisas Training and  
Research Hospital,  
Clinic of Cardiovascular Surgery,  
Ankara,  
TÜRKİYE/TURKEY  
s4126k@yahoo.com.tr

**ABSTRACT** Autogenous arteriovenous fistula at the wrist is considered as the best choice of vascular access in hemodialysis patients. In this case report, we present a young renal transplant patient who underwent autologous fistula vein interposition and closure of arteriovenous fistula to provide continuity of the radial artery.

**Key Words:** Renal dialysis; arteriovenous fistula; kidney transplantation

**ÖZET** Hemodiyaliz hastalarında el bileğinde açılan otolog arteriyovenöz fistül, vasküler erişim için en iyi seçenek olarak düşünülmektedir. Bu vaka sunumunda, radyal arterin devamlılığı sağlamak için otolog fistül ven interpozisyonu yapılan ve arteriyovenöz fistülü kapatılan genç renal transplantlı hasta takdim edilmiştir.

**Anahtar Kelimeler:** Böbrek diyalizi; arteriyovenöz fistül; böbrek transplantasyonu

**Damar Cer Derg 2013;22(2):252-3**

The autogenous arteriovenous fistula (AVF) at the wrist is considered as the best choice of vascular access (VA) in hemodialysis (HD) patients due to its low complication and high patency rates.<sup>1</sup> Comorbid diseases affecting the vascular system such as diabetes mellitus and hypertension are frequently seen in elderly, which may reduce the success of creation and maintenance of AVF. In end stage renal disease patients, VA becomes useless after a successful renal transplantation (RT). Following RT, there is no consensus about the fate of the AVF. Although the AVF may close spontaneously, the dilemma is whether to preserve the vascular access in case of restarting HD or perform a surgical closure concerning the possible complications.<sup>2</sup> In this case report, we present a young patient whose radial AVF fistula was repaired due to low ulnar arterial flow at the upper extremity selected for HD access. We believe that, in such young patients, dual arterial blood flow to the extremity should be maintained if possible.

### CASE REPORT

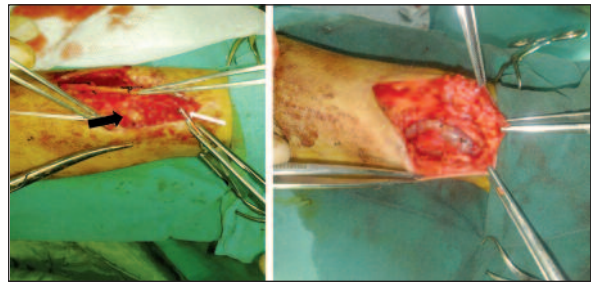
A 28-year-old patient had been operated for left radiocephalic side to side AVF formation three years before RT. Six months after RT, she was admit-

ted to our clinic with swelling and cyanosis of the left hand. The AVF had not been used after RT. There was palpable thrill and aneurysm formation at the site of anastomosis. Left ulnar artery was weakly palpable, but radial artery distal to the AVF was not. The patient was complaining about ischemic pain at moderate effort with that hand. Preoperative Doppler ultrasonography revealed stenotic distal radial artery and biphasic low ulnar arterial flow. The aneurysm was 20x25 mm in diameter. The patient was operated under local anesthesia, the aneurysm was resected and the AVF was closed. Radial artery segment incorporated in the anastomosis zone was stenotic without distal run off. A stenotic segment of 3 cm size was resected and back flow at the wrist level was detected. Cephalic vein segment that was previously used in AVF formation was interposed between the proximal and distal radial artery (Figure 1). Distal radial artery was palpable after the anastomosis was completed. Postoperative course was uneventful. Distal radial artery was palpable one month after the operation at follow up.

## DISCUSSION

In this case of AVF closure after RT, stenotic radial artery segment which was incorporated in the anastomosis was resected and arterial continuity was provided with autologous fistula vein interposition. Dual arterial blood supply to the hand was maintained in this young patient.

Cardiac failure, high flow at the AVF, vascular access complications and esthetic concerns can be considered as the major indications for AVF closure after RT with a well functioning kidney.<sup>2</sup> Late occurrence of aneurysms proximal to radial artery years after closure of AVF has also been described.<sup>3</sup> In our patient, the radiocephalic side to side AVF led to swelling and cyanosis of the distal extremity. The patient was also complaining about ischemic pain at



**FIGURE 1:** Aneurysm formation (black arrow) and distal radial artery segment (white arrow) is seen on the left side. Cephalic vein was interposed between the proximal and distal ends of the radial artery (right side).

moderate effort with that hand, which was related to insufficient ulnar and collateral arterial blood flow to hand. Our patient had a history of superficial thrombophlebitis of the lower extremity, and since the operation was performed under local anesthesia, autologous saphenous vein graft interposition was impossible. Therefore we used the arterialized segment of the outflow vein of AVF. The disadvantage of this technique could be the diameter mismatch between the cephalic vein and radial artery, but we did not come across a major problem during the operation. The aneurysm formation did not alter the anatomical course of nerves significantly in the operative field. Any neurological problem was not encountered in the postoperative course.

Although primary closure of the AVF and ligation of the proximal and distal ends of the artery is a possible choice, we preferred providing the dual arterial continuity of the hand, which is important especially in young patients with ischemic signs and symptoms. Careful clinical evaluation of the patients may help to select patients for surgical closure of AVF after RT.

## Conflict of Interest

*Authors declared no conflict of interest or financial support.*

## REFERENCES

1. Brescia MJ, Cimino JE, Appel K, Hurwich BJ. Chronic haemodialysis using venipuncture and a surgically created arteriovenous fistula. *N Engl J Med* 1966;275(20):1089-92.
2. Manca O, Pisano GL, Carta P, Manca EM, Piredda GB, Pili G, et al. The management of hemodialysis arteriovenous fistulas in well functioning renal transplanted patients: many doubts, few certainties. *J Vasc Access* 2005;6(4):182-6.
3. Basile C, Antonelli M, Libutti P, Teutonico A, Casucci F, Lomonte C. Is there a link between the late occurrence of a brachial artery aneurysm and the ligation of an arteriovenous fistula? *Semin Dial* 2011;24(3):341-2.