



# Results of a universal ultrasonographic hip screening program at a single institution

Olcay GÜLER<sup>1</sup>, Ali ŞEKER<sup>1</sup>, Serhat MUTLU<sup>2</sup>, Mehmet Halis ÇERÇİ<sup>3</sup>, Baran KÖMÜR<sup>2</sup>, Mahir MAHIROĞULLARI<sup>1</sup>

<sup>1</sup>Medipol University Faculty of Medicine, Department of Orthopedics and Traumatology, İstanbul, Turkey

<sup>2</sup>Kanuni Sultan Süleyman Training and Research Hospital, Department of Orthopedics and Traumatology, İstanbul, Turkey

<sup>3</sup>Nisa Hospital, Department of Orthopedics and Traumatology, İstanbul, Turkey

**Objective:** The aims of the present study were to determine the prevalence of developmental dysplasia of the hip (DDH) in newborns screened by hip ultrasonography (US), to review outcome of follow-up and treatment of infants with DDH, and to evaluate the relationship between US-based diagnosis and risk factors.

**Methods:** A total of 9564 hips of 4782 newborns (2398 females, 50.1%) were evaluated with US. Risk factors for DDH and accompanying deformities were also recorded. Graf classification type IIa(-), IIb, IIc, D, and III hips were treated with Pavlik harnesses.

**Results:** Abnormal US findings (type IIa, IIc, or D hips) were detected in 475 newborns (9.9%). Risk factors and concomitant orthopedic deformities were similar in newborns with and without US abnormality and type I hips ( $p > 0.05$  for all). However, abnormal US findings were significantly more common in firstborn and female newborns. A total of 39 hips (5 bilateral, 20 left, 9 right) of 34 newborns (31 females) were placed in Pavlik harnesses. Twelve newborns had type IIc or D hips at initial evaluation, and 22 had type IIb or IIa(-) at follow-up. Mean recovery time was 12.5 (8–16) weeks for newborns with type IIc and D hips, 8.6 (8–12) weeks for those with type IIa(-) hips, and 11.2 (8–12) weeks for those with type IIb hips.

**Conclusion:** DDH is still common among newborns in Turkey. Hip US is recommended for detection and follow-up of DDH in newborns.

**Keywords:** Developmental dysplasia of the hip; ultrasonography; Pavlik harness; risk factors.

**Level of Evidence:** Level III, Retrospective case control study.

Developmental dysplasia of the hip (DDH) is a developmental disturbance generally defined as improperly formed hips, with a reported incidence of 2–76 per 1000 live births among various racial groups by geographical region.<sup>[1–4]</sup> Clinical presentation ranges from slight acetabular dysplasia to severe hip dislocation with proximal femoral displacement.<sup>[5,6]</sup>

If not treated in time, DDH is associated with long-term morbidities, including gait abnormalities, chronic pain, and degenerative arthritis.<sup>[7]</sup> Therefore, early detection of DDH is important in the prevention of hip deformities. However, incorrect diagnosis may lead to unnecessary treatment, which may be complicated by avascular necrosis.<sup>[6,8]</sup>

**Correspondence:** Olcay Güler, MD. Medipol Üniversitesi Tıp Fakültesi, Ortopedi ve Travmatoloji Anabilim Dalı, İstanbul, Turkey.

Tel: +90 – 212 – 521 23 77 e-mail: olcayguler77@gmail.com

**Submitted:** December 24, 2014 **Accepted:** May 28, 2015

©2016 Turkish Association of Orthopaedics and Traumatology

Available online at  
www.aott.org.tr

doi: 10.3944/AOTT.2016.15.0024

QR (Quick Response) Code



**Table 1.** Graf classification of DDH.<sup>[10,11]</sup>

| Classification | Description   | Osseous roof ( $\alpha$ angle) | Cartilaginous roof ( $\beta$ angle)               |
|----------------|---|--------------------------------|---|
| Type I         | Normal, fully mature hips   | $\geq 60$                      | 1a: $< 55$ (narrow)<br>1b: $\geq 55$ (wide based) |
| Type IIa       | IIa(+): Physiological immature—appropriate for age (infants $< 3$ months)<br>IIa(-): Physiological immature—maturational deficit (infants $< 3$ months) | 50–59                          | 55–77   |
| Type IIb       | Physiological delay in ossification (infants $> 3$ months)  | 50–59                          | 55–77   |
| Type IIc       | Abnormal, slightly dislocated hip (critical range)  | 43–49                          | $\leq 77$   |
| Type D         | On point of dislocation (decentric)   | 43–49                          | $> 77$  |
| Type III       | IIIa: Dislocated without structural alteration<br>IIIb: Dislocated with structural alteration   | $< 43$                         | $> 77$  |
| Type IV        | Dislocated inferomedially   | $< 43$                         | $> 77$  |

DDH: Developmental dysplasia of the hip.

Although a number of studies have focused on the importance of early screening for DDH, no consensus has been reached regarding a standard time or method. Options include clinical examination and ultrasonography (US) for all infants, and targeted US for infants at high risk for DDH.<sup>[6,7]</sup> DDH screening programs in the UK and the Netherlands recommend US screening of infants with one or more risk factors, including breech delivery, family history, and limited abduction.<sup>[8,9]</sup> However, the late dislocation rate of 0.22–0.68 per 1000 live births in selective US screening programs should be considered.<sup>[6]</sup>

The number of studies comparing clinical examination with US evaluation has been limited; further investigation is needed in order to clarify the role of US in screening for DDH and determine whether all newborns should be screened by hip US.

The present cross-sectional study was performed at a single institution to determine the prevalence of DDH in newborns screened by hip US, to report the outcome of follow-up and treatment of infants with DDH, and to investigate possible correlations between US-based DDH diagnosis, concomitant orthopedic deformities, and risk factors.

## Patients and methods

The present study was approved by the institutional ethics committee and conducted in accordance with the latest revision of the Declaration of Helsinki. This was a cross-sectional prevalence study in which hospital files of 5439 newborns under routine clinical follow-up were reviewed between January 2010 and December 2012. A total of 9564 hips of 4782 newborns (2398 females, 50.1%; 2384 males, 49.9%) who had undergone hip US at 1 month of age were included. Thirty-four newborns were treated for DDH with a mean follow-up duration of 24.3 months (range, 18–42 months). Newborns who

did not undergo screening at 1 month or hip US examination at the hospital in which the study was conducted, and those with neuromuscular diseases, neural tube defects, or genetic syndromes were excluded. Newborns on whom the Pavlik harness could not be used were also excluded.

Newborns included were initially evaluated by pediatricians at 1 month of age, a routine time for clinical follow-up at the hospital in which the study was conducted. Pediatricians performed physical examinations and determined presence of risk factors for DDH (e.g., breech presentation, family history, vaginal birth, female sex, first birth order, swaddling, and accompanying deformities such as torticollis or foot deformity).

Newborns were screened for DDH with hip US, which was performed according to the Graf method, using a 7.5-MHz linear array probe on both hips in the lateral decubitus position on a specially designed table.<sup>[10]</sup> A minimum of 2 sonograms in the standard plane were obtained for each hip, and each sonogram was evaluated according to Graf classification (Table 1).<sup>[10,11]</sup>

Graf classification type I hips (mature) were excluded from follow-up. Hips of other types were evaluated at orthopedic clinics. Type IIc, D, and III hips were immediately treated with Pavlik harnesses. A follow-up US examination at 4 weeks was performed for type IIa hips. Type IIa hips that progressed to type IIa(-) during follow-up were also treated with Pavlik harnesses. Type IIa(+) hips were followed at 4-week intervals, and Pavlik harnesses were used to treat hips progressing to type IIb. Correlations between risk factors, concomitant orthopedic pathologies, and Graf hip types were investigated. Some type IIa, immature, hips improved to type I during follow-up. An aim of the present study was to investigate the improvement to type I by the third month of follow-up.

**Table 2.** Risk factors and concomitant orthopedic deformities with respect to US Graf classification of newborn hips at initial evaluation.

| Time of evaluation                 | Baseline          |            |          |                |            | p <sup>c</sup>   |
|------------------------------------|-------------------|------------|----------|----------------|------------|------------------|
|                                    | I                 | Ila        | Ilc      | D              | Ila+Ilc+D  |                  |
| Type of Graf classification        |                   |            |          |                |            |                  |
| Number of newborns                 | 4307 <sup>a</sup> | 463        | 11       | 1 <sup>b</sup> | 475        |                  |
| Risk factors                       |                   |            |          |                |            |                  |
| Firstborn child                    | 142 (7.8)         | 91 (19.6)  | 4 (36.4) | 1 (100)        | 96 (20.2)  | <0.01            |
| Breech presentation                | 193 (10.6)        | 57 (12.3)  | 3 (27.3) | 1 (100)        | 61 (12.8)  | 0.158            |
| Family history                     | 339 (18.6)        | 87 (18.8)  | 4 (36.4) | 1 (100)        | 107 (22.5) | 0.686            |
| Vaginal birth                      | 1099 (60.2)       | 291 (62.9) | 9 (81.8) | 1 (100)        | 301 (63.4) | 0.201            |
| Female gender                      | 1008 (55.2)       | 342 (73.9) | 2 (18.2) | 1 (100)        | 352 (74.1) | <b>&lt;0.001</b> |
| Swaddling                          | 101 (5.5)         | 22 (4.8)   | 0 (0.0)  | 0 (0.0)        | 22 (4.6)   | 0.439            |
| Concomitant orthopedic deformities |                   |            |          |                |            |                  |
| Torticollis                        | 34 (1.9)          | 4 (0.9)    | 0 (0.0)  | 0 (0.0)        | 4 (0.8)    | 0.121            |
| Foot deformities                   | 26 (1.4)          | 5 (1.1)    | 1 (9.1)  | 0 (0.0)        | 6 (1.3)    | 0.791            |

Data are presented as number of newborns (percentage to total newborns with corresponding Graf classification). <sup>a</sup>Risk factors and orthopedic deformities were recorded for 1827 of the 4307 newborns with Graf type I hips at baseline; <sup>b</sup>Fisher's exact test for type D; <sup>c</sup>Pearson's chi-square test for type I vs type Ila+Ilc+D.

The Pavlik harness is a dynamic abduction orthosis that places the hip in a position of flexion and modest abduction.<sup>[12]</sup> As the well-established orthosis of choice for infants with DDH,<sup>[6,8]</sup> Pavlik harnesses were applied by orthopedists for the treatment of type Ila(-) and more severe types of DDH after obtaining informed consent from families.

Patients in Pavlik harnesses were evaluated with US at 4-week intervals until mature (type I) hips had developed; US was used to determine the end of Pavlik harness treatment. In addition to US, bilateral anteroposterior and frog-leg radiographs were taken at 6 months of Pavlik harness treatment.

Initial screening and follow-up were performed by the same radiologist and orthopedist.

Based on the 0.59% reported prevalence of DDH in Turkey,<sup>[13]</sup> sample size was calculated as 4780 subjects, assuming an error rate of 0.0035, type I error of 0.05, and power of 80%. Post hoc analysis revealed a power of 99.99% with a DDH prevalence rate of 9.9% in 4782 newborns, compared to the study by Songür et al.<sup>[13]</sup> Statistical analysis was performed using SPSS software for Windows (version 15.0; SPSS Inc., Chicago, IL, USA). Relationships between Graf classification and sex, breech presentation, family history, type of labor, history of swaddling, and presence of torticollis or foot deformity were evaluated using Pearson's chi-square test. Fisher's exact test was used for comparisons in which expected cell count was less than 5. A p value less than 0.05 was considered statistically significant.

## Results

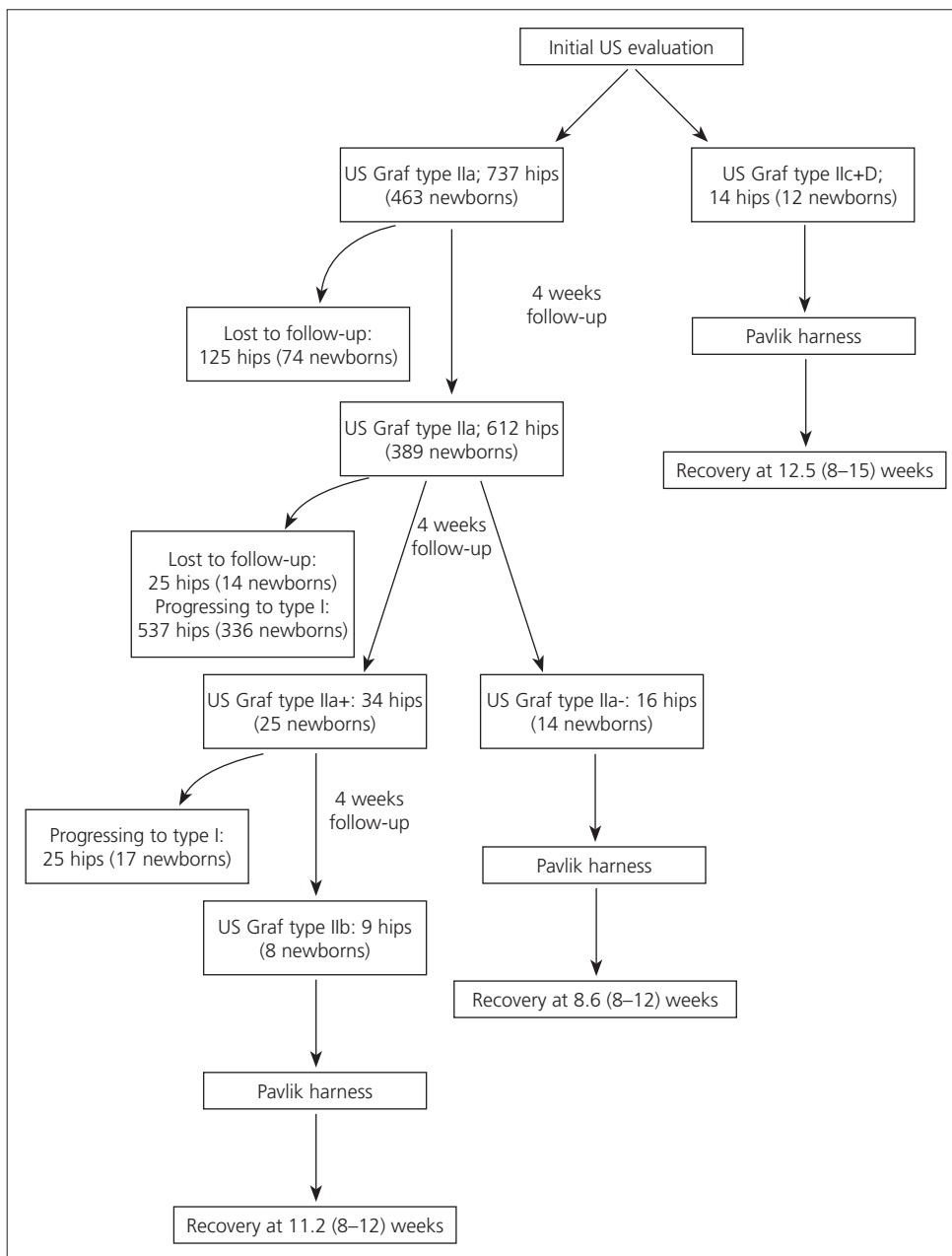
Type Iic or D DDH was detected in 12 (0.25%) of the 4782 newborns evaluated by US. Type Ila, immature,

hips were observed in 463 newborns (9.6%). A total of 8813 out of 9564 hips were type I (92.1%, 4307 newborns), 737 were type Ila (7.7%, 463 newborns), 12 were type Iic (0.1%, 11 newborns), and 2 were type D (0.02%, 1 newborn).

Data regarding risk factors and concomitant orthopedic deformities at initial evaluation could only be obtained from the hospital files of 475 newborns with type Ila (n=463), Iic (n=11), or D (n=1) hips and from the files of 1827 newborns with type I hips (1008 females, 819 males) (Table 2). Risk factors and concomitant orthopedic deformities in newborns with type Ila, Iic, or D hips were similar to those observed in newborns with type I hips (vaginal birth, 63.4% vs 60.2%; family history, 22.5% vs 18.6%; breech presentation, 12.8% vs 10.6%; swaddling, 4.6% vs 5.5%; torticollis, 0.8% vs 1.9%; foot deformities, 1.3% vs 1.4%, respectively; p>0.05 for all). However, female gender and first birth order were more common among newborns with types Ila, Iic, or D hips and than among those with type I hips (female gender, 74.1% vs 55.2%, respectively; p<0.001; first birth order, 20.2% vs 7.8%, respectively; p<0.01).

Patients in Pavlik harnesses were examined with US at 4-week intervals, until mature (type I) hips were developed; US was used to determine end of Pavlik harness treatment. Bilateral anteroposterior and frog-leg radiographs were taken at 6 months of harness treatment.

Mean time to follow-up US evaluation was 36 (25–44) days for newborns with type Ila (immature) hips. Pavlik harnesses were used to treat a total of 39 hips (5 bilateral, 20 left, 9 right) of 34 newborns (31 females). Fourteen of the 39 hips were type Iic or D at initial evaluation and 16 were type Ila(-). Nine were type Iib at



**Fig. 1.** Follow-up and treatment of newborns diagnosed with DDH via hip US.

follow-up. Mean recovery time was 12.5 (8–16) weeks for type IIc and type D DDH, 8.6 (8–12) weeks for type IIa(-) DDH, and 11.2 (8–12) weeks for type IIb DDH (Figure 1). No patients experienced complications due to Pavlik harness. Three-month evaluation revealed that risk factors and concomitant orthopedic deformities were significantly more prevalent in newborns treated with Pavlik harness (Table 3). It was also observed that breech presentation, family history, and concomitant orthopedic deformities were more prevalent in newborns with DDH that developed from type IIa (n=22) to type

IIb/IIa(-) than in those with DDH that developed from type IIa to type I (n=441) (Table 3).

## Discussion

In the present cross-sectional study, 4782 newborns were screened for DDH using hip US at a single center in Istanbul. The center serves a population that has, for the most part, moved to the city from rural areas and has largely abandoned the practice of swaddling, which is still common in certain rural regions of Turkey. Although 10% of newborns were diagnosed with DDH

**Table 3.** Risk factors and concomitant orthopedic deformities with respect to US Graf classification of newborn hips at third month.

| Time of evaluation                 | Third month           |            |                |                  |                  | P <sup>b</sup>   | P <sup>c</sup> |
|------------------------------------|-----------------------|------------|----------------|------------------|------------------|------------------|----------------|
|                                    | I+IIa⇒I               | IIa⇒I      | IIa⇒IIb/IIa(-) | IIa(-)+IIb+IIc+D |                  |                  |                |
| Type of Graf classification        |                       |            |                |                  |                  |                  |                |
| Number of newborns                 | 1827+441 <sup>a</sup> | 441        | 22             | 34               |                  |                  |                |
| Risk factors                       |                       |            |                |                  |                  |                  |                |
| Firstborn child                    | 222 (9.7)             | 80 (18.1)  | 11 (50.0)      | 16 (47.0)        | <b>&lt;0.001</b> | <b>&lt;0.001</b> |                |
| Breech presentation                | 241 (10.6)            | 48 (10.8)  | 9 (40.9)       | 13 (38.2)        | <b>&lt;0.001</b> | <b>&lt;0.001</b> |                |
| Family history                     | 416 (18.3)            | 77 (17.4)  | 10 (45.4)      | 15 (44.1)        | <b>&lt;0.001</b> | <b>&lt;0.001</b> |                |
| Vaginal birth                      | 1376 (60.6)           | 277 (62.8) | 14 (63.6)      | 24 (70.5)        | 0.741            | <b>&lt;0.05</b>  |                |
| Female gender                      | 1331 (58.6)           | 323 (72.5) | 19 (68.1)      | 22 (64.7)        | 0.142            | <b>&lt;0.05</b>  |                |
| Swaddling                          | 119 (5.24)            | 18 (4.08)  | 4 (18.1)       | 4 (11.7)         | <b>&lt;0.05</b>  | <b>&lt;0.05</b>  |                |
| Concomitant orthopedic deformities |                       |            |                |                  |                  |                  |                |
| Torticollis                        | 37 (1.63)             | 3 (0.6)    | 1 (4.54)       | 1 (2.94)         | <b>&lt;0.05</b>  | <b>&lt;0.05</b>  |                |
| Foot deformities                   | 30 (1.32)             | 4 (0.9)    | 1 (4.54)       | 2 (5.88)         | <b>&lt;0.05</b>  | <b>&lt;0.05</b>  |                |

Data are presented as number of newborns (percentage to total newborns with corresponding Graf classification). <sup>a</sup>Risk factors and orthopedic deformities were recorded for 2268 newborns at third month (1827 of the 4307 newborns with type I hips and 441 newborns with hips that developed from type IIa to type I);

<sup>b</sup>Pearson's chi-square test for type IIa⇒type I vs. type IIa⇒type IIb/IIa(-) at third month; <sup>c</sup>Pearson's chi-square test for type I vs type IIa(-)+IIb+IIc+D at third month.

in the present study, no risk factors other than female sex and first birth order were significantly more prevalent in infants with DDH. In addition to its significant role in diagnosing newborns with neither symptoms nor risk factors, hip US was effectively used during follow-up of DDH.

Studies from Turkey have revealed a wide range of DDH prevalence, 0.5–28.1%, depending on screening method, presence of risk factors, and region.<sup>[13–15]</sup> Knowledge of DDH among primary care physicians in Turkey has been significantly improved by a hip screening program in the recent years.<sup>[16]</sup> The aim of the present study was to contribute to standards of screening for DDH.

Graf US was used to assess the relationship between the femoral head and acetabulum, and the classification of DDH. The Graf method, a quantitative classification system, is the most widely used, standardized technique for DDH screening via US examination.<sup>[17]</sup>

Although US is currently the gold standard DDH diagnostic tool, no consensus exists regarding the use of US for DDH screening.<sup>[18]</sup> Arti et al. recently used US to screen 5800 newborns with risk factors or suspicion upon clinical examination in Iran.<sup>[3]</sup> It was determined that 72% of hips included after US screening had been diagnosed as normal upon clinical examination, concluding that hip US is the gold standard method of evaluating DDH. In addition, Koşar et al. reported in a study that included 1321 male infants that up to 28% of DDH cases would have been missed by selective US screening protocol, concluding that all newborns should be assessed using hip US.<sup>[19]</sup> Dogruel et al. demonstrated

a low specificity for clinical findings and a need for US in diagnosing DDH, and Atalar et al. showed that low-grade dysplasia detected on US may go undetected on radiography.<sup>[20,21]</sup> Furthermore, US has been reported to have high interobserver reliability.<sup>[22]</sup> The findings of the present study also demonstrate the effectiveness of hip US in the diagnosis of DDH. Prevalence of newborns with abnormal hip US was approximately 10% (475/4782 newborns) at initial evaluation. Among these newborns, 12 were diagnosed with DDH (type IIc or D), and 463 had an immature hip, 22 of which developed to types IIb or IIa(-) on follow-up.

Only gender and first birth order were found to correlate with increased risk of hip immaturity or DDH in the present study, a finding that sheds light on the importance of universal screening (Table 2). However, in 2 large trials that included 11925 and 15529 newborns who were randomly assigned to groups in which either all were screened (universal screening), only high-risk newborns were screened (selective screening), or none were screened, no statistically significant difference was determined regarding prevalence of late DDH among groups.<sup>[23,24]</sup> In addition, a recent Cochrane review concluded that based on the available evidence, no clear recommendations for hip screening of newborn infants can be given.<sup>[8]</sup> Currently, a combination of universal clinical screening and selective US screening is in practice.<sup>[14,25]</sup> During follow-ups, all risk factors and concomitant deformities increased the risk of DDH (Table 3). However, Omeroglu et al. have reported that female newborns with type IIa are at greater risk for DDH without spontaneous improvement.<sup>[26]</sup> In the literature, risk factors including breech presentation, fam-

ily history, and torticollis are shown to increase risk of DDH.<sup>[27–29]</sup>

As Pavlik harness has been proved superior to abduction orthosis for primary management of DDH,<sup>[30]</sup> harnesses were used as treatment in the present study. A recent review reported harness-related complications, including avascular necrosis and femoral nerve palsy.<sup>[31]</sup> Outcome of treatment in the present study was successful in all cases without complication. In addition to its use as a screening tool, US has been used to monitor reduction during treatment.<sup>[25]</sup> US was also used to monitor progress of DDH and response to harness treatment effectively in the present study.

Among subjects with abnormal US findings at initial evaluation (n=475), most had immature (type IIa) DDH (n=463), the majority of whom were female (73.9%). Female gender is a known risk factor for DDH.<sup>[20,32]</sup> In the present study, 22 newborns (21 girls) diagnosed as type IIb or IIa(-) were successfully treated with Pavlik harnesses.

In contrast to previous reports from Turkey demonstrating that swaddling is a risk factor for DDH,<sup>[20,26,30,32,33]</sup> swaddling rates among newborns with and without DDH were similar in the present study. Recent literature supports the lack of association between foot deformities such as clubfoot and DDH.<sup>[34]</sup> Although the present findings run counter to widely held beliefs among many surgeons, they are similar to those of previous studies, which indicate a lack of association between risk factors and DDH diagnosis.<sup>[19]</sup> Abnormal findings concurrent with risk factors and concomitant orthopedic deformities occurred at similar rates in newborns with and without DDH.

The main limitations of the present study were retrospective design and small sample size. Retrospective design led to the exclusion of newborns that had not been screened at the study center, inconsistent physical examination findings due to intraobserver variability, and examination of only a subset of patients for clinical risk factors, which may have introduced bias. Furthermore, several conclusions may have been influenced by the study of a population served by a single institution. In addition, US evaluations were performed by the same radiologists throughout the study, which may also have introduced bias. Finally, prevalence of DDH in the present small sample may not reflect its prevalence in the larger Turkish population, precluding authors from forming conclusions regarding DDH risk factors. Nevertheless, the present findings contribute to DDH literature, in which there is still no consensus on the use of US for screening and follow-up. Further large-scale and

prospective studies are needed to reach a definitive conclusion regarding the necessity of universal US screening, taking time and cost-effectiveness into account.

In conclusion, the findings of the present study support US screening of firstborn and female newborns. Due to lack of statistical difference regarding risk factors and concomitant deformities among newborns with and without DDH, universal screening is recommended.

**Conflicts of Interest:** No conflicts declared.

## References

1. Kokavec M, Bialik V. Developmental dysplasia of the hip. Prevention and real incidence. *Bratisl Lek Listy* 2007;108:251–4.
2. Loder RT, Skopelja EN. The epidemiology and demographics of hip dysplasia. *ISRN Orthop* 2011;2011:238607.
3. Arti H, Mehdinasab SA1, Arti S2. Comparing results of clinical versus ultrasonographic examination in developmental dysplasia of hip. *J Res Med Sci* 2013;18:1051–5.
4. Phelan N, Thoren J, Fox C, O'Daly BJ, O'Beirne J. Developmental dysplasia of the hip: incidence and treatment outcomes in the Southeast of Ireland. *Ir J Med Sci* 2015;184:411–5. [CrossRef](#)
5. Weinstein SL, Mubarak SJ, Wenger DR. Developmental hip dysplasia and dislocation: Part II. *Instr Course Lect* 2004;53:531–42.
6. Gulati V, Eseonu K, Sayani J, Ismail N, Uzoigwe C, Choudhury MZ, et al. Developmental dysplasia of the hip in the newborn: A systematic review. *World J Orthop* 2013;4:32–41. [CrossRef](#)
7. Shorter D, Hong T, Osborn DA. Cochrane Review: Screening programmes for developmental dysplasia of the hip in newborn infants. *Evid Based Child Health* 2013;8:11–54. [CrossRef](#)
8. van der Sluijs JA, De Gier L, Verbeke JI, Witbreuk MM, Pruys JE, van Royen BJ. Prolonged treatment with the Pavlik harness in infants with developmental dysplasia of the hip. *J Bone Joint Surg Br* 2009;91:1090–3. [CrossRef](#)
9. Gray A, Elbourne D, Dezateux C, King A, Quinn A, Gardner F. Economic evaluation of ultrasonography in the diagnosis and management of developmental hip dysplasia in the United Kingdom and Ireland. *J Bone Joint Surg Am* 2005;87:2472–9. [CrossRef](#)
10. Graf R. Hip sonography. Diagnosis and management of infant hip dysplasia, 2<sup>nd</sup> edn. Springer, Berlin 2006.
11. Graf R. Classification of hip joint dysplasia by means of sonography. *Arch Orthop Trauma Surg* 1984;102:248–55. [CrossRef](#)
12. Pavlik A. Method of functional therapy with strap braces as a principle of conservative therapy of congenital dislocation of the hip in infants. [Article in German] *Z Orthop*

- Ihre Grenzgeb 1957;89:341–52. [Abstract]
13. Songür M, Akel I, Karahan S, Kuzgun U, Tümer Y. Prevalence of untreated hip dislocation in Turkish children aged 6 months to 14 years. *Acta Orthop Traumatol Turc* 2011;45:215–20. [CrossRef](#)
  14. Omeroglu H, Koparal S, Bicimoglu A, Karademir A. The relationship between risk factors, clinical findings and ultrasonographic findings in developmental hip dysplasia. *Acta Orthop Traumatol Turc* 1999;33:30–4.
  15. Tümer Y, Omeroglu H. Prevention of developmental hip dysplasia in Turkey. *Acta Orthop Traumatol Turc* 1997;31:176–81.
  16. Doğruel H, Atalar H, Yavuz Oy, Uraş İ, Günay C, Şayli U. An Evaluation of Developmental Hip Dysplasia Frequency and Screening Programs in Turkey: Review. *Türkiye Klinikleri J Med Sci* 2008;28:357–60.
  17. Omeroglu H. Use of ultrasonography in developmental dysplasia of the hip. *J Child Orthop* 2014;8:105–13. [CrossRef](#)
  18. Scott-Jupp R. Ultrasound hip screening: why bother? *Arch Dis Child* 2013;98:985. [CrossRef](#)
  19. Koşar P, Ergun E, Yiğit H, Gökharman FD, Kosar U. Developmental dysplasia in male infants: risk factors, instability and ultrasound screening. *Hip Int* 2011;21:409–14. [CrossRef](#)
  20. Doğruel H, Atalar H, Yavuz OY, Sayli U. Clinical examination versus ultrasonography in detecting developmental dysplasia of the hip. *Int Orthop* 2008;32:415–9. [CrossRef](#)
  21. Atalar H, Doğruel H, Selek H, Tasbas BA, Bicimoglu A, Günay C. A comparison of ultrasonography and radiography in the management of infants with suspected developmental dysplasia of the hip. *Acta Orthop Belg* 2013;79:524–9.
  22. Copuroglu C, Ozcan M, Aykac B, Tuncer B, Saridogan K. Reliability of ultrasonographic measurements in suspected patients of developmental dysplasia of the hip and correlation with the acetabular index. *Indian J Orthop* 2011;45:553–7. [CrossRef](#)
  23. Rosendahl K, Markestad T, Lie RT. Ultrasound screening for developmental dysplasia of the hip in the neonate: the effect on treatment rate and prevalence of late cases. *Pediatrics* 1994;94:47–52.
  24. Holen KJ, Tegnander A, Bredland T, Johansen OJ, Saether OD, Eik-Nes SH, et al. Universal or selective screening of the neonatal hip using ultrasound? A prospective, randomised trial of 15,529 newborn infants. *J Bone Joint Surg Br* 2002;84:886–90. [CrossRef](#)
  25. Fitch RD. Ultrasound for screening and management of developmental dysplasia of the hip. *N C Med J* 2014;75:142–5. [CrossRef](#)
  26. Omeroglu H, Caylak R, Inan U, Köse N. Ultrasonographic Graf type Ila hip needs more consideration in newborn girls. *J Child Orthop* 2013;7:95–8. [CrossRef](#)
  27. Omeroglu H, Koparal S. The role of clinical examination and risk factors in the diagnosis of developmental dysplasia of the hip: a prospective study in 188 referred young infants. *Arch Orthop Trauma Surg*. 2001;121:7–11. [CrossRef](#)
  28. Tien YC, Su JY, Lin GT, Lin SY. Ultrasonographic study of the coexistence of muscular torticollis and dysplasia of the hip. *J Pediatr Orthop* 2001;21:343–7. [CrossRef](#)
  29. Bache CE, Clegg J, Herron M. Risk factors for developmental dysplasia of the hip: ultrasonographic findings in the neonatal period. *J Pediatr Orthop B* 2002;11:212–8.
  30. Sankar WN, Nduaguba A, Flynn JM. Ilfeld abduction orthosis is an effective second-line treatment after failure of Pavlik harness for infants with developmental dysplasia of the hip. *J Bone Joint Surg Am* 2015;97:292–7. [CrossRef](#)
  31. Tibrewal S, Gulati V, Ramchandran M. The Pavlik method: a systematic review of current concepts. *J Pediatr Orthop B* 2013;22:516–20. [CrossRef](#)
  32. Akman A, Korkmaz A, Aksoy MC, Yazici M, Yurdakök M, Tekinalp G. Evaluation of risk factors in developmental dysplasia of the hip: results of infantile hip ultrasonography. *Turk J Pediatr* 2007;49:290–4.
  33. Guner SI, Guner S, Peker E, Ceylan MF, Guler A, Turktas U, et al. Are consanguineous marriage and swaddling the risk factors of developmental dysplasia of the hip? *J Membr Biol* 2013;246:115–9. [CrossRef](#)
  34. Chou DTs, Ramchandran M1. Prevalence of developmental dysplasia of the hip in children with clubfoot. *J Child Orthop* 2013;7:263–7. [CrossRef](#)