

İlknur SARAL¹
Oğuz DURMUŞ¹
Mehmet AĞIRMAN¹
Tuğrul ÖRMECİ²
Engin ÇAKAR¹

Correspondance

İlknur SARAL
İstanbul Medipol University, Department of Physical
Medicine and Rehabilitation, İSTANBUL

Phone: 0212 460 70 70
e-mail: ilknursaral@gmail.com

Received: 30/01/2015

Accepted: 12/02/2015

¹ İstanbul Medipol University, Department of Physical
Medicine and Rehabilitation, İSTANBUL

² İstanbul Medipol University, Department of Radiology,
İSTANBUL



CASE REPORT

AN UNEXPECTED CASE OF ATYPICAL FEMUR FRACTURE MISDIAGNOSED AS RADICULOPATHY AND HIP OSTEOARTHRITIS: A PATIENT TREATED WITH BISPHOSPHONATE

ABSTRACT

Bisphosphonates are the most commonly used drugs in the treatment of osteoporosis. Several randomized controlled studies have proved their effectiveness in the treatment of postmenopausal osteoporosis and today BPs are considered a first-line therapy for osteoporosis. Bisphosphonates inhibit osteoclastic activity, decrease bone turnover and increase bone mineral density. Although there is strong evidence that bisphosphonates prevent osteoporotic fractures, in recent years, there have been several reports that show the increasing risk of atypical femoral fractures that is related to prolonged usage (5 years or longer) of bisphosphonates. This may be related to prolonged suppression of bone turnover. By suppressing the bone turnover they impair the ability of bone to repair the microdamages and leads the accumulation of microcracks. In this case, we report 67-year-old female who presented with atypical femoral fracture.

Key Words: Alendronate; Bisphosphonates; Femoral Fractures.



OLGU SUNUMU

BİSFOSFONAT TEDAVİSİ ALAN BİR HASTADA RADİKÜLOPATİ VE KALÇA OSTEOARTRİTİNİ TAKLİT EDEN ATİPİK FEMUR KIRIĞI: OLGU SUNUMU

Öz

Bisfosfonatlar osteoporoz tedavisinde en yaygın kullanılan ilaçlardır. Postmenopozal osteoporozun tedavisinde etkili oldukları birçok randomize kontrollü çalışma tarafından kanıtlanmıştır ve günümüzde osteoporoz tedavisinde birinci seçenek ilaç olarak kullanılmaktadır. Bisfosfonatlar, osteoklastik aktiviteyi inhibe ederek kemik döngüsünü azaltır ve kemik mineral dansitesini artırır. Bisfosfonatların osteoporotik kırıkları önlediğine dair güçlü kanıtlar olmasına rağmen geçtiğimiz yıllarda uzun süreli kullanım (5 yıl veya daha fazla süre) sonrasında atipik femoral fraktür riskini artırdıkları çeşitli çalışmalarla rapor edilmiştir. Bunun sebebi kemik döngüsünü baskılayarak kemiğin mikro hasarları tamir etme becerisini bozması ve mikro-çatlakların birikmesine yol açması olabilir. Bu yazıda atipik femur kırığına sahip 67 yaşındaki bir kadın hasta sunulmaktadır.

Anahtar Sözcükler: Alendronat; Bisfosfonat; Femur Kırığı.



INTRODUCTION

Bisphosphonates (BPs) are highly effective medications for the prevention and treatment of osteoporosis. However, they are associated with sporadic cases of atypical femoral fractures. Atypical femur fractures were first reported in 2007 and are now recognized as a unique clinical entity (1). They are described as fractures that are located in the subtrochanteric region and femoral shaft, transverse or short oblique orientation, resulting spontaneously or after minimal trauma (2). Atypical femoral fractures are rarely seen among the stress fractures but they gained much interest recently because of their strong relationship with BPs. In this article, we present a 67-year-old female with a 6-year history of continuous alendronate therapy, who was diagnosed with nondisplaced fracture of the left femur.

CASE

A 67-year-old female patient was admitted to our clinic with severe low-back, left thigh and hip pain. The pain had started about 1 year previously. He had applied to several health centers due to pain. He had received physical therapy and analgesic medications with a diagnosis of lumbar disco-

pathy and hip osteoarthritis but there had been no improvement. The patient has osteoporosis for about 10 years and has been receiving alendronate therapy continuously for the past six years because of postmenopausal osteoporosis. She did not use any other drug for osteoporosis. She had undergone right femur fracture occurring spontaneously about three years ago. There was no history of trauma, fall, alcohol intake and smoking.

Clinical examination revealed an antalgic gait due to the left leg pain. There was pain over the shaft of left femur during palpation. The motion of the left hip joint was painful in all directions. Lumbar motions were restricted and she had lumbar paravertebral muscle spasm. There were no neurological deficits of the lower extremities. Lumbar magnetic resonance imaging showed disc herniation at L2-L5 and L5-S1 and radiographs showed hip mild degeneration. The serum calcium, phosphate, parathyroid and thyroid hormones and 25-hydroxy vitamin D levels were in normal range. Femur and lumbar spine were evaluated by dual-energy X-ray absorptiometry. T-scores were in the osteopenic range, and showed T-score of -1.0 at lumbar spine (L1-L4) and -1.5 at femur. Magnetic resonance imaging (MRI) of the left lower extremity revealed findings consistent with the previous fracture line on the right femur (Figure 1a) and the suspected di-

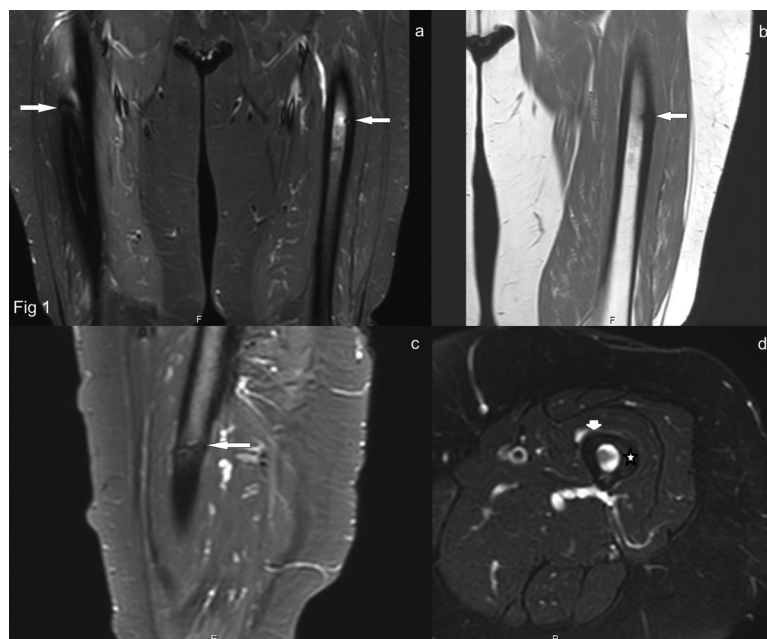


Figure 1— a. Coronal T2 SPAIR image shows transverse, incomplete fracture lines (arrows) in the proximal femur diaphysis bilaterally. The fracture line on the right femur is hardly seen depending on the metallic artifact at the site of the previous surgery, b. coronal T1 TSE and c. sagittal T2 SPAIR demonstrate an appearance of cortical breaking slightly due to incomplete fracture line with focal cortical thickening in the lateral cortex of left side, d. axial T2 SPAIR shows bone bruise (star) with hyperintensity in adjacent soft tissue planes due to edema (arrow head).

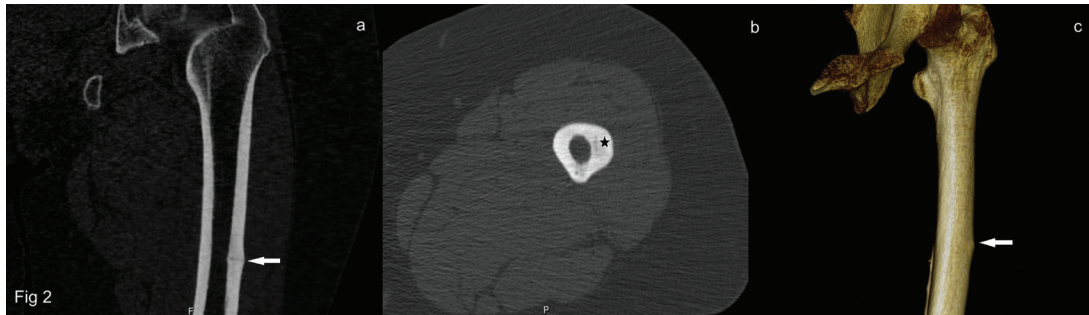


Figure 2— In **a**, non-displaced and incomplete fracture line (arrow) is detected in coronal non-enhanced and reformatted CT image, **b**, axial non-enhanced CT image shows discrete radiolucency (star) on the fracture site, **c**, The cortical thickening (arrow) on the lateral cortex can be easily seen in VRT - CT (Volume Rendering Technique- Computerized Tomography) image.

aphyseal femoral shaft fracture (Figure 1b-c-d). Computerized Tomography scan (CT scan) demonstrated non-displaced transverse fracture in the middle third of the diaphysis (Figure 2a-b-c). The alendronate therapy was discontinued and orthopedic surgical approach was planned.

In conclusion, BPs are considered a first-line therapy for osteoporosis today. They inhibit osteoclast-mediated bone resorption and decrease fracture risk by suppressing excessive bone remodeling. In long term, reduction of remodeling is also related with increased micro damage accumulation and may result to an a dynamic brittle bone (2-4). The guidelines advise prescribing BPs not for longer than 5 years. Long-term BP usage may over suppress bone turnover and severe suppression of bone turnover and micro damage accumulation may lead to increase the risk of atypical fracture (5). In recent years, there have been increasing number of clinical trials, cases and case series that show the increasing risk of atypical femoral fractures that is related to prolonged usage of BPs (4). But there is no rationale for their discontinuation. The occurrence of atypical femoral fracture is very rare as compared to the number of fractures prevented by BPs.

In this report, we aimed to emphasize the atypical femoral fractures associated with long-term usage of BPs. We advise that; In geriatric patients who have received long-term

treatment of BPs, fractures should be remind and clinicians not just satisfied with radiographs, further radiological investigations should be carried out in the presence of persistent thigh and hip pain.

REFERENCES

1. Tyler W, Bukata S, O'Keefe R. Atypical femur fractures. *Clin Geriatr Med* 2014;30:349-59. (PMID:24721373).
2. Shane E, Burr D, Ebeling PR et al. Atypical subtrochanteric and diaphyseal femoral fractures: report of a task force of the American Society for Bone and Mineral Research. *J Bone Miner Res* 2010;25:2267-94. (PMID:20842676).
3. Schilcher J, Sandberg O, Isaksson H, Aspenberg P. Histology of 8 atypical femoral fractures: remodeling but no healing. *Acta Orthop* 2014;85:280-6. (PMID:24786905).
4. Park-Wyllie LY, Mamdani MM, Juurlink DN et al. Bisphosphonate use and the risk of subtrochanteric or femoral shaft fractures in older women. *JAMA* 2011;305:783-9. (PMID:21343577).
5. Shane E, Burr D, Abrahamsen B, Adler RA et al. Atypical subtrochanteric and diaphyseal femoral fractures: second report of a task force of the American Society for Bone and Mineral Research. *J Bone Miner Res* 2014;29:1-23. (PMID:23712442).