

# Transabdominal Preperitoneal Repair For Bilateral Inguinal Hernias: A Single Center Experience

Mustafa Haksal<sup>1</sup>, Nuri Okkabaz<sup>2</sup>, Osman Civil<sup>2</sup>, Metin Kement<sup>2</sup>, Mustafa Oncel<sup>1</sup>

<sup>1</sup>Istanbul Medipol University, School of Medicine, General Surgery, Istanbul, Turkey

<sup>2</sup>Kartal Training and Research Hospital, General Surgery, Istanbul, Turkey

## ABSTRACT

**Aim:** To evaluate outcomes of transabdominal preperitoneal repair in patients with bilateral inguinal hernias.

**Methods:** Sociodemographic data, and data about disease and operation with postoperative data of all patients with bilateral inguinal hernias, who were treated by transabdominal preperitoneal repair were prospectively collected. Patients were followed-up for recurrence and chronic pain in the long-term.

**Results:** A total of 70 (67 [95.7%] males, mean age was 53.4±13.6 years) cases were included. Total 138 hernias (mostly Nyhus type 3 [n=116; 84.1%]) were repaired in 70 cases. Unilateral inguinal hernia was diagnosed in two cases during the operation. Mean operation time was 80.6±26.5 minutes. Inferior epigastric vein was injured in 2 (1.4%) cases. Parenteral analgesics were required in only 10 (14.3%) patients. Patients were discharged 1.21±0.67 days after the operation, and only 9 (12.8%) cases were hospitalized more than one day. Patients returned work or normal activity 10.5±4.7 days after the surgery. The mean follow-up period was 25.9±19.4 months. Symptomatic recurrence was observed in 2 (1.4%) patients. Six (8.7%) cases had chronic pain.

**Conclusion:** Transabdominal preperitoneal repair may be an alternative approach in treatment of bilateral inguinal hernias.

**Keywords:** Inguinal hernia, hernia repair, recurrence, laparoscopy

## ÖZ

Bilateral kasık fıtıklarında transabdominal preperitoneal onarım: tek merkez deneyimi

**Amaç:** Bilateral kasık fıtığı olan hastalarda transabdominal preperitoneal tamir sonuçlarını irdelemek.

**Yöntemler:** Transabdominal preperitoneal yöntemle bilateral kasık fıtığı tamiri uygulanan tüm hastalarda prospektif olarak sosyodemografik veriler, hastalık ve operasyona ait veriler ile postoperative veriler değerlendirildi. Uzun dönemde hastalar kronik ağrı ve nüks açısından takip edildi.

**Bulgular:** Toplam 70 hasta (67 [95.7%] erkek, ortalama yaş 53.4±13.6) çalışmaya dahil edildi. İki hastada ameliyat esnasında tek taraflı fıtık saptandığından toplam 138 fıtık (Nyhus tip 3 [n=116; %84.1]) tamiri yapıldı. Ortalama operasyon süresi 80.6±26.5 dakikaydı. İki hastada inferior epigastrik ven yaralanması görüldü. Sadece 10 (%14.3) hastada parenteral analjezik ihtiyacı gelişti. Ortalama hastanede kalış süresi 1.21±0.67 gün olup sadece 9 (%12.8) hastada bir günden fazla yatış gerekti. İş veya normal aktivitelere dönüş süresi 10.5±4.7 gündü. Hastalar ortalama 25.9±19.4 ay takip edildi. Semptomatik nüks 2 (%1.4) hastada gelişti. Kronik ağrı ise 6 (%8.7) hastada saptandı.

**Sonuç:** Bilateral kasık fıtıklarında transabdominal preperitoneal tamir bir alternatif olarak düşünülebilir.

**Anahtar kelimeler:** Kasık fıtığı, fıtık tamiri, nüks, laparoskopi

Received/Geliş tarihi: 26.02.2018 Accepted/Kabul tarihi: 4.05.2018



Address for Correspondence/Yazışma Adresi: Istanbul Medipol University, School of Medicine, General Surgery, Istanbul, Turkey

Phone/Telefon: +90-505-923-1965 E-mail/E-posta: drmustafahaksal@yahoo.com

Atif/Citation: Haksal M, Okkabaz N, Civil O, Kement M, Oncel M. Transabdominal preperitoneal repair for bilateral inguinal hernias: a single center experience. Bakırköy Tıp Dergisi 2018;14:216-21. <https://doi.org/10.5350/BTDMJB.20180226105912>

## INTRODUCTION

The lifetime chance of a person to undergo an inguinal hernia repair is reported to be as high as 27.0% and 3.0% for men and women, respectively (1). Accordingly, hernia repair is one of the most common procedures in general surgery practice.

Although there is no agreement on a gold standard technique, it has been shown that the use of a mesh is associated with a reduced rate of recurrence (2). In addition, debate continues on whether laparoscopy has advantages over conventional anterior mesh repair techniques in patients with unilateral inguinal hernia. A recent meta-analysis evaluating trials comparing the outcomes of totally extraperitoneal technique vs. Lichtenstein's procedure, which is an anterior mesh application method, has not revealed any statistical difference between two practices regarding the risks of chronic pain, recurrences and severe adverse events (2). Besides, a recent survey on endoscopic surgeons has shown that laparoscopic technique is preferred as the first approach for inguinal hernia repair, although most physicians have declared that they considered a tailor-made approach (3).

Laparoscopic hernia repair may be more beneficial in patients with bilateral inguinal hernias, for whom a doubled size incision will be necessary, if an open technique is preferred, compared to the cases with unilateral hernia. A recent analysis comparing 10,120 patients with unilateral or bilateral inguinal hernias treated with transabdominal preperitoneal repair revealed that primary outcomes including period of disability, and the rates of morbidity, reoperation and recurrence were similar in patients with unilateral and those with bilateral hernias (4). In addition, the place of laparoscopic surgery was evaluated at least in three prospective trials, although the studies might be criticized to be underpowered for assessing risks of techniques, particularly recurrence. Sarli et al. (5) showed on 43 low-risk male patients that transabdominal preperitoneal technique might be more beneficial over tension-free open operation regarding postoperative pain, requirement for analgesics and time to return to work, although it increased the cost. Another study evaluating transabdominal preperitoneal vs. open techniques in cases with bilateral or recurrent inguinal hernias revealed that

transabdominal preperitoneal repair was quicker, less painful and it allowed earlier return for work (6).

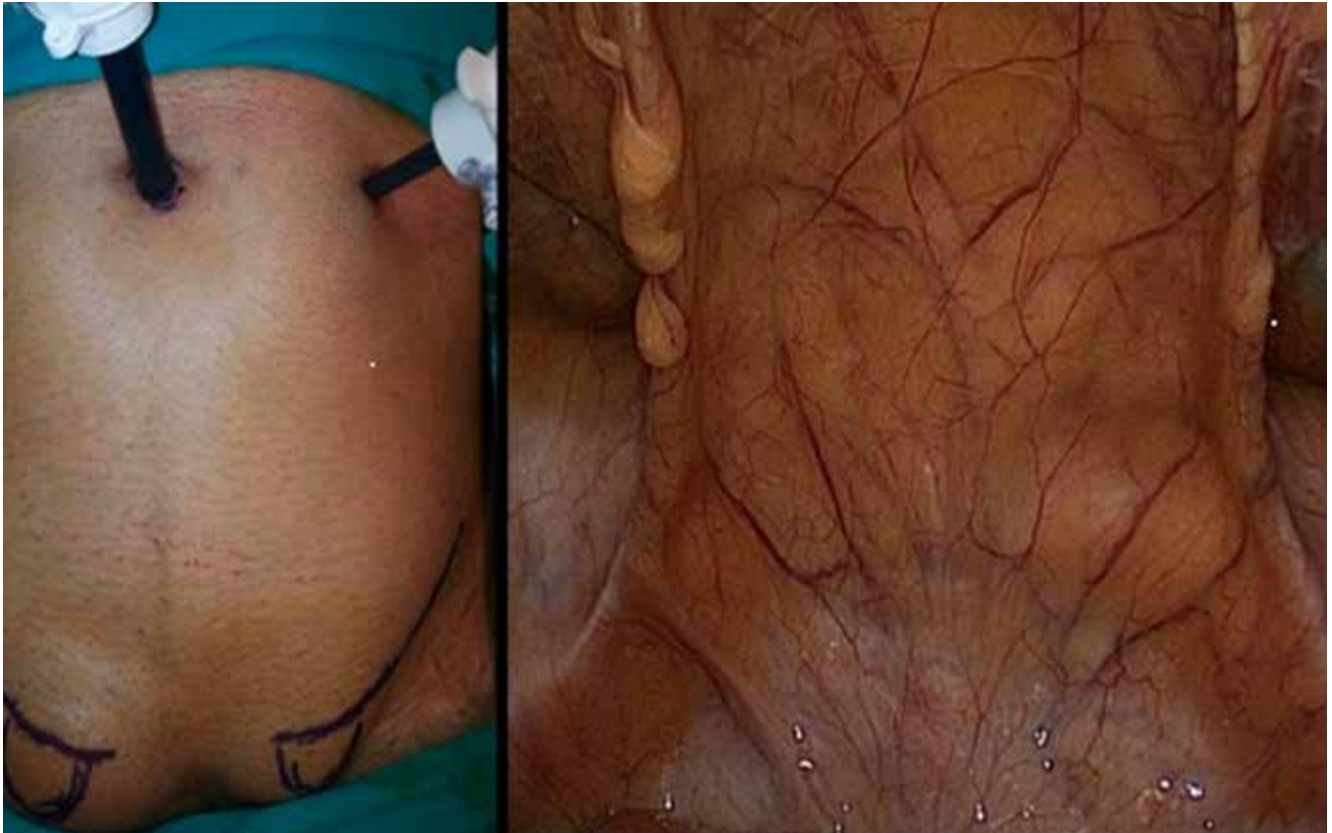Finally, a recent prospective non-randomized study evaluating the outcomes of laparoscopic vs. open approach after bilateral inguinal hernia repair revealed that totally extraperitoneal procedure was faster, associated to less complications, and promised a shorter recovery (7). Also, a survey revealed that most surgeons prefer the laparoscopic technique (93.0% vs. 7.0%) instead of the open procedure in cases of bilateral hernia (3).

Although the results of totally extraperitoneal and transabdominal preperitoneal repair techniques have been compared in prospective randomized trials or in large volume scale series of patients with unilateral hernias, there is a lack of prospective randomized information analyzing the outcomes of these methods in case of bilateral hernias (8,9). In addition, it has been reported in a systemic review that there are no significant differences between outcomes of both techniques regarding operation time, hematoma development, deep/mesh infections, length of hospitalization, time to return activity, and recurrence, but transabdominal preperitoneal repair is associated with higher risks of port-side hernias and visceral injuries (10). On the other hand, more surgeons have declared that they prefer to use transabdominal preperitoneal technique, particularly in difficult hernias, such as obese patients and large scrotal hernias (3).

Thus, the aim of the current prospective study is to analyze the experience of a single center on the short- and long-term results of transabdominal preperitoneal technique in patients with bilateral inguinal hernias.

## MATERIALS AND METHODS

A prospective study analyzing feasibility of transabdominal preperitoneal repair for patients with bilateral inguinal hernias has been completed in the beginning of 2012. The Institutional Ethics Committee approved the design and content of the study (B104İSM4340029/1009/36). Written consent was obtained from all patients. All consecutive patients with bilateral inguinal hernias were included into the study; unless the case was under 18 years old, or additional intraabdominal procedures were required, or the patient had a previous



**Figure 1:** The view of bilateral inguinal hernia after the insufflation (on the left) and from the inside (on the right). (Arrows: medial umbilical folds, a: left inguinal hernia sac, b: right inguinal hernia sac)

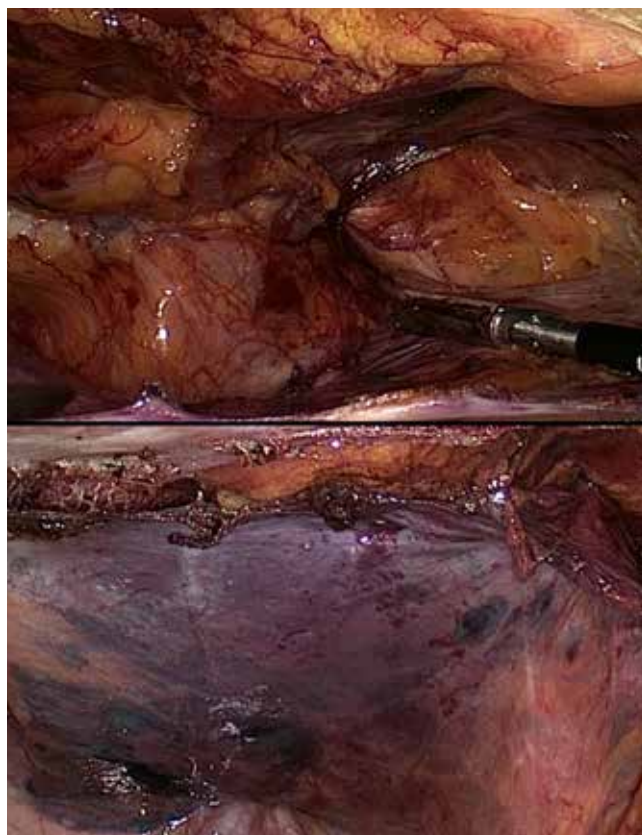
lower abdominal laparotomy. Cases with huge hernia sac (some of Nyhus type 3b) or femoral hernia (Nyhus thpe 3c) were also excluded.

The procedures were performed under general anesthesia, and a three-trocar technique was used (Figure 1). All procedures were performed or supervised by one of two staff surgeons (MO or NA). In case of a supervision, which was experienced in most patients, a resident completed the procedure, and the supervising surgeon controlled the camera. Dissection was continued with scissors or 5-mm Ligasure™ (Covidien, Baltimore, USA). The supervising surgeon decided the type and size of the mesh considering the patient's anatomy and weight. Tacks were used for attaching the mesh to the abdominal wall (Figure 2). The 10 mm trocar side used for camera insertion was closed at the end of the procedures. In order to prevent hematoma, hernia sides were tightly dressed for 24 hours postoperatively.

These data were prospectively abstracted and noted in a

computer program: patient- (demographics and American Anesthesiology Society [ASA] score), disease- (hernia type according to Nyhus classification) and procedure-related (operation time, technical details, intraoperative complications) information, and postoperative data (pain level, complications and hospitalization period). Parenteral analgesics were used on patients' request. Hernias were classified according to Nyhus classification, which graded the inguinal hernias according to type of the disease as type 1 indirect sac with normal internal ring, type 2 indirect sac with dilated internal ring, type 3a direct hernia, type 3b indirect hernia with weak inguinal floor or sliding hernia, type 3c femoral hernia and finally type 4 recurrent hernia (11).

During the follow-up period, patients were observed for at least 18 months. The exact time for return back to work was noted. Routine examination was performed and recurrences were confirmed by ultrasound examinations. The patients were accepted to have recurrences, only if the



**Figure 2:** The dissection is continued until the hernia sac (a) is entirely taken down and inguinal ligament (arrows) is completely exposed (top). After mesh fixation is completed, the peritoneal flap (b) is closed with tacks (bottom).

findings were correlated with patients' symptoms. Finally, presence of chronic pain was assessed in the 6th month postoperatively during the clinical visit by questioning whether they suffered from any continuous or activity-induced pain at the operation side.

Data were presented as percentages, mean and standard deviations or median and ranges.

## RESULTS

A total of 70 cases (67 [95.7%] males with the mean age of  $53.4 \pm 13.6$  years) were included. Patients' ASA scores were 1 ( $n=27$ ; 38.6%), 2 ( $n=36$ , 51.4%) and 3 ( $n=7$ , 10.0%). In 2 cases, intraoperative evaluation denied the presence of an inguinal hernia at one side; accordingly unilateral repair was completed in these patients. Consequently, a total of 138 hernias were repaired in 70 cases (Table 1).

**Table 1.** Demographics, operative and follow-up variables

Age (years)	53.4±13.6
Gender (male) (n, %)	67 (95.7)
Hernia types <sup>*†</sup> (n, %)	
2	20 (14.5)
3a	97 (70.3)
3b	19 (13.8)
4	2 (1.4)
Operation time (min)	80.6±26.5
Analgesic need (n, %)	10 (14.3)
Length of hospital stay (days)	1.2±0.7
Symptomatic recurrence (n, %)	2 (2.9)
Chronic pain on hernia side (n, %)	6 (8.7)

\*According to Nyhus, †Based on number of hernias.

Mean operation time was  $80.6 \pm 26.5$  minutes. No intraoperative complication was observed except inferior epigastric vein bleeding in 2 (1.4%) procedures. Hemorrhage was stopped with Ligasure™ (Covidien, Baltimore, USA). Postoperative hematoma was observed after 4 (2.9%) repairs, and all were spontaneously reabsorbed. Parenteral analgesics were required in a few patients. Patients were discharged from the hospital  $1.21 \pm 0.67$  days postoperatively, and only 9 (12.8%) cases were hospitalized more than one day (Table 1).

Postoperative follow-up protocol revealed that patients returned work or normal activity  $10.5 \pm 4.7$  days after the surgery. The mean follow-up period was  $25.9 \pm 19.4$  months (at least 18 months). Routine physical examination and ultrasound findings in suspected cases revealed recurrence in 7 (5.1%) hernia sides, but symptomatic recurrence which was confirmed by ultrasonographic examination was observed after 2 repairs (1.4%) [2 (2.9%) of all patients]. Both required conventional repairs with Lichtenstein technique. On the other hand, two cases who has bilateral hernia but underwent unilateral repair had no symptomatic hernia on the non-repaired side or no symptomatic recurrence on the repaired side at 32 and 37 months of follow up. Finally, patients were questioned whether they had any continuous or activity-induced pain at the operation side, and 6 (8.7%) cases declared that they were suffering from chronic pain (Table 1).

## DISCUSSION

Controversy continues on the role of laparoscopic repair in case of bilateral inguinal hernias. Some believe that

laparoscopy may result in early recovery and a reduction of chronic pain, compared to the Lichtenstein technique, which is considered as the reference standard in many Western Europe countries (2,12). Besides, bilateral hernias may be the best indication for laparoscopic repair, since they require a doubled-size incision during a conventional technique. Consequently, it has been reported that most surgeons prefer laparoscopic technique for these cases (3). Current prospective study aims to analyze outcomes of transabdominal preperitoneal repair procedure on 70 consecutive patients with bilateral inguinal hernias. Most hernias have been classified as Nyhus type 3, and most cases have been low-risk patients staged as ASA 1 or 2.

Perioperative outcomes of transabdominal preperitoneal repair in case of bilateral inguinal hernias were analyzed in the current study. Information evaluating laparoscopic repair revealed a huge variation in operation time reaching up to an average period of 123 minutes in a series (13). Besides, operation time was similar or longer in the current data when it was compared to the large scale studies evaluating results of transabdominal preperitoneal repair for bilateral hernias (4,14).

The rate of perioperative complication was reasonable in our series. Hemorrhage from inferior epigastric vessels was a rare complication (15). It has been recently reported in a society guideline that bleeding from epigastric branches, vessels on the pubic bone or testicular vessels might occur in 2.75% of cases, and in additional 3.0% of patients, inferior epigastric vessels were ligated because they blocked the view of the surgeon during operation (16). We have observed this complication in 2 (2.7%) patients. In addition, seroma/hematoma was occurred after 4 (2.9%) repairs. However, we have not observed other complications including visceral injury, mesh infection, and conversion or port side hernia; each of which were reported to happen less than 1.0% of patients in the recent review (16). Finally, only 9 patients required a hospitalization period more than a day, and patients returned work or normal activity in an average of 10.5 days. Pain was not a major complication after hernia repair, but the decrease in pain has been considered as a valuable early postoperative benefit of laparoscopic hernia repair. A recent prospective randomized study revealed that laparoscopic hernia repair was associated to a decreased level of postoperative pain when it was compared to Lichtenstein

technique (17). In the current study, analgesics were used according to patients' preference; and only 10 (14.3%) cases needed them. In our opinion, these data support the hypothesis that transabdominal preperitoneal repair may be a practical approach in patients with bilateral inguinal hernia, because perioperative outcomes after this technique are satisfactory.

Besides, postoperative chronic pain and recurrence are considered to be the most important outcomes and critical for decision making in patients with hernias (2). Chronic pain is a disappointing complication of hernia repair; and a recent guideline has suggested informing the patient about this problem, because it may happen up to 25.0% (16) of cases. In the current study, 8.7% of cases declared that they had chronic pain at the operation side. Recurrence after transabdominal preperitoneal procedure is rare, but was reported to occur up to 5.0% (18). In a recent review, the recurrence rates after transabdominal preperitoneal repair were 1.33% and 0.77% in two different series with 8,507 and 17,695 patients, respectively (16). Although 7 repairs in 6 patients resulted with suspected recurrences in our series, 2 patients had symptomatic recurrences requiring reoperation. In our opinion, the rates of chronic pain and recurrence are tolerable in the current study.

Current study has some limitations mostly related to its design. Since it is a single-armed study, it has not analyzed benefits and limitations of transabdominal preperitoneal technique in a comparative basis with other operative approaches. In addition, the study size hinders reliable conclusions particularly those about complications and recurrence, because they are rarely encountered. However, as the study has been planned in a prospective manner, and it includes all consecutive patients, we believe that it contributes significant information on transabdominal preperitoneal repair in patients with bilateral inguinal hernias.

In conclusion, perioperative complications rarely occur in patients undergoing a transabdominal preperitoneal procedure. Most patients do not require parenteral analgesics after surgery and the risk for seroma/hematoma rate is acceptable. Patients are generally discharged from the hospital on the next day of the operation and return back working/normal activity within days. The risks for chronic pain and recurrence are tolerable. Thus, we believe that transabdominal preperitoneal may be a feasible approach for the treatment of bilateral inguinal hernias.

**Ethics Committee Approval:** Ethics committee approval was received for this study from the local ethics committee.

**Informed Consent:** Informed consent was obtained.

**Author contributions:** Conception/Design of study -M.C.H., M.O.; Data acquisition - O.C., N.O.; Data analysis/Interpretation - N.O., M.K.;

Drafting manuscript - M.C.H., M.K., N.O.; Critical revision of manuscript - O.C., M.O.; Final approval and accountability - M.C.H., N.O., O.C., M.K., M.O.; Supervision -M.O.

**Conflict of Interest:** Authors declared no conflict of interest.

**Financial Disclosure:** Authors declared no financial support.

## REFERENCES

1. Timișescu L, Turcu F, Munteanu R, et al. Treatment of bilateral inguinal hernia - minimally invasive versus open surgery procedure. *Chirurgia (Bucur)* 2013;108:56-61.
2. Koning GG, Wetterslev J, van Laarhoven CJ, Keus F. The totally extraperitoneal method versus Lichtenstein's technique for inguinal hernia repair: a systematic review with meta-analyses and trial sequential analyses of randomized clinical trials. *PLoS One* 2013;8:e52599. [\[CrossRef\]](#)
3. Morales-Conde S, Socas M, Fingerhut A. Endoscopic surgeons' preference for inguinal hernia repair: TEP, TAPP, or OPEN. *Surg Endosc* 2012;26:2639-43. [\[CrossRef\]](#)
4. Wauschkuhn CA, Schwarz J, Boekeler U, Bittner R. Laparoscopic inguinal hernia repair: gold standard in bilateral hernia repair? Results of more than 2800 patients in comparison to literature. *Surg Endosc* 2012;24:3026-30. [\[CrossRef\]](#)
5. Sarli L, Iusco DR, Sansebastiano G, Costi R. Simultaneous repair of bilateral inguinal hernias: a prospective, randomized study of open, tension-free versus laparoscopic approach. *Surg Laparosc Endosc Percutan Tech* 2001;11:262-7. [\[CrossRef\]](#)
6. Mahon D, Decadt B, Rhodes M. Prospective randomized trial of laparoscopic (transabdominal preperitoneal) vs open (mesh) repair for bilateral and recurrent hernia. *Surg Endosc* 2003;17:1386-90. [\[CrossRef\]](#)
7. Feliu X, Claveria R, Besora P, et al. Bilateral inguinal hernia repair: laparoscopic or open approach? *Hernia* 2011;15:15-8. [\[CrossRef\]](#)
8. Belyansky I, Tsirlina VB, Klima DA, et al. Prospective, comparative study of postoperative quality of life in TEP, TAPP, and modified Lichtenstein repairs. *Ann Surg* 2011;254:709-14. [\[CrossRef\]](#)
9. Gong K, Zhang N, Lu Y, et al. Comparison of the open tension-free mesh-plug, transabdominal preperitoneal (TAPP), and totally extraperitoneal (TEP) laparoscopic techniques for primary unilateral inguinal hernia repair: a prospective randomized controlled trial. *Surg Endosc* 2011;25:234-9. [\[CrossRef\]](#)
10. McCormack K, Wake BL, Fraser C, et al. Transabdominal preperitoneal (TAPP) versus totally extraperitoneal (TEP) laparoscopic techniques for inguinal hernia repair: a systematic review. *Hernia* 2005;9:109-14. [\[CrossRef\]](#)
11. Nyhus L. Individualization of hernia repair. *Surgery* 1993;114:1-2.
12. Grant AM, EU Hernia Trialists Collaboration. Laparoscopic versus open groin hernia repair: meta-analysis of randomized trials based on individual patient data. *Hernia* 2002;6:2-10. [\[CrossRef\]](#)
13. Tatuli F, Chetta G, Caputi A, Mastrototaro P, Ruggieri T. Laparoscopic inguinal hernia repair: audit of our experience with laparoscopic trans-abdominal properitoneal repair (TAPP). *Chir Ital* 2009;61:47-63.
14. Olmi S, Erba L, Bertolini A, Scaini A, Croce E. Fibrin glue for mesh fixation in laparoscopic transabdominal preperitoneal (TAPP) hernia repair: indications, technique, and outcomes. *Surg Endosc* 2006;20:1846-50. [\[CrossRef\]](#)
15. Schultz L, Graber J, Pietrafitta J, Hickok D, Laser laparoscopic herniorrhaphy: a clinical trial preliminary results. *J Laparoendosc Surg* 1990;1:23-5. [\[CrossRef\]](#)
16. Bittner R, Arregui ME, Bisgaard T, et al. Guidelines for laparoscopic (TAPP) and endoscopic (TEP) treatment of inguinal Hernia [International Endohernia Society (IEHS)] *Surg Endosc* 2011;25:2773-843. [\[CrossRef\]](#)
17. Wang WJ, Chen JZ, Fang Q, et al. Comparison of the effects of laparoscopic hernia repair and Lichtenstein tension-free hernia repair. *J Laparoendosc Adv Surg Tech A* 2013;23:301-5. [\[CrossRef\]](#)
18. Fitzgibbons RJ Jr, Camps J, Cornet DA, et al. Laparoscopic inguinal herniorrhaphy: results of a multicenter trial. *Ann Surg* 1995;221:3-13. [\[CrossRef\]](#)