

## Spinal arteriovenous malformation: use of intraoperative color Doppler ultrasonography guidance for surgical resection. Case report.

Ozdil Baskan<sup>1</sup>, Emre Durdag<sup>2</sup>, Serdar Geyik<sup>1</sup>, Ilhan Elmaci<sup>2</sup>

<sup>1</sup>Department of Radiology, <sup>2</sup>Department of Neurosurgery, Istanbul Medipol University, School of Medicine, Istanbul, Turkey

### Abstract

Spinal arteriovenous malformations (AVMs) may be associated with sensory and motor deficits, bowel or bladder dysfunction, radicular pain or deficit, and back pain. Hemorrhage can occur in the parenchyma leading to the acute onset of symptoms. Neurosurgical resection is one of the way of treatment. Several techniques including intraoperative angiography, dye-injection and the micro Doppler method have proven to be useful during the surgical resection of spinal vascular lesions. Herein, we report our experience with intraoperative ultrasonography (IOUS) and color Doppler ultrasonography guidance for visualizing a spinal cord AVM during surgery. IOUS is a time-saving and noninvasive method for intraoperative imaging of spinal AVM.

**Keywords:** spinal arteriovenous malformations, neurosurgical resection, intraoperative ultrasound.

### Introduction

Arterial and venous vascular malformations of the spinal cord represent a heterogeneous group of vessel disorders that affect the tissue of the spinal cord either directly or indirectly [1]. Spinal arteriovenous lesions may be associated with sensory and motor deficits, bowel or bladder dysfunction, radicular pain and back pain. Hemorrhage can occur in the parenchyma and subarachnoid space of the spinal cord, leading to the acute onset or sudden worsening of neurological deficits. The risk of hemorrhage is greater in spinal cord arteriovenous malformations (AVMs) (Type II) than in other types of lesions. Neurosurgical resection is the choice of treatment especially for type II malformations [2]).

In recent years, intraoperative tools such as fluorescence angiography, Doppler ultrasonography and intraoperative digital subtraction angiography (DSA) have

been used adjunctively to confirm excision of the vascular malformations [2,3]. However, these tools have their own respective disadvantages like being time consuming. With real-time images, intraoperative ultrasonography (IOUS) can inform neurosurgeons about the location of the lesion, its relation to the spinal cord and the residual following the excision.

Herein, we present our experience with the use of IOUS and color doppler ultrasonography in a patient with intramedullary glomus AVM (Type II) to localize before surgical removal and to confirm total resection after surgery.

### Case report

A 53 year old woman presented with an acute onset back pain and weakness of the legs. Paraparesis, bilateral superficial sensory disturbance below the T12 level and disturbance of bladder were detected on neurological examination.

Patient underwent magnetic resonance imaging (MRI). T2-weighted (fig 1a), T1-weighted images revealed intramedullary hemorrhage in the spinal cord extending from the T11-12 level to the conus. Following contrast administration focal linear and nodular enhancement in the spinal cord and clustered tortuous

Received 23.07.2014 Accepted 19.08.2014

Med Ultrason

2014, Vol. 16, No 4, 386-388

Corresponding author: Ozdil Baskan

Tasli Cikis sk. 8/4 Kabatas Beyoglu

34427 Istanbul Turkey

Phone: +90 533 437 26 87

Fax: (0212) 460 70 70

Email: ozdil.baskan@yahoo.com

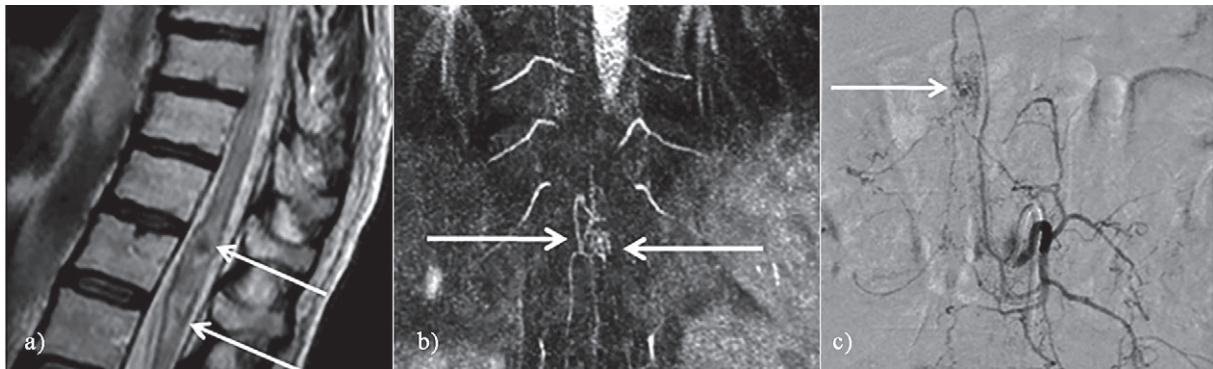


Fig 1. Preoperative; sagittal T2-weighted (a) image revealed intramedullary hemorrhage in the spinal cord extending from the T11-12 level to the conus (arrows). The high resolution contrast enhanced MRA (b) demonstrated tortuous vascular structures (arrows). Spinal DSA (c) from the left L1 intercostal artery demonstrated an AVM (arrow) which was supplying by ASA.

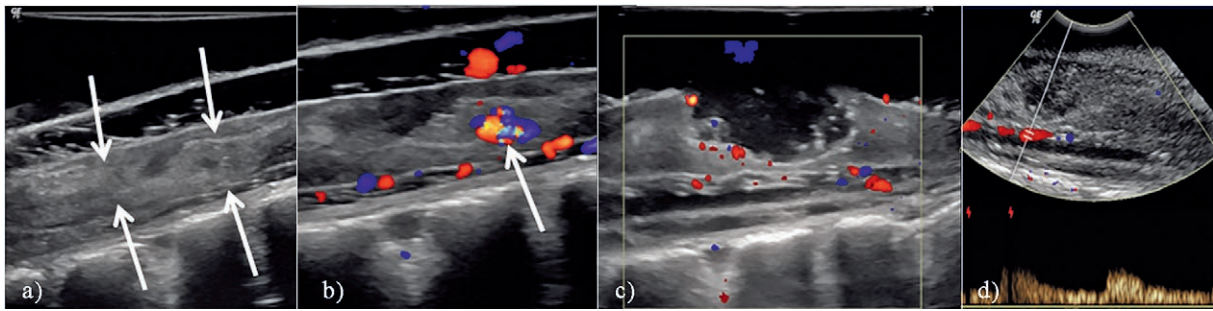


Fig 2. IOUS (a) showed intramedullary multilobulated hyperechogenic and isoechogenic focal areas in the distal spinal cord at the level T11-12 (arrows), the color Doppler ultrasound (b) showed high-velocity, high turbulence vessels within a focal nodular component in the proximal part of the hemorrhage that was thought to belong the nidus (arrows). Following a midline myelotomy, after resection of the multilobulated focal hemorrhagic areas and a nodular component the repeated the color Doppler IOUS (c), showed no intramedullary vascular lesion. The ASA flow was demonstrated with spectral Doppler ultrasonography (d).

extramedullary vascular structures were detected. The high resolution contrast enhanced magnetic resonance angiography (MRA) demonstrated tortuous vascular structures that anterior spinal artery (ASA) end on (fig 1b). The MRI findings were consistent with vascular malformation-AVM. **Spinal** DSA from the left L1 intercostal artery demonstrated an AVM which was supplying by ASA (fig 1c).

The patient underwent a T10-L1 laminectomy. We performed IOUS before the dura was opened, used Logiq p6 (GE Healthcare, Madison, WI) and a linear array transducer (7-11 MHz). The operation site was filled with sterile saline and scanning was done without touching the dura mater. With conventional B-mode sonography, intramedullary multilobulated hyperechogenic and isoechogenic focal areas in the distal spinal cord were detected. The color Doppler ultrasound mode showed high-velocity, high turbulence vessels within a focal nodular component in the proximal part of the hemorrhage that was thought to belong the nidus (fig 2a,b).

The dura was opened under the operative microscope and physiological monitoring. Tortuous vessels were detected on the dorsal surface of the spinal cord. Following a midline myelotomy, multilobulated focal hemorrhagic areas and a nodular component were detected intramedullary. After the resection the color Doppler IOUS was repeated (fig 2c) and no intramedullary vascular lesion was detected. We demonstrated the ASA flow with spectral Doppler ultrasonography (fig 2d). Postoperative MRI and MRA demonstrated disappearance of the enhancing lesion and of the tortuous vascular structures, respectively.

## Discussions

Spinal vascular malformations are rare entities that, if not treated properly, can lead to considerable morbidity with progressive spinal cord symptoms. All types of arteriovenous shunts or vascular malformations account for 3% to 16% of all space-occupying lesions of the spinal cord [4].

Arteriovenous shunts and vascular malformations in the spinal cord region are classified based on their nidus location, vascular supply, and drainage pattern. The lesions are divided into 4 types: type I – the typical dural arteriovenous fistula (DAVF); type II – glomus AVM; type III – juvenile AVMs, without an obvious nidus; type IV – perimedullary DAVF. Type II lesions are glomus AVMs, with a mass of dysmorphic arteries and veins without an intervening capillary bed inside a short segment of the spinal cord. These lesions can be partial or entirely intramedullary [5]. There is a high rebleeding rate if the AVM is not treated; therefore, prompt recognition and treatment is warranted [4].

Reid first applied IOUS to visualize and diagnose an intramedullary spinal cord tumor in 1978 with a low frequency sector scanner [6]. IOUS was used for brain and spinal lesions especially in intra-axial brain tumor surgeries. Furthermore, intraoperative color Doppler US has been used in intracranial vascular lesions [7], cerebral and spinal AVMs and aneurysms [8], and a spinal perimedullary fistula [9].

MRI, CT fluorescence angiography and intraoperative DSA have been used for intraoperative imaging in neurosurgical operations over the last few years [2]. In spite of higher resolution, these techniques are not practical and difficult to repeat for real-time imaging during surgery. In comparison, IOUS is of low cost and easily accessible, can be adapted for various applications in surgery [3,7-9].

IOUS helps surgical planning with its capability of continuous and real-time visualization of intradural spinal lesions. IOUS could help to locate the lesion and optimize the localization and dimension of the incision of the dura and myelotomy. IOUS imaging will point the location of the lesion and show the shortest way to reach it. By real time imaging of the lesion surgeons can plan an image-guided optimal removal of lesions. In the present case we identified the locations and margins of the parenchymal changes and hemorrhages by using conventional B-mode sonography. By using the color Doppler ultrasound we demonstrated the vascular morphology of the lesion. A focal nodular component with high turbulence vessels in the proximal part of the parenchymal changes was detected. Intraoperative color Doppler ultrasonography can detect the abnormal vessels, navigate easily the vascular lesions and also provides information about the flow direction and velocity. We used spectral Doppler ultrasonography to control the patency of the ASA after the resection of the lesion.

Despite multiple reports, IOUS is not commonly and routinely used as a diagnostic tool in many countries. IOUS is a quick, inexpensive, widely available, and easy to apply imaging modality that provides the experienced user with real-time information [10]. Furthermore, image quality may decrease with ongoing resection because of blood and air bubbles in the surgical field during resection of lesions.

In this paper, the use of IOUS and color Doppler ultrasonography in surgical removal of spinal AVM is reported. IOUS provides real-time information about the precise location of the lesion and the residual following excision. IOUS is a useful and practical intraoperative tool that helps to improve surgical precision and might reduce the procedure related morbidity.

### References:

1. Causin F, Gabrielli J, Orrù E. Classification and Treatment of Vascular Malformations of the Spinal Cord. In: Muto Mario. Eds. *Interventional Neuroradiology of the Spine*. Springer-Verlag Italy, 2013: 231-248.
2. Yamamoto S, Kim P. Spinal Arteriovenous Fistulas and Arteriovenous Malformations – Complicated Vasculature and Surgical Imaging. In: Stavropoula I, Tjoumakaris. Ed. *Arteriovenous Fistulas and Arteriovenous Malformations*. InTech, 2013.
3. Zhou H, Miller D, Schulte DM, et al. Intraoperative ultrasound assistance in treatment of intradural spinal tumours. *Clin Neurol Neurosurg* 2011; 113: 531-537.
4. da Costa L, Dehdashti AR, terBrugge KG. Spinal cord vascular shunts: spinal cord vascular malformations and dural arteriovenous fistulas. *Neurosurg Focus* 2009; 26: E6.
5. Wang VY, Chou D, Chin C. Spine and spinal cord emergencies: vascular and infectious causes. *Neuroimaging Clin N Am* 2010; 20: 639-650.
6. Reid MH. Ultrasonic visualization of a cervical cord cystic astrocytoma. *AJR Am J Roentgenol* 1978; 131: 907-908.
7. Eide PK, Sorteberg AG, Meling TR, Sorteberg W. Directional intraoperative Doppler ultrasonography during surgery on cranial dural arteriovenous fistulas. *Neurosurgery* 2013; 73(2 Suppl Operative): 211- 222.
8. Black KL, Rubin JM, Chandler WF, McGillicuddy JE. Intraoperative color-flow Doppler imaging of AVM's and aneurysms. *J Neurosurg* 1988; 68: 635-639.
9. Seki T, Hida K, Lee J, Yano S, Iwasaki Y. Intraoperative color Doppler sonography in the surgical treatment of perimedullary arteriovenous fistula--case report. *Neurol Med Chir (Tokyo)* 2005; 45: 100-103.
10. Reinacher PC, van Velthoven V. Intraoperative ultrasound imaging: practical applicability as a real-time navigation system. *Acta Neurochir Suppl* 2003 ;85: 89-93.