

Condensing osteitis of the clavicle in a man: Any relationship with tooth decay?

Inci Baltepe Altioğ, ¹ Mehmet Tokmak, ² Tarik Akman, ³ Bahadır Alkan, ⁴ Murat Cosar ⁵

Abstract

Condensing osteitis of the clavicle is a rarely seen pathology since its first description in 1974. Although mechanical stress is claimed for aetiology, but remains a dilemma for physicians. The intermittent or steady pain is variable in intensity and generally localised at the medial end of the involved clavicle, supraclavicular fossa, ipsilateral anterior thorax and shoulder.

In this report, we present a 28-year-old man with the regression of the condensing osteitis of the clavicle after the extraction of a decayed tooth.

Keywords: Clavicle, Condensing osteitis, Mechanical stress, Tooth.

Introduction

Osteitis condensans of the clavicle has been frequently reported in literature.^{1-3,5-7} Its aetiology is uncertain, but some reports presumed mechanical stress to be a causative factor.^{1,4,8} Our case report is about regression of the condensing osteitis of the clavicle in a man after the extraction of a decayed tooth. Oral infection may affect the course and pathogenesis of a number of systemic diseases.⁹ There is perhaps a relationship between osteitis condensans of the clavicle and dental carries and it may be a multifactorial disease.

Case Report

A 28-year-old man was admitted to a university hospital in 1999. He had two-year history of pain in the left shoulder, left anterior thorax around the left sternoclavicular joint which was present at rest. It was increasing with the abduction of the shoulder. At first his symptoms were mild and intermittent. Subsequently, pain episodes became more intense and more frequent, requiring treatment with various anti-inflammatory medication. But they produced only transient relief. Physical examination revealed localised soft tissue swelling and tenderness over the left sternoclavicular joint. There was no

.....
¹Department of Radiology, Istanbul Medipol Hospital, ²Faculty of Medicine, Department of Neurosurgery, Istanbul Medipol University, Istanbul, ³⁻⁵Faculty of Medicine, Department of Neurosurgery, Canakkale 18 Mart University, Canakkale, Turkey.

Correspondence: Tarik Akman. Email: tarkakman@yahoo.com.tr

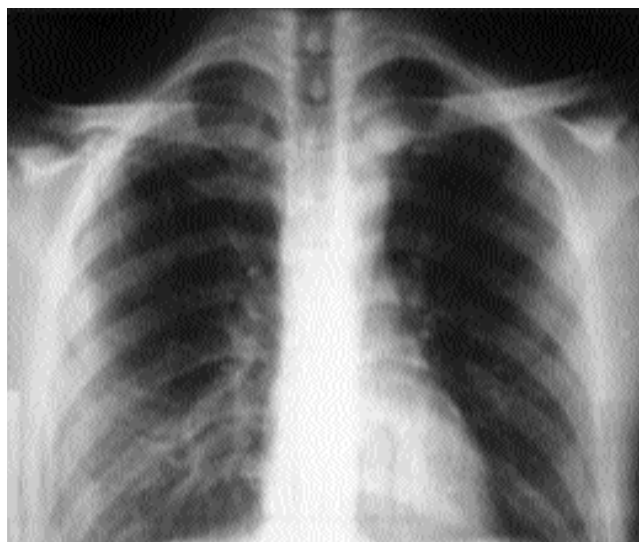


Figure-1: Plain film radiograph, demonstrating condensing osteitis as an area of increased density in inferior half the of the medial head of the left clavicle.

erythema. The motion of the left sternoclavicular joint and, to a lesser degree, the left glenohumeral joint were limited.

Plain film radiography of the left sternoclavicular joint revealed condensation of the inferior half of the medial end of the left clavicle (Figure-1). A bony spur projected from inferomedial aspect of the left clavicular head. Computed tomography (CT) verified these findings and revealed narrowed sternoclavicular joint space, no evidence of subchondral pseudocyst, bony destruction or

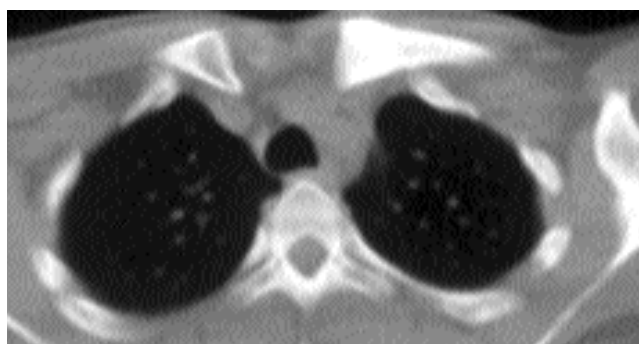

Figure-2: Computed tomography scanning of the clavicles demonstrated sclerosis of the marrow space of the medial end of the left clavicle.

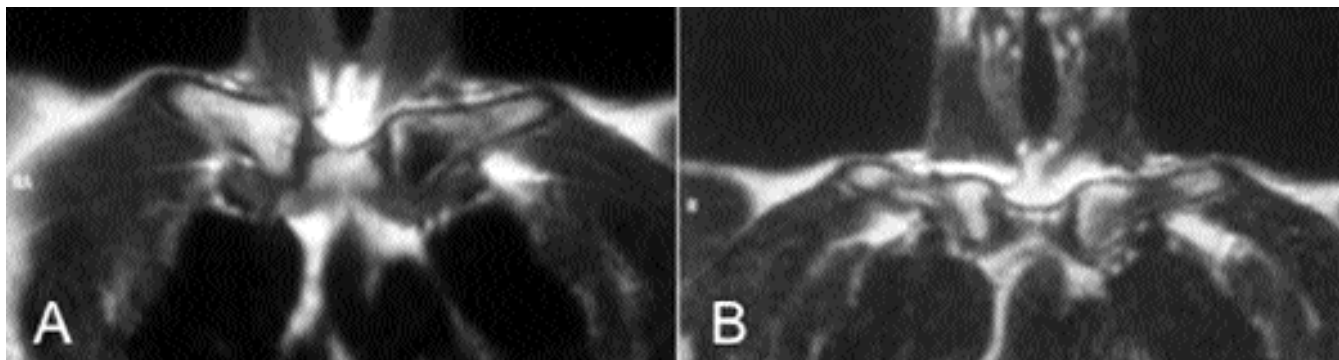


Figure-3: (A) T1 weighted and (B) T2 weighted coronal images. There is low signal in the medullary component in T1 weighted image. T2 weighted image shows both hypointense and isointense signal in the medullary component of the medial end of the left clavicle.

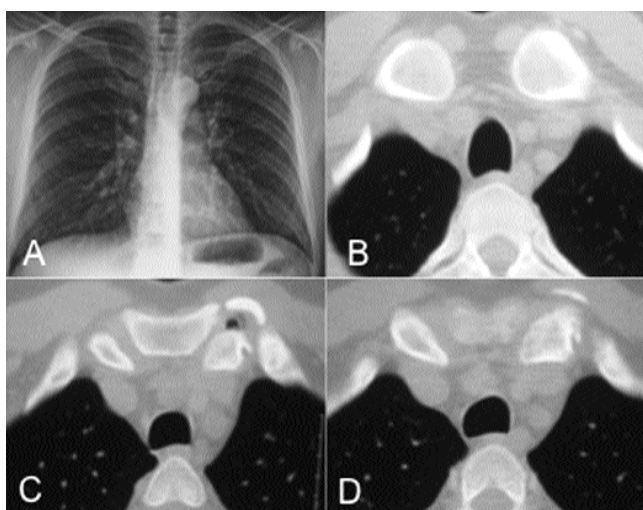


Figure-4: Plain film radiograph and Computed tomography scanning demonstrating regression of the condensing osteitis. There is an inferior spur, joint space narrowing, vacuum phenomenon in the joint space as a sequela.

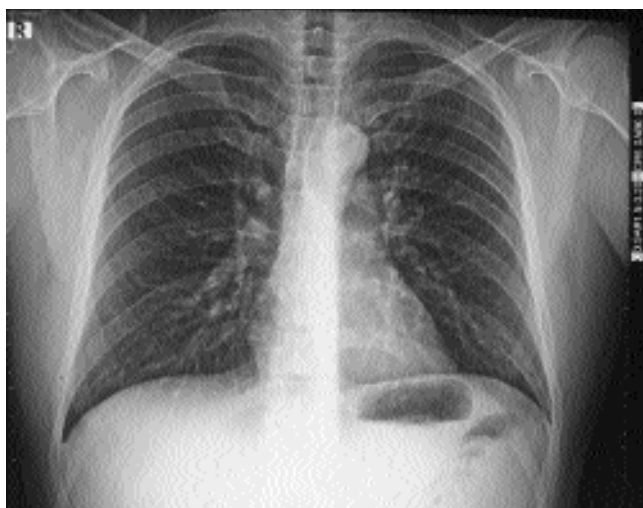


Figure-5: No recurrence at plain film radiograph taken in year 2013.

soft tissue mass (Figure-2). Magnetic resonance imaging (MRI) was performed (Figure-3). T1-weighted SE (spin echo) images revealed hypointense signal intensity corresponding to areas of sclerosis. On T2-weighted images, areas of sclerosis appeared as regions of hypointense and isointense signal intensity. There was hyperintense signal on both T1 and T2-weighted images of the sternal side of the sternoclavicular joint. This finding, joint space narrowing and bony spur were presumed to be due to secondary degenerative changes. There was no fluid in the sternoclavicular joint and on T2-weighted images there was hyperintense signal in the peri-articular soft tissue representing soft tissue oedema as a reactive finding. Blood tests, aspiration or bacteriological test were not done because of the suggestive clinical and radiological findings. The patient had pain for nearly six years after the diagnosis, till his molar decayed tooth had an abscess and was extracted in 2005. After the extraction, he never felt the pain again. After nearly six months, CT scan revealed complete regression of the sclerosis of the clavicle (Figure-4). There was no recurrence at control plain film radiograph taken in 2013 (Figure-5).

Discussion

Condensing osteitis of the clavicle was first described in 1974.¹ It is a rare benign entity and characterised by variably painful and tender swelling over the medial end of the clavicle. The lesion appears to occur most often in women who are of late child-bearing age. By the time the patient first seeks medical attention, the symptoms usually will have been present for months or years.² The pain is described as intermittent or steady and is variable in intensity. The pain is usually localised to medial end of the involved clavicle and it may radiate to supraclavicular fossa, ipsilateral anterior thorax and shoulder. Movement of the shoulder, particularly abduction or forward elevation, tends to aggravate the pain, but the range of

motion is seldom reduced. A fusiform firm, variably tender, swelling ultimately appears in the region of the medial end of the clavicle. The changes like erythema in the overlying skin that would suggest infection or inflammation are absent and tenderness is generally mild. Systemic complaints are invariably denied by the patient and general physical examination reveals no related abnormalities.² The aetiology of condensing osteitis of the clavicle is uncertain, but several authors thought that mechanical stresses might be the cause.^{1,4,8} There was mechanical stress in the history of our patient too. But the cessation of intense pain and regression of the condensing osteitis after the extraction of the decayed tooth make us think that condensing osteitis of the clavicle may be a multifactorial disease. To our knowledge, any association between osteitis condensans of the clavicle and dental infections has not been reported in literature. Three mechanisms or pathways linking oral infection to secondary systemic effects have been proposed: (i) metastatic spread of infection from oral cavity as a result of transient bacteraemia, (ii) metastatic injury from the effects of circulating oral microbial toxins, (iii) metastatic inflammation caused by immunological injury induced by oral micro-organisms.⁵ Because bacteriology of the biopsy specimen is negative in all reported cases, we think that effects of circulating oral microbial toxins or immunological injury induced by oral bacteria may play a role in the pathogenesis of osteitis condensans of the clavicle. This relationship may explain

some studies which have mentioned regression of the findings after antibiotic treatment.⁹

Conclusion

Because of abrupt cessation of intense pain after the extraction of the decayed tooth and regression of radiological findings after six months, it won't be wrong to say that there may be a strong relationship between osteitis condensans of the clavicle and dental carries.

References

1. Brower AC, Sweet DE, Keats TE. Condensing osteitis of the clavicle: a new entity. *AJR Am J Roentgenol* 1974; 121: 17-21.
2. Kruger GD, Rock MG, Munro TG. Condensing osteitis of the clavicle. *J Bone Joint Surg Am* 1987; 69: 550-7.
3. Rand T, Schweitzer M, Rafii M, Nguyen K, Garcia M, Resnick D. Condensing osteitis of the clavicle. *J Computer Assisted Tomography* 1998; 22: 621-4.
4. Harden SP, Argent JD, Blaquiére RM. Painful sclerosis of the medial end of the clavicle. *Clin Radiol* 2004; 59: 992-9.
5. Galla R, Basava V, Conermann T, Kabazie AJ. Sternoclavicular steroid injection for treatment of pain in a patient with osteitis condensans of the clavicle. *Pain Physician* 2009; 12: 987-90.
6. Patel HC, Lopez-Ben R, Ken AJ, Gene P.S. Painful sclerotic medial clavicle in a 46-year-old woman. *Clin Orthopaedics Related Res* 2003; 414: 342-46.
7. Appell RG, Oppermann HC, Becker W, Kratzat R, Brandeis WE, Willich E. Condensing osteitis of the clavicle in childhood: A rare sclerotic bone lesion. *Pediatr Radiol* 1983; 13: 301-6.
8. Jones MW, Carty H, Taylor JF, Ibrahim SK. Condensing osteitis of the clavicle: Does it exist? *J Bone Joint Surg* 1990; 72: 464-7.
9. Li X, Kolltviet KM, Tronstad L, Oslen I. Systemic diseases caused by oral infection. *Clin Microbiol Rev* 2000; 13: 547-58.

Copyright of Journal of the Pakistan Medical Association is the property of Pakistan Medical Association and its content may not be copied or emailed to multiple sites or posted to a listserv without the copyright holder's express written permission. However, users may print, download, or email articles for individual use.