

## A rare congenital liver anomaly: Hypoplasia of left hepatic lobe

Tugrul Ormeci,<sup>1</sup> Secil Telli Erdogan,<sup>2</sup> Asli Ormeci,<sup>3</sup> Cem Aygun<sup>4</sup>

### Abstract

Morphologic anomalies of liver, as opposed to many other visceral organs, are very rare. Hypoplasia or agenesis of left lobe of the liver is defined as the absence of liver tissue on the left side of liver without previous disease or surgery. It is usually an incidental finding revealed by imaging exams or during abdominal surgery. A 44-year-old female patient was admitted to the hospital for abdominal pain and discomfort. Physical examination revealed no specific abnormality. Routine laboratory tests were normal. Imaging studies showed the absence of the left hepatic lobe. She had no history of surgery, trauma or liver disease and was diagnosed as having congenital hypoplasia of left hepatic lobe. Anomalies of hepatic morphology are due to developmental defects during embryogenesis and are rarely seen. They are generally diagnosed incidentally based on imaging techniques. Early diagnosis of such an anatomical anomaly is necessary for surgical planning, for appropriate evaluation of intraoperative surgical findings, and for the design of the postoperative approach to therapy.

**Keywords:** Liver, Congenital, Left lobe hypoplasia.

### Introduction

Congenital anomalies of liver are extremely rare. Hypoplasia or agenesis of lobes, absences of segments, deformed lobes, decreased sizes of lobes, gall bladder agenesis or transposition and Riedel's lobe are among the various abnormalities reported. Normally liver is divided into eight segments and still, for many liver diseases including hepatocellular cancer, resection of the affected segment is the most effective treatment modality. To know the detailed anatomical infrastructure of liver parenchyme before any intervention or surgery is very crucial. The diagnosis of congenital anomaly requires some criteria such as no evidence of previous surgery, trauma or any disease leading to hepatocellular

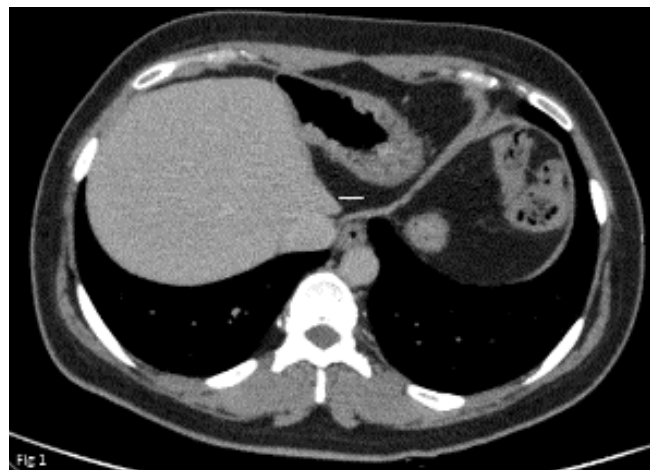
.....  
<sup>1</sup>Radiology Department, Medipol Mega University, <sup>2</sup>Radiology Department, Medipol Mega Hospital Complex, <sup>3</sup>Division of Gastroenterology, Department of Internal Medicine, Haseki Research and Training Hospital, Istanbul, <sup>4</sup>Division of Gastroenterology, Department of Internal Medicine, Medipol University Hospital, Istanbul, Turkey.

**Correspondence:** Seçil Telli Erdogan. Email: seciltelli@hotmail.com

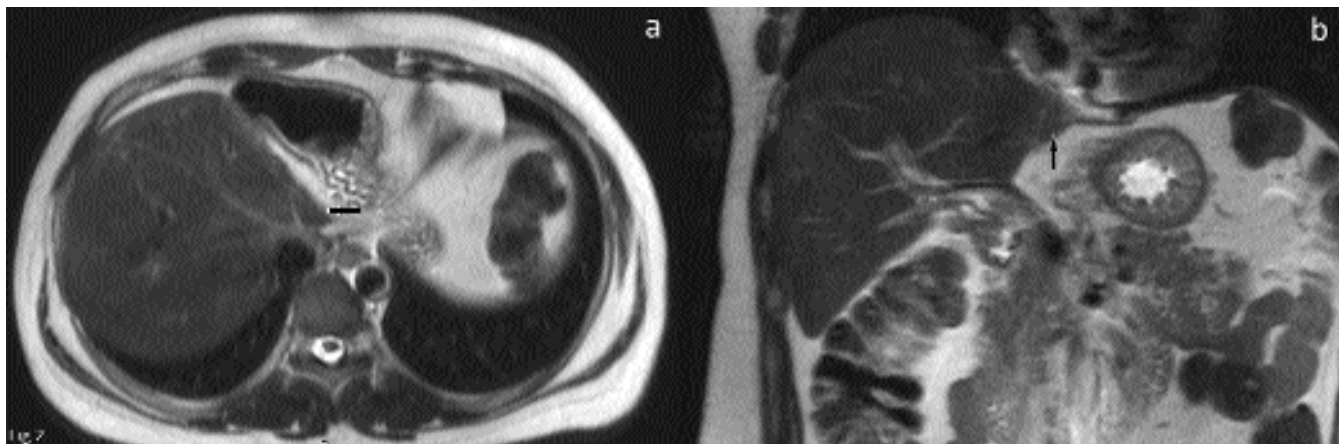
dysfunction and atrophy.<sup>1-3</sup> In this report we aimed to present the clinical and radiologic findings of a case with hypoplasia of left hepatic lobe.

### Case Report

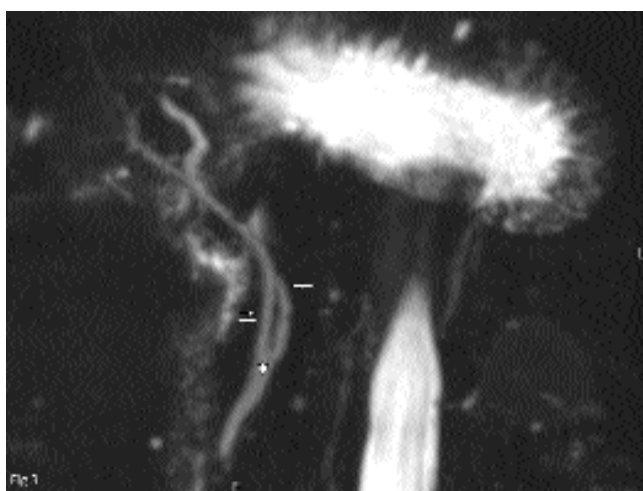
A 44-year-old female patient was admitted to the outpatient clinics of Medipol University Hospital, Istanbul, Turkey, for left upper quadrant abdominal pain and discomfort in June, 2015. Physical examination revealed no specific abnormality. Routine laboratory tests were normal except the urine analysis which showed mild haematuria. As a part of diagnostic work up, an abdominal ultrasound (US) was performed revealing a benign renal simple cyst with a thin wall that did not contain septae, calcifications, or any solid component. In the same US examination right lobe of liver was noticed as hypertrophied and left liver lobe was hypoplastic. Liver parenchymal echogenicity and biliary ducts on the right lobe were apparently normal. Contrast enhanced computed tomography (CT) was performed to evaluate the hepatic lobes and gall bladder in detail. CT images revealed enlargement of the right hepatic lobe, especially medial segment. The left hepatic lobe was hypoplastic and a linear structure of low attenuation formed a boundary between left and right hepatic lobes. Gall bladder was located posterior to the medial and lateral segment of the right lobe. Left branch of portal vein and



**Figure-1:** The left lobe medial segment (subsegments 4a) are partially observed in contrast enhanced CT (arrow). However, lateral segment of the left lobe is not seen.



**Figure-2:** Appearance of hypoplastic left lobe medial segment is seen in axial T2-TSE (a) and coronal T2-TSE (b) MRI (arrows).



**Figure-3:** 3D magnetic resonance cholangiopancreatography (MRCP) High Resolution coronal image of the right hepatic duct (double arrow) and the common bile duct (asterisk) are in normal view. The left intrahepatic bile ducts and proximal of the left hepatic duct are not observed, however distal part of it is seen incompletely (arrow).

left hepatic vein could only be followed shortly (Figure-1). To evaluate the biliary system in detail, magnetic resonance cholangiopancreatography (MRCP) was also performed. MRCP showed normal common and right biliary ducts while left hepatic biliary duct could only be followed shortly (Figure-2). Since the patient had no clinical sign of liver disease on physical examination, normal biochemical liver function tests and no history of surgery or trauma, she was diagnosed as having congenital hypoplasia of left hepatic lobe.

## Discussion

Absence of a hepatic lobe is a rare anomaly of liver development. It is usually noted incidentally at autopsy or surgery. Clinically most of the patients with absence of

right or left hepatic lobes are generally asymptomatic. Since most of the cases are asymptomatic physicians usually do not notice them very often.

Using the most accepted nomenclature, the liver is divided into eight segments. The caudate lobe alone represents segment I. Segment II is the superior portion of the lateral segment of the left hepatic lobe. Segment III is the inferior portion of the lateral segment of the left hepatic lobe. Segment IV occupies the entire medial segment of the left hepatic lobe. Segment V is the inferior portion of the anterior segment of the right hepatic lobe. Segment VI is the inferior portion of the posterior segment of the right hepatic lobe. Segment VII is the superior portion of the posterior segment of the right hepatic lobe. Segment VIII is the superior portion of the anterior segment. In our patient we observed that segment I, II, III and most of IV was absent. Only a small remnant part of segment IV could be seen as the unique part of left lobe. Before any intervention or surgery, to know the differentiations of these segments is highly important.<sup>4,5</sup>

Congenital agenesis of a liver lobe affects the left lobe more than right liver lobe. Some of these patients had additional anomalies such as partial or complete absence of the right side of the diaphragm, intestinal malrotation, or choledochal cyst. The incidence of the left lobe anomalies was seen more frequently than right lobe especially in the cadavers. In our patient there was no additional anomaly of diaphragm, choleduct or intestines which explained why she was symptom free. Actually similar left lobes anomalies could be even higher in society since we do not notice them because these cases are usually asymptomatic. Rarely, defective development of the left lobe of the liver can lead to severe

complications like gastric volvulus. Pages et al. categorized anomalies of morphology related to developmental defects as follows: Agenesis (absence of a lobe that is replaced by fibrous tissue); aplasia (one of the lobes is small and its structure is abnormal, with few hepatic trabeculae, numerous bile ducts, and abnormal blood vessels); or hypoplasia (one of the lobes is small but is normal in structure).<sup>1</sup> According to this classification, our case could be categorized as hypoplasia. The recognition of this entity is facilitated by examining the left portal vein, left hepatic vein and left bile duct with no right side abnormality or intrahepatic duct dilation. In our patient we could see the short branches of left portal vein, hepatic vein and bile duct with a small paranchyme of segment IV. Aplasia and hypoplasia differ from lobar atrophy which results from acquired vascular and biliary diseases. The differential diagnosis includes hepatic cirrhosis, cholangiocarcinoma with atrophy due to biliary obstruction and prior ablative surgery.

Surgical knowledge of such anatomical liver lobe hypoplasia is necessary for any hepatic intervention or surgical planning, for the appropriate identification of intraoperative surgical findings and for the design of the postoperative approach to therapy.<sup>6-8</sup> However, knowledge of the diagnosis and adequate orientation are even much more important for the patient because the chance that he or she will aggravate any disease related to this anatomical alteration is quite high. Awareness of such

variations is also crucial to physicians for distinguishing new variants or new developmental defects and imagery specialists for avoiding misinterpretation of CT and MRI.

### Conclusion

Awareness of variation as liver hypoplasia is crucial for both clinicians and radiologists. Imaging features should be kept in mind when evaluating a patient with liver lobe agenesis.

**Disclosure:** None.

**Conflict of Interest:** None.

### References

1. Pages A, Marty-Double C. Les Malformations Constitutionnelles du Foie et des Voies Biliaires Intrahepatiques. Paris, France : Ed Varia; 1972.
2. Kakitsubata Y, Nakamura R, Mitsuo H, Suzuki Y, Kakitsubata S, Watanabe K. Absence of the left lobe of the liver: US and CT appearance. *Gastrointest Radiol.* 1991; 16:323-5.
3. Nacif LS, Buscariolli Ydos S, D'Albuquerque LA, Andraus W. Agenesis of the right hepatic lobe. *Case Rep Med.* 2012; 415742: 1-3.
4. Demirci A, Diren HB. Computed tomography in agenesis of the right lobe of the liver. *Acta Radiol.* 1990; 31:105-6.
5. Bismuth H. Surgical anatomy and anatomical surgery of the liver. *World J Surg.* 1982; 6:3-9.
6. Kakitsubata Y, Kakitsubata S, Asada K, Watanabe K. Anomalous right lobe of the liver: CT appearance. *Gastrointest Radiol.* 1991; 16:326-8.
7. Radin DR, Colletti PM, Ralls PW, Boswell WD Jr, Halls JM. Agenesis of the right lobe of the liver. *Radiology.* 1987; 164:639-42.
8. Singh R. Hypoplastic left lobe of liver with accessory caudate lobe. *Case Rep Med.* 2013; 2013:604513.