

Closure of a persistent oroantral fistula with nasoseptal cartilage as a complication of lateral sinus lifting: A case report

Lateral sinus yükseltme komplikasyonu olarak oluşan inatçı oroantral fistülün nazoseptal kıkırdak ile kapatılması: Bir olgu sunumu

Assist. Prof. Gökhan Gürler

Istanbul Medipol University, Faculty of Dentistry, Department of Oral and Maxillofacial Surgery, Istanbul

Dr. Emrah Dilaver

Istanbul Medipol University, Faculty of Dentistry, Department of Oral and Maxillofacial Surgery, Istanbul

Assist. Prof. Erkan Soylu

Istanbul Medipol University, Faculty of Medicine, Department of Ear Nose and Throat, Istanbul

Assist. Prof. Tuba Develi

Istanbul Medipol University, Faculty of Dentistry, Department of Oral and Maxillofacial Surgery, Istanbul

Prof. Çağrı Delilbaşı

Istanbul Medipol University, Faculty of Dentistry, Department of Oral and Maxillofacial Surgery, Istanbul

Received: 27 February 2017

Accepted: 4 April 2017

DOI: 10.5505/yeditepe.2017.43434

Corresponding author

Assist. Prof. Gökhan Gürler
Istanbul Medipol University, Faculty of Dentistry,
Department of Oral and Maxillofacial Surgery
34083 Unkapanı-Istanbul
Tel: 212 453 49 40
E-mail: ggurler@medipol.edu.tr

SUMMARY

Oroantral fistula may develop due to tooth extraction, infection or surgical interventions in the posterior maxilla. Several surgical techniques have been described for oroantral fistula closure. All these techniques have different advantages and disadvantages. This report presents an oroantral fistula case, which occurred, following lateral sinus lifting procedure. Traditional surgical techniques (buccal advancement flap, palatal flap, and Bichat's buccal fat pad) were performed to close the oroantral fistula, but could not to be managed. Finally, closure was succeeded with septal cartilage graft placed over the bony defect.

Key words: Oroantral fistula, sinus lifting, septal cartilage, complication.

ÖZET

Oroantral fistül, posterior maksillada diş çekimi, enfeksiyon veya cerrahi işlemlere bağlı olarak gelişebilir. Oroantral fistülün kapatılmasına yönelik pek çok cerrahi teknik tanımlanmıştır. Bütün bu tekniklerin kendine özgü avantaj ve dezavantajları vardır. Bu olguda raporunda lateral sinüs yükseltme işlemine bağlı gelişen oroantral fistül sunulmuştur. Geleneksel cerrahi yöntemlerle (bukkal ilerletme flebi, palatal flep, Bichat bukkal yağ dokusu) kapatılamayan defekt, son olarak otojen septal kıkırdak grefti uygulanarak başarıyla kapatılabilmektedir.

Anahtar kelimeler: Oroantral fistül, sinus yükseltme, septal kıkırdak, komplikasyon.

INTRODUCTION

Oroantral fistula (OAF) is an epithelized communication between maxillary sinus and oral cavity.¹ It is mostly seen after extraction of maxillary molar and premolar teeth those root apices are anatomically adjacent to the maxillary sinus. The incidence of complication as a result of simple maxillary premolar and molar extraction varies from 0.31% to 3.8%.² Other causative factors for OAF are dentoalveolar infections, cysts or tumors that invade through maxillary sinus, Paget's disease, trauma and complication of Caldwell-Luc procedure.^{1,2,3} Commonly used surgical techniques for closure of OAF are described in the literature including buccal advancement flap, buccal fat pad, palatal island flap and buccal sliding flap^{4,5} This report presents a persistent OAF which occurred following lateral sinus lifting procedure; however, closure could not to be managed performing buccal sliding flap, palatal flap and buccal fat pad respectively. Final closure could be accomplished using autogenous septal cartilage graft.

CASE REPORT

A 44-year-old male patient referred to our clinic with a complaint of tooth loss in the bilateral posterior maxilla. Panoramic graphy and Cone Beam Computed Tomography (CBCT) revealed insufficient vertical bone for implant insertion at both sides (Figure 1).

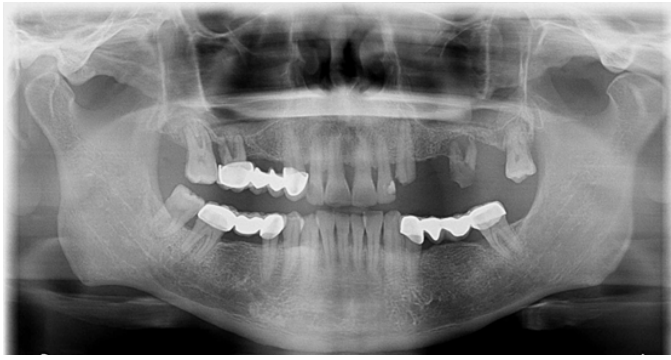

Figure 1. Preoperative panoramic graphy of the patient.

Systemic condition and maxillary sinus examination of the patient were symptomless. Bilateral lateral maxillary sinus lifting and onlay horizontal bone augmentation with otogenous mandibular symphysis block graft for the left posterior region were carried out under conscious sedation and local anesthesia. Patient was symptomless postoperatively but two months later, he referred to our department with a complaint of postnasal flow. At clinical and radiological examination, graft particles migrating from the right augmented site and antral polyp formation as well as maxillary sinusitis were observed (Figure 2a-b).

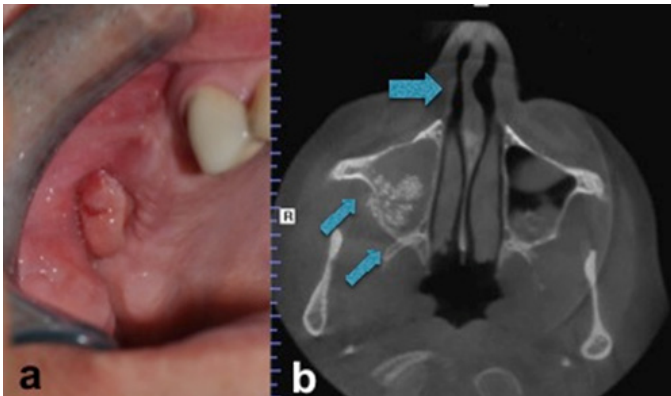


Figure 2 (a-b.) Intraoral appearance of the antral polyp (a). Axial view of the CBCT depicting right maxillary sinusitis (double arrow) and nasal septum deviation (arrow) (b).

He was prescribed antibiotic (1000 mg amoxicillin and clavulanate combination plus 500 mg metronidazole two times a day), and a decongestant (paracetamol 300 mg, phenylpropranolamin 25 mg and chlorpheniramin 2 mg) postoperatively for 10 days. Since the symptoms subsided, infected graft particles were curetted and oroantral fistula was closed with buccal advancement flap. After two weeks of follow-up there was still pus discharge from the operation site. He was again prescribed the above-mentioned drugs for another ten days and following regression of the symptoms; the fistula was re-closed with palatal flap. However, in the follow-up period of ten days the fistula recurred, wound dehiscence was observed and pus discharge re-initiated. The patient was again prescribed antibiotic and decongestant and was decided to follow-up for one month. At the end of this period the patients had no symptoms hence, the fistula was attempted to close with Bichat's buccal fat pad. Un-

fortunately, the same complaints consisted with OAF was observed again. Finally, we consulted patient's otolaryngologist. After diagnostic endoscopy and computed tomography, nasal septum deviation that restricts right maxillary sinus drainage was diagnosed (Figure 2-b and Figure 3).

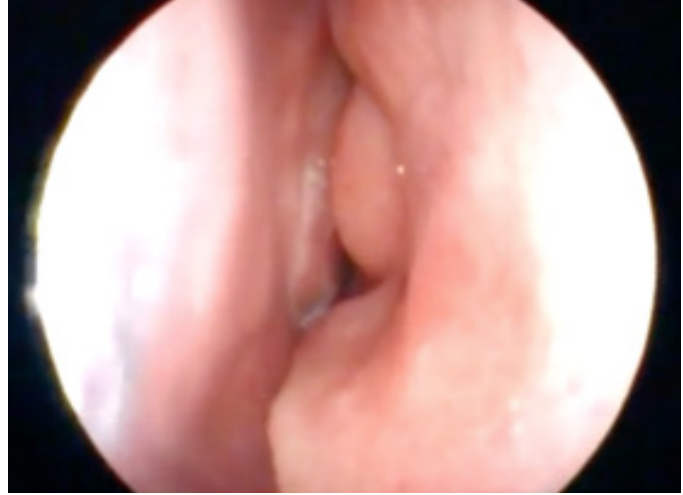

Figure 3. Intranasal endoscopic appearance.

Functional endoscopic sinus surgery (FESS) and nasal deviation correction i.e septoplasty operation were planned as well as closure of the fistula with septal cartilage obtained during the septoplasty operation. Patient was operated under general anesthesia. Local anesthetic containing epinephrine was injected in the uncinatate process and middle turbinate to control bleeding. Using a rigid 4.0 mm endoscope (Karl Storz, Tutlingen, Germany) the middle turbinate was carefully dislocated toward the septum to visualize the uncinatate process and ethmoid bulla. The uncinatate process was removed by forceps and natural ostium of the maxillary sinus was enlarged to a size sufficient for clear visualization of the sinus and its effective drainage after healing. Inflammatory polyps were removed and nasal septal cartilage graft was harvested. OAF epithelium was excised circumferentially. The mucoperiosteal flap was elevated from the buccal side of alveolar crest. Inflamed mucosa was removed under fiberoptic endoscope. Nasal septal graft was placed to cover the large opening and sutured to adjacent bone with 4/0 polydioxanone (Figure 4a-b). Soft tissue was closed with 3/0 silk suture. After one week sutures were removed. Healing was uneventful during the follow-up examination at one year (Figure 5).

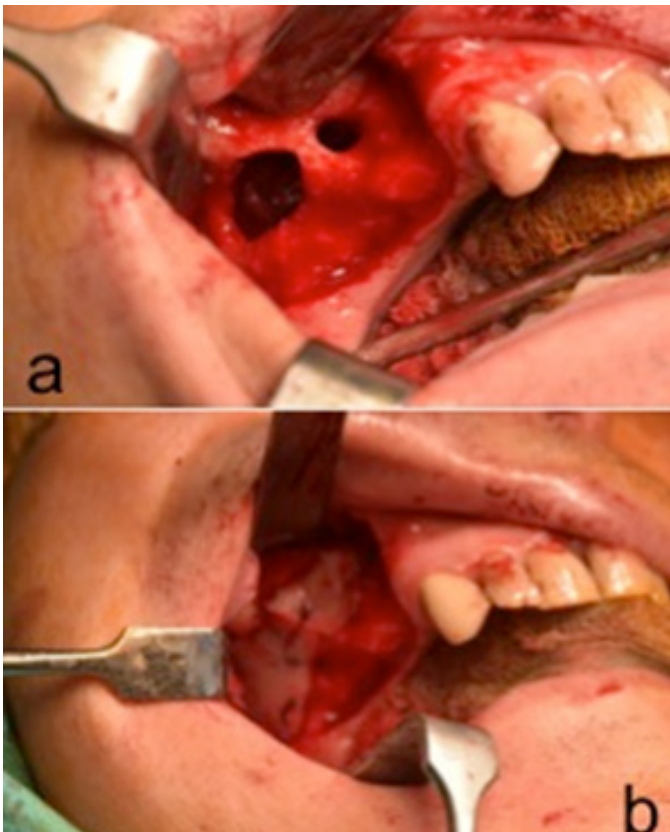


Figure 4 (a-b). Intraoperative appearance of the bony defect on the anterior wall of the maxillary sinus (a). Stabilization of the nasal septal cartilage over the bony defect (b).

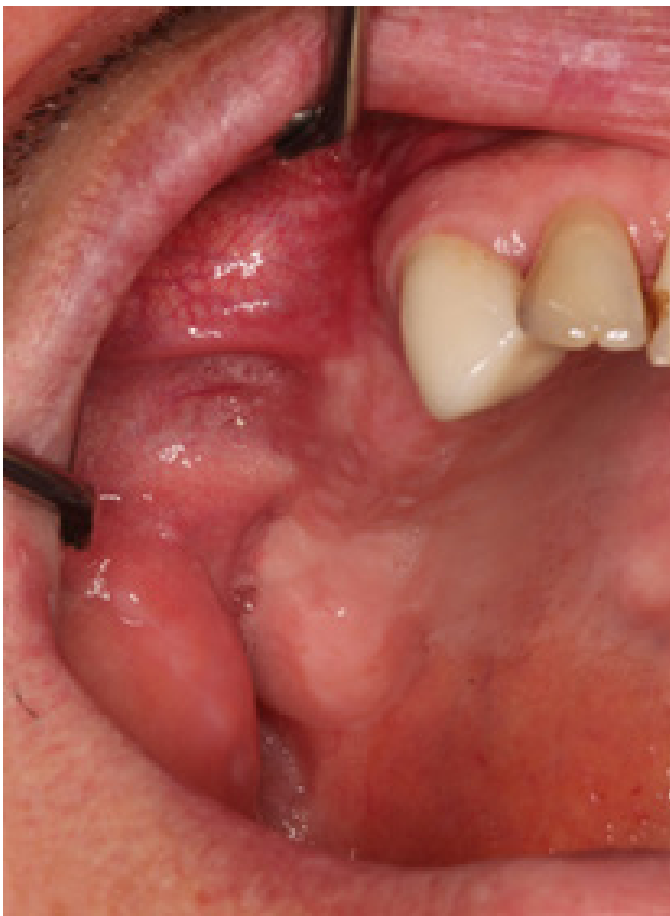

Figure 5. Postoperative view showing complete healing.

DISCUSSION

Maxillary sinus is one of the paranasal sinuses, which has a close proximity to maxillary premolar and molar teeth. The factors disrupting the continuity of sinus membrane may include; tooth extraction, pathologic lesions, trauma and surgical interventions in the posterior maxilla. Oroantral fistula is defined as the communication between maxillary sinus and oral cavity. It usually occurs after premolar and molar extractions. While the mucosal perforations smaller than 5mm heal spontaneously, larger perforations need surgical interventions.^{4,5}

Several techniques are used in oroantral fistula closure. Although buccal advancement flap and buccal fat pad are commonly used and relatively easy methods, lack of high blood perfusions may lead to recurrent fistulas.⁴⁻¹⁰ Palatal rotation flap is preferred for oroantral fistula closure with large defects, having 76.9% success rate thanks to its vascular pedicle.^{5,10} Additionally autogenous and alloplastic graft materials are used to separate the sinus membrane and oral mucosa to facilitate the closure and subsequent implant operation or sinus lifting procedure. The inflammation and infection risk of alloplastic materials and high cost limit the use of these materials in OAF closure.⁵ The use of autogenous bone grafts harvested from mandibular symphysis has successful results. Autogenous bone grafts permit defect closure and future implant insertion.

The autogenous cartilage grafts are used to close tympanic membrane perforations and cerebrospinal leakage while it is easy to adapt, well tolerated, easily manipulated, easily accessible and cost effective as well as it is resistant to resorption and infection. Autogenous cartilage grafts have less vascularity than other bone grafts. Due to low vascularity of cartilage grafts, resorption of the graft is limited.^{6,7} It can be easily trimmed and harvested from the same surgical site with minimal morbidity. Because nasoseptal cartilage is near to the field of repair and can be harvested without additional time, it is a suitable graft in OAF closure. Furthermore, there is no need to change the position of the patient and the surgeon during the operation. This technique causes no esthetic problems, there is minimal donor site complication, and also it is easy to handle.⁶

In this case we reported a persistent oroantral fistula, which recurred after several closure attempts, because of impaired sinus drainage. The closure was succeeded with FESS and simultaneous application of nasoseptal cartilage. We also emphasized the need for consultation with an ENT specialist in case of severe and persistent OAF patients.

REFERENCES

1. Lazow SK. Surgical management of the oroantral fistula flap procedures. *Oper Tech Otolaryngol Head Neck Surg* 1999; 10: 148-152.
2. Punwutukorn C, Waikakul A, Pairuchvej V. Clinically significant oroantral communications – a study of incidence and site. *Int J Oral Maxillofac Surg* 1994; 23: 19-21.
3. Kiran Kumar Krishanappa S, Prashanti E, Sumanth KN, Naresh S, Moe S, Aggarwal H, Mathew RJ. Interventions for treating oro-antral communications and fistulae due to dental procedures. *Cochrane Database Syst Rev* 2016; 27: CD011784.
4. Procacci P, Alfonsi F, Tonelli P, Selvaggi F, Menchini Fabris GB, Borgia V, De Santis D, Bertossi D, Nocini PF. Surgical Treatment of Oroantral Communications. *J Craniofac Surg* 2016; 27: 1190-1196.
5. Dergin G, Emes Y, Delilbasi C, Gurler G. Management of Oroantral Fistula. In: *A Textbook of Advanced Oral and Maxillofacial Surgery*. Volume 3. Chapter: Management of Oroantral Fistula, 367-385 pp, Intecch Publisher, 2016.
6. Mohanna PN, Kangesu L, Sommerlad BC. The use of conchal-cartilage grafts in the closure of recurrent palatal fistulae. *Br J Plast Surg* 2001; 54: 274.
7. Al-Sibahi A, Shanoon A. The use of soft polymethyl-methacrylate in the closure of oro-antral fistula. *J Oral Maxillofac Surg* 1982; 40: 165-166.
8. Kansu L, Akman H, Uckan S. Closure of oroantral fistula with the septal cartilage graft. *Eur Arch Otorhinolaryngol* 2010; 267: 1805-1806.
9. Saleh EA, Issa IA. Closure of large oroantral fistulas using septal cartilage. *Otolaryngol Head Neck Surg* 2013; 148: 1048-1050.
10. Nezafati S, Vafaii A, Ghojazadeh M. Comparison of pedicled buccal fat pad flap with buccal flap for closure of oro-antral communication. *Int J Oral Maxillofac Surg* 2012; 41: 624-628.