



A Rare Cause of Elbow Pain: Hegemann's Disease

Nadir Bir Dirsek Ağrısı Nedeni: Hegemann Hastalığı

Hegemann Hastalığı / Hegemann's Disease

Tuğrul Alıcı¹, Yunus İmren², Hakan Gündeş³

¹Özel Avusturya Sen Jorj Hastanesi, Ortopedi ve Travmatoloji Kliniği, İstanbul,

²Kars Devlet Hastanesi, Ortopedi ve Travmatoloji Kliniği, Kars, ³İstanbul Medipol Üniversitesi Ortopedi ve Travmatoloji Ana Bilim Dalı, İstanbul, Türkiye

Bu olgu sunumu 31 Ekim-5 Kasım 2011 tarihleri arasında Antalya'da düzenlenen 22. Ulusal Ortopedi ve Travmatoloji Kongresi'nde poster bildirisi olarak sunulmuştur.

Özet

Travma olmaksızın dirsek ağrısı çocuklarda ergenlik öncesi dönemde nadir görülür. Bu dönemde kronik dirsek ağrısı, şişlik ve eklem hareket kaybı osteokondral lezyonlara bağlı olabilir. Osteokondritis dissecans, subkondral kemik ile eklem kıkırdığının subkondral kemikteki bir lezyona bağlı ayrışması olarak tanımlanır. Özellikle diz, ayak bileği ve dirsek eklemlerinde görülür. Dirsek osteokondrozunda birincil olarak kapitellum etkilenmekteyken, troklea osteonekrozu ile ilgili az sayıda olgu bildirilmiştir. Bu yazıda yakın zamanda travma öyküsü olmayan, ergenlik öncesi dönemde bulunan, klinik ve radyolojik olarak tek taraflı troklea osteokondral lezyonu ile uyumlu olan bir olgu sunulmuştur. Hastada son 3 haftadır daha önce belirti vermeyen, günlük aktivitelerde ortaya çıkan sağ dirsek ağrısı mevcuttu. 2 hafta uzun kol atelde takip edilen hastada şikayetlerin devamı üzerine dirsek MR görüntülemesine ihtiyaç duyuldu. Tanı konduktan sonra cerrahi dışı tedavi ile başarılı sonuç elde edildi. Çocuklarda rezidüel deformitenin tanınması ve uygun tedavisi için takipte dikkatli olunmalıdır.

Anahtar Kelimeler

Osteokondrit; Dirsek; Ağrı

Abstract

Non-traumatic elbow pain is rarely seen in children and pre-adolescents. Osteochondral lesions may be the source of chronic elbow pain, swelling, and loss of motion in children or adolescents. Osteochondritis dissecans (OCD) is described as a lesion of subchondral bone resulting in separation of the articular cartilage and subchondral bone. It is found primarily in the knee, ankle, and elbow joints. Since osteochondrosis of the elbow primarily involves capitellum, few papers involving osteonecrosis of the trochlea have been reported. This paper discusses a pre-adolescent boy with clinical and radiographic signs consistent with unilateral osteochondral lesion of the trochlea humeri, with no history of recent trauma. The patient had insidious onset of right elbow pain during daily activities for the last 3 weeks. After usage of long arm splint for 2 weeks, persistence of the symptoms necessitated MRI of the affected elbow. After the diagnosis, non-operative management was achieved. Care should be taken for the affected children to recognize any residual deformity and to treat it properly at follow up.

Keywords

Osteochondritis; Elbow; Pain

DOI: 10.4328/JCAM.1061

Received:03.05.2012

Accepted: 27.05.2012

Printed: 01.07.2015

J Clin Anal Med 2015;6(4): 499-501

Corresponding Author: Yunus İmren, Kars Devlet Hastanesi Ortopedi ve Travmatoloji Kliniği, Örnek Mahallesi, Hastane Sokak, 36200 Kars, Türkiye.

GSM: +905423661038 E-Mail: yunusimren@yahoo.com

Introduction

Non-traumatic elbow pain is rarely seen in children and pre-adolescents. A differential diagnosis of elbow pain should include ulnar neuritis, osteochondritis dissecans, triceps tendinitis, instability and epicondylitis [1]. Osteochondral lesions may be the source of chronic elbow pain, swelling, and loss of motion in children or adolescents. Virtually dominant arm is involved. Osteochondritis is defined as an inflammation of bone and cartilage. Osteochondritis dissecans (OCD) is described as a lesion of subchondral bone resulting in separation of the articular cartilage and subchondral bone. The term "osteochondritis dissecans" was given to this condition by Franz König in 1888 (1). He described a case of knee pain that appeared to suggest a subchondral inflammatory process dissecting a fragment of cartilage from the femoral condyle. OCD involves localized avascular necrosis of subchondral bone and subsequent loss of structural support for the adjacent articular cartilage. It is found primarily in the knee, ankle, and elbow joints [2]. Osteochondrosis of the elbow primarily involves capitellum, which was first described by Panzer in 1927. Few papers involving osteonecrosis of the trochlea have been reported. Uhrmacher firstly described this condition in 1933, and then Hegemann presented three cases in 1951. Conservative treatment is usually reserved for early lesions with intact overlying cartilage and nearly half of the lesions tend to heal treated non-operatively. Strengthening exercises may be helpful after relief of symptoms. Surgery is indicated for patients who do not respond to conservative treatment, or those who have mechanical symptoms with unstable fragments and loose bodies in the elbow joint. This paper discusses a pre-adolescent boy with clinical and radiographic signs consistent with unilateral osteochondral lesion of the trochlea humeri, with no history of recent trauma.

Case Report

A right-handed 12-year-old boy had insidious onset of right elbow pain during daily activities for the last 3 weeks. No history of recent trauma, vigorous activity, and locking episode of the elbow joint were noted. There was no history of corticosteroid use and bone disease in his family. Physical examination revealed mild swelling and palpation induced tenderness on the medial epicondyle and 25° loss of active elbow extension. The carrying angle was 5° on the right and 13° on the left. There was no evidence of medial or lateral instability. Mental examination and laboratory data were within normal limits. Radiographs of the right elbow showed a slight radiolucent defect in the trochlear notch with well-defined margins (Fig.1). After usage of long arm splint for 2 weeks, persistence of the symptoms necessitated MRI of the affected elbow. The diagnosis of aseptic necrosis of the humeral trochlea was made by characteristic signal patterns of the magnetic resonance imaging. Avascular necrosis was traditionally seen as a geographic area that exhibited low signal on both T1- and T2-weighted images (Fig.2). Fluid collection was also noted in the radiohumeral joint. After the diagnosis, a long arm splint was applied for further 2 weeks. 2 months after removal of the splint, motion pain of the elbow joint disappeared and a full range of movement was achieved at 6 months after his first visit.

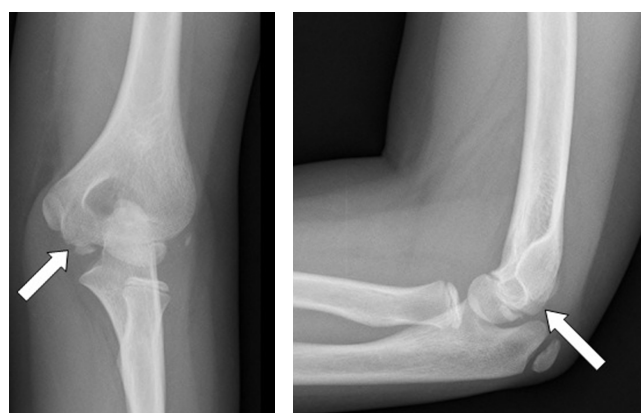

Figure 1. AP and lateral views of right elbow showing a slight radiolucent defect in the trochlear notch (A, B).

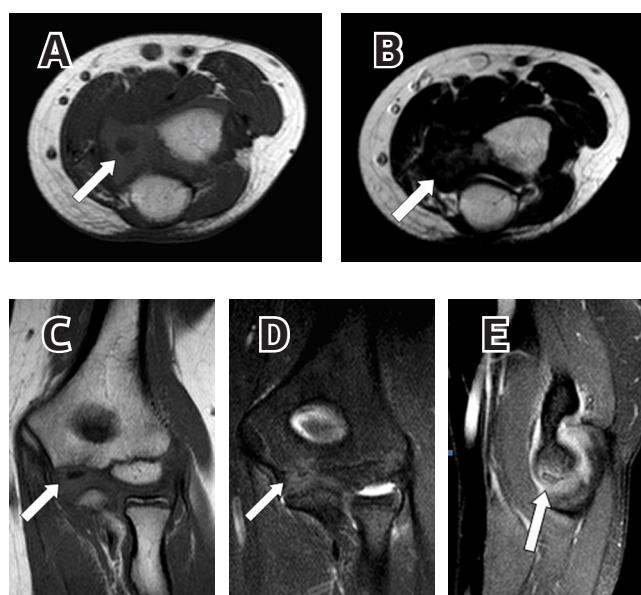


Figure 2. Right elbow axial T1 MR image showing avascular necrosis of the trochlea (A). Right elbow axial T2 MR image showing patchy avascular necrosis of the trochlea (B). Right elbow coronal T1 MR image showing the affected part of trochlea (C). Right elbow coronal T2 MR image showing the trochlear avascular necrosis (D). Sagittal T2-weighted MR image of the elbow delineating the lesion of the trochlea and effusion in the joint space (E).

Discussion

Osteochondritis dissecans (OCD) is a relatively common condition, seen predominantly in adolescents and young adults, often in males. It is recently considered as a form of osteochondral fracture caused by chronic repetitive injury. OCD is a pain syndrome primarily affecting the knee, secondarily the ankle, and occasionally the elbow involving the humerus. The overall incidence of OCD has been reported between 15-29/100000 with a significant number of lesions being asymptomatic, and male to female ratio is 2/1. Increasing incidence of OCD is found in other joints such as the ankle, elbow, shoulder, and hip (1,2). It's well-known that the ossification center of the trochlea develops between 8 and 13 years of age in boys and fuses with the metaphysis of the humerus between 13 and 16 years of age [2]. Beyer et al. [3] reviewed the literature for aseptic osteonecrosis of the trochlea and reported that this condition was primarily seen in older children and pre-adolescents. The main symptoms

were either swelling of the elbow or a limited range of movement without any history of recent trauma. Physical examination usually reveals the tenderness around the elbow joint, and the loss of elbow extension. Our patient's complaint was only the pain and restriction of elbow motion, so the carrying angle was affected. Many theories have been proposed for the etiology of osteochondritis dissecans such as ischemia, trauma, and genetic predisposition. However, none of them has been accepted universally. The ischemic theory is based primarily on the histopathologic characteristics of the lesion and also the vascular anatomy of the distal part of the humerus. Haraldsson [4] has shown that the vascular supply of the capitellum was limited with end arteries entering only the posterior portion of the distal humerus in people aged from 5 to 19 years. On the other hand, Yamaguchi et al. [5] indicated that the medial and lateral aspects of the trochlea were supplied by separate vascular arcades and there was a watershed area in the central part, therefore capitellum was mostly involved. Trauma has also been suggested as a cause of osteochondritis dissecans. History of frequent repetitive overuse of the elbow is common in people who have osteochondritis dissecans [6]. Some patients may have genetic predisposition, as suggested by the rate of osteochondritis dissecans occurring bilaterally and in multiple locations, although hereditary influences are probably slight. Kenniston JA et al. [6] presented a case report of fraternal twins with OCD lesions in their non-dominant arms without a known history of repetitive injury to the elbow. Conservative treatment was preferred for our patient since he had early lesion with no mechanical symptoms and the overlying cartilage of the elbow was intact. After initial subchondral rarefaction, condensation occurred, and contour of humeral trochlea was preserved. He was closely observed for degenerative sequela which could be seen in nearly half of patients despite non-operative treatment.

The entity of osteochondritis dissecans remains controversial, primarily due to debate over its etiology. The natural history is poorly understood and long-term sequelae include degenerative arthritis. Treatment of osteochondritis dissecans of the elbow is based on the radiographic stability of the fragment. Regardless of the etiology of osteochondral injury, the role of imaging is to provide information regarding the integrity of the overlying articular cartilage, the viability of the separated fragment, and the presence of associated intra-articular bodies [7]. The integrity of the articular surface and the stability of the lesion can be carefully evaluated with MRI and arthroscopy. MRI also provides superior soft tissue imaging and allows visualization of marrow and vasculature changes in bone. The most common indications for elbow arthroscopy include removal of loose bodies, synovectomy, debridement and/or excision of osteophytes, capsular release, and the assessment and treatment of osteochondritis dissecans [8]. Intact lesions generally respond to non-operative management, including rest, splinting, and NSAIDs. Although osteochondrosis of the humeral trochlea has similarities with Perthes disease, fortunately Hegemann's disease is a relatively more benign condition due to non-weight bearing property of the upper extremity. Non-operative management is good for lesions in skeletally immature patients given the potential for healing associated with normal subsequent function and radiographs. Care should be taken for the affected children to recog-

nize any residual deformity and to treat it properly at follow up.

Competing interests

The authors declare that they have no competing interests.

References

1. Patel N, Weiner SD. Osteochondritis dissecans involving the trochlea: report of two patients (three elbows) and review of the literature. *J Pediatr Orthop* 2002;22(1):48-51.
2. Ito K, Ogino T, Aoki M, Wada T, Ishii S. Growth disturbance in aseptic osteonecrosis of the humeral trochlea (Hegemann's Disease): a case report with developmental distal radioulnar joint incongruency. *J Pediatr Orthop* 2004;24(2):201-4.
3. Beyer WF, Hept P, Glücker K, Willauschus W. Aseptic necrosis of the humeral trochlea (Hegemann's Disease). *Arch Orthop Trauma Surg* 1990;110(1):45-8.
4. Le TB, Mont MA, Jones LC, LaPorte DM, Hungerford DS. Atraumatic osteonecrosis of the adult elbow. *Clin Orthop Relat Res* 2000;(373):141-5.
5. Yamaguchi K, Sweet FA, Bindra R, Morrey BF, Gelberman RH. The extraosseous and intraosseous arterial anatomy of the adult elbow. *J Bone Joint Surg Am* 1997;79(11):1653-62.
6. Kenniston JA, Beredjikian PK, Bozentka DJ. Osteochondritis dissecans of the capitellum in fraternal twins: case report. *J Hand Surg Am* 2008;33(8):1380-3.
7. Steinbach LS, Fritz RC, Tirman PF, Uffman M. Magnetic Resonance Imaging of the Elbow. *Eur J Radiol* 1997;25(3):223-41.
8. Dodson CC, Nho SJ, Williams RJ 3rd, Altchek DW. Elbow arthroscopy. *J Am Acad Orthop Surg* 2008;16(10):574-85.

How to cite this article:

Alici T, İmren Y, Gündeş H. A Rare Cause of Elbow Pain: Hegemann's Disease. *J Clin Anal Med* 2015;6(4): 499-501.