

# Prospective observational study on antibiotic-associated bloody diarrhea: report of 21 cases with a long-term follow-up from Turkey

Mesut Yilmaz<sup>a</sup>, Yesim Aybar Bilir<sup>b</sup>, Gökhan Aygün<sup>c</sup>, Yusuf Erzin<sup>e</sup>, Recep Ozturk<sup>b</sup> and Aykut Ferhat Celik<sup>d</sup>

**Objective** Antibiotic-associated hemorrhagic colitis is a distinct form of antibiotic-associated bloody diarrhea (AABD) in which *Clostridium difficile* is absent. Although the cause is not exactly known, reports have suggested the role of *Klebsiella oxytoca* and/or *C. difficile*.

**Materials and Methods** Between 2001 and 2006, stool samples of 21 consecutive patients with AABD were cultured for common enteric pathogens and *K. oxytoca*, and were tested for the presence of parasites and *C. difficile* toxin A + B within the first 24 h of their initial admission and a colonoscopy was performed when available. The patients were followed up prospectively by telephone interviews.

**Results** The occurrence of symptoms ranged between 6 h and 14 days following the first dose of the antibiotic responsible and the duration of the AABD ranged between 6 h and 21 days. The antibiotic responsible was oral ampicillin/sulbactam in 18 (85%) cases. *C. difficile* toxin A + B production by enzyme-linked immunosorbent assay and *K. oxytoca* growth in stool cultures were detected in six (29%) and 11 (51%) of 21 patients, respectively. Endoscopic morphology and histology in a limited number of patients revealed no more than a nonspecific inflammation and acute colitis, respectively.

## Introduction

Diarrhea is a frequent adverse effect of antibiotic therapy, with an incidence varying between 5 and 25%, depending on the antibiotic used [1]. Hemorrhagic colitis is also a well-known complication of treatment with antibiotic agents. Antibiotic-associated colitis is generally considered to be caused by an overgrowth of toxin-producing *Clostridium difficile* in the colon; however, a subset of patients may be identified as having a distinct form of antibiotic-associated colitis and this is called antibiotic-associated hemorrhagic colitis (AAHC) because of *Klebsiella oxytoca* [2,3]. Toffler *et al.* [4] were the first to describe this form of colitis during therapy with penicillins. The disease has also been reported after antibiotic therapy with quinolones and cephalosporins [5,6].

In contrast to antibiotic-associated colitis induced by *C. difficile*, AAHC is considered to resolve spontaneously after cessation of the antibiotic responsible [4,5,7].

Recent evidence suggests that *K. oxytoca*, a Gram-negative facultative aerobic enterobacterium found in surface water,

**Conclusion** This study confirms that antibiotic-associated hemorrhagic colitis, as a distinct entity in relation to *K. oxytoca*, is seen in half of the patients with AABD. Most of the cases are seen within a week following the antibiotic use. Almost all of the patients did not develop any flares during the long-term antibiotic-free follow-up. In some of the patients with AABD, there was coexistence of *K. oxytoca* with *C. difficile* toxin A + B. *Eur J Gastroenterol Hepatol* 24:688–694 © 2012 Wolters Kluwer Health | Lippincott Williams & Wilkins.

European Journal of Gastroenterology & Hepatology 2012, 24:688–694

**Keywords:** antibiotic-associated bloody diarrhea, antibiotic-associated hemorrhagic colitis, *Clostridium difficile*, *Klebsiella oxytoca*

<sup>a</sup>Department of Infectious Diseases and Clinical Microbiology, Istanbul Medipol University, <sup>b</sup>Department of Infectious Diseases and Clinical Microbiology, <sup>c</sup>Department of Microbiology and Clinical Microbiology, <sup>d</sup>Department of Gastroenterology, Cerrahpasa Medical Faculty, Istanbul University and <sup>e</sup>Department of Gastroenterology, Yeditepe University, Istanbul, Turkey

Correspondence to Mesut Yilmaz, MD, Unkapanı, Atatürk Bulvarı No. 27, 34083 Fatih Istanbul, Turkey  
Tel: +90 212 453 4856; fax: +90 212 531 7555;  
e-mail: myilmaz@medipol.edu.tr

Received 22 December 2011 Accepted 10 February 2012

sewage, soil, and plants and present in up to 38% of adult stool samples, is a cause of AAHC [6,8]. *K. oxytoca* constitutively produces chromosomal  $\beta$ -lactamases that confer resistance to aminopenicillins. Strains that overproduce these  $\beta$ -lactamases or extended-spectrum  $\beta$ -lactamases may cause AAHC because of an overgrowth by the selective pressure of the antibiotics used.

Few cases of AAHC have been reported in the literature [4,7,9–12]. The onset is usually sudden, with severe lower abdominal pain and cramping, and up to 20 loose stools in 24 h. These clinical findings are not specific for AAHC and may exist in the presentation of any form of colitis.

The exact causes of AAHC still remain controversial. Sakurai and colleagues were the first to report the presence of *K. oxytoca* in patients with AAHC after oral ampicillin treatment in 1979. Since then, individual cases and small series of *C. difficile*-negative *K. oxytoca*-positive AAHC have been reported in the literature. Most of these

reported cases have a history of treatment with  $\beta$ -lactam antibiotics [2,6,7,9,13].

Currently, allergic reactions, mucosal ischemia, and infection with *K. oxytoca* are the main suggested mechanisms for the development of AAHC [2,4,7,14]. It has been more than 2 decades since the first report on the role of *K. oxytoca* in AAHC was published; however, definitive proof was not provided until the fulfillment of Koch's postulates by Högenauer *et al.* [6]. Their findings suggested that cytotoxin-producing *K. oxytoca* is the causative organism in at least some cases of AAHC. A number of reports on the role of *K. oxytoca* in AAHC have been published recently [2,6,9,13], but none of these have investigated its long-term follow-up and relation to inflammatory bowel disease (IBD).

Our study investigated the role of *K. oxytoca* in a cohort of 21 patients with community-acquired antibiotic-associated bloody diarrhea (AABD) and their outcome with a long-term follow-up in regard to its relation with IBD.

## Materials and methods

### Patient series of acute hemorrhagic colitis

#### Description of terms

The term AABD has been used to indicate patients presenting with diarrhea and hematochezia following the use of oral antibiotics, whereas AAHC has been used to indicate patients with AABD whose stool culture revealed *K. oxytoca*. *C. difficile*-associated diarrhea has been used to indicate patients who tested positive for the production of the *C. difficile* toxin.

#### Patient selection

From January 2001 to November 2006, patients with AABD admitted to the Istanbul University, Cerrahpasa Medical Faculty, a 1500-bed tertiary care center, were questioned to determine whether they fulfilled the following criteria: (a) no previously diagnosed IBD and (b) history of use of antibiotics preceding bloody diarrhea. A total of 24 patients were recruited into our study.

#### Clinical data, colonoscopy, and microbiologic study

Clinical history and physical and endoscopic examination findings for each patient were documented on a standard form. Clinical data included age, sex, drug intake (aspirin, NSAID, oral contraceptive, etc.), the dose and duration of antibiotics used, evolution, and treatment of diarrhea. Laboratory, abdominal ultrasound and/or computed tomography, colonoscopic, and histopathologic findings (when the patient provided consent), the results of *C. difficile* toxin A + B, and growth for *K. oxytoca* in stool culture were recorded for each patient. Colitis was verified by endoscopy and histopathology when the patient provided consent.

Each patient was subjected to a colonoscopy and their stool was cultured for common enteric pathogens

[*Salmonella* spp., *Shigella* spp., *Campylobacter* spp., *Aeromonas* spp., *Yersinia* spp., and enterohemorrhagic *Escherichia coli* (EHEC)], examined for parasites (*Giardia lamblia* and *Entamoeba histolytica*), and tested for *C. difficile* toxin A + B using an enzyme-linked immunosorbent assay (R-Biopharm, Darmstadt, Germany). Stool specimens from patients were examined for *K. oxytoca* using MacConkey agar plates, and bacterial identification was performed using the API 20E test (bioMérieux, Marcy l'Etoile, France).

#### Long-term follow-up

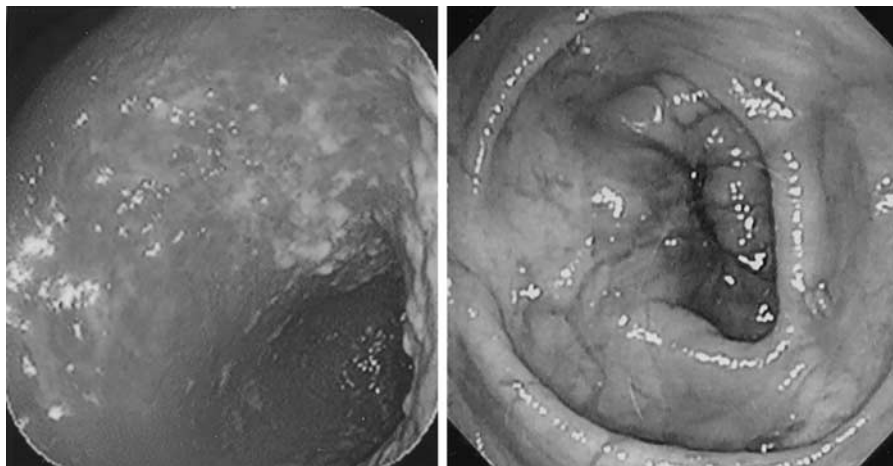
A telephonic interview was conducted with the patients in December 2010. The information obtained about their current health status, the use of any antibiotics, and recurrence of diarrhea/hemorrhagic colitis was documented on a standard form. Patients were invited to the hospital for an examination when necessary.

## Results

Three out of 24 patients with AABD were excluded from the study because of a lack of either stool cultures or follow-up information. Of the 21 patients with AABD who were evaluated, six underwent a colonoscopy with a biopsy within 24 h of admission, whereas the rest did not agree to the procedure mainly because of the sudden disappearance of their symptoms within hours. Colonoscopy revealed segmental hemorrhagic colitis with rectal sparing in all cases (Fig. 1, left). *K. oxytoca* growth was found in the fecal samples of three patients who underwent a colonoscopy. Colitis was predominantly localized in the ascending and the transverse colon. Colonoscopic findings of the six patients revealed erythema in all, superficial ulcerations in four, and pseudomembranes in one patient. The latter patient tested positive for both *C. difficile* toxin A + B and *K. oxytoca* in stool culture. Histology of biopsies taken from every patient undergoing a colonoscopy ( $n = 6$ ) revealed nonspecific acute colitis in every case. *K. oxytoca* was isolated from the stool in 11 (52%) and *C. difficile* toxin A + B was positive in six (29%) of the patients. No other enteric pathogens (*Salmonella* spp., *Shigella* spp., *Campylobacter* spp., *Aeromonas* spp., and EHEC) or parasites (*Giardia lamblia* and *Entamoeba histolytica*) were recovered from the stool samples.

The characteristics of the patients and the clinical and endoscopic features of colitis are shown in Table 1. All of the patients were outpatients at the onset of diarrhea. The stool was bloody at the onset of diarrhea in the majority of patients (76%), but turned bloody in the rest of the patients during the first 24 h of diarrhea. Although three patients recovered completely upon cessation of antibiotics, the rest were empirically treated with metronidazole before the diagnosis was established. The time period during which hemorrhagic colitis occurred following the intake of antibiotics varied as follows: 33% of the patients within the first 24 h, 52% of patients within the

Fig. 1



Colonoscopy of a patient with antibiotic-associated hemorrhagic colitis showing segmental hemorrhagic colitis of the ascending colon (left) and the same site following cessation of antibiotics (right).

**Table 1** Characteristics of the prospective cohort of 21 patients with acute antibiotic-associated bloody diarrhea

Mean age (years) (range)	34.1 (20–52)
Female sex (%)	12 (57)
Clinical setting	
Outpatients at the onset of diarrhea (%)	21 (100)
Bloody stool at onset (%)	16 (76.2)
Mean days from antibiotic intake to the onset of AAHC (range)	3.2 (0.25–14)
Mean total duration of bloody diarrhea-days (range)	3.9 (0.25–21)
History of use of the offending antibiotic previously (%)	1 (4.8)
Clinical features	
Bloody diarrhea (%)	21 (100)
Mucus in stools (%)	10 (47.6)
Fever (%)	7 (33.3)
Antibiotics received	
Ampicillin/sulbactam (%)	18 (85.7)
Amoxicillin/clavulanate (%)	2 (9.5)
Levofloxacin (%)	1 (4.8)
Microbiologic studies	
<i>Klebsiella oxytoca</i> (%)	11 (52.4)
<i>Clostridium difficile</i> toxin A + B (%)	6 (28.6)
<i>C. difficile</i> -negative <i>K. oxytoca</i> -positive (%)	5 (18.3)
<i>C. difficile</i> -positive <i>K. oxytoca</i> -positive (%)	6 (28.6)
Common enteric pathogens	0
Treatment	
Cessation of antibiotics only (%)	3 (14.3)
Cessation of antibiotics + metronidazole (%)	18 (85.7)
Outcome	
Recurrence of hemorrhagic colitis (%)	1 (4.8)

AAHC, antibiotic-associated hemorrhagic colitis.

first 48 h, and 90% of patients within the first 5 days. Only one patient developed symptoms 14 days after the intake of antibiotics. Five (24%) patients had *K. oxytoca*-positive *C. difficile*-negative AAHC, whereas all six patients who were *C. difficile* toxin A + B positive were also positive for *K. oxytoca*.

The characteristics of the 11 patients with AAHC are presented in Table 2. One of the patients (patient no. 4) was diagnosed with IBD during the follow-up period.

Interestingly, she had a history of AABD before recruitment into our study. Moreover, her stool tested positive for *C. difficile* toxin A + B and bloody diarrhea lasted less than 5 days in all the patients except her. She reported recurrent episodes of bloody diarrhea during the follow-up period and was subsequently diagnosed with ulcerative colitis. The patient was later cured with colectomy. Four of the patients were receiving NSAIDs at the time of the diagnosis of AAHC, and three of these patients were found to have both *C. difficile* toxin A + B and *K. oxytoca*.

The white blood cell count of the patients with AAHC ranged from 6.4 to  $29 \times 10^9/l$ , with a mean value of  $13 \times 10^9/l$ . Seventy-one percent of patients had white cell counts of more than  $10 \times 10^9/l$ . Serum C-reactive protein (CRP) levels ranged from 1 to 322 mg/l, with a mean value of 82 mg/l (0–5 mg/l) (Table 3). The CRP levels of the patients with both *C. difficile* toxin A + B and *K. oxytoca* were found to be significantly higher than those who had one or neither (149 vs. 55 mg/l,  $P = 0.002$ ). Other routine biochemical tests for the liver and kidney were within the normal range during admission.

## Discussion

Antibiotic-associated diarrhea can range from mild and self-limiting forms for most patients, who do not require treatment or alteration in the course of therapy, to colitis, a potentially life-threatening condition [15]. Although AAHC and *C. difficile*-associated diarrhea share some clinical symptoms, AAHC is a distinctly separate form of colitis. It is characterized by the absence of toxin-producing *C. difficile*, the lack of pseudomembranes on colonoscopy, and a sudden occurrence of bloody diarrhea during antibiotic treatment. *K. oxytoca* was recently found to be one of the causative agents of AAHC [2,6,9,16].

**Table 2** Characteristics of the 11 patients with antibiotic-associated hemorrhagic colitis who were positive for *Klebsiella oxytoca*

Patient number	Age	Sex	Antibiotic triggering AAHC	Indication for antibiotic therapy	Clostridium difficile toxin A + B	Additional therapy before the onset of AAHC	Time from start of antibiotics therapy to onset of AAHC (days)	Time to recovery	Therapy	Outcome of long-term follow-up (2–7 years)
1	27	F	Ampicillin-sulbactam	Sinusitis	Negative	None	3	3	Symptomatic <sup>a</sup>	No recurrence <sup>b</sup>
2	43	F	Ampicillin-sulbactam	Sinusitis	Positive	None	3	2	Metronidazole <sup>c</sup>	No recurrence
3	41	M	Ampicillin-sulbactam	Sinusitis	Positive	None	2	3	Metronidazole	No recurrence
4	31	F	Amoxicillin-clavulanate	Sinusitis	Positive	None	1	21	Metronidazole	Ulcerative colitis
5	49	M	Ampicillin-sulbactam	Tonsillitis	Positive	NSAID	1	2	Metronidazole	No recurrence
6	36	F	Ampicillin-sulbactam	Tonsillitis	Positive	NSAID	14	2	Metronidazole	No recurrence
7	28	F	Ampicillin-sulbactam	Tonsillitis	Positive	NSAID	1	2	Metronidazole	No recurrence
8	51	M	Ampicillin-sulbactam	Sinusitis	Negative	None	4	4	Metronidazole	No recurrence
9	22	M	Ampicillin-sulbactam	Sinusitis	Negative	NSAID	2	5	Metronidazole	No recurrence
10	25	M	Ampicillin-sulbactam	Sinusitis	Negative	None	3	3	Metronidazole	No recurrence
11	46	F	Ampicillin-sulbactam	Sinusitis	Negative	None	2	3	Metronidazole	No recurrence

AAHC, antibiotic-associated hemorrhagic colitis; F, female; M, male.

<sup>a</sup>Symptomatic treatment included cessation of antibiotics and administration of intravenous fluids.

<sup>b</sup>No recurrence indicates that the antibiotic responsible was not used and hemorrhagic colitis did not recur.

<sup>c</sup>Metronidazole treatments were given empirically.

**Table 3** White blood cell counts and C-reactive protein levels of 21 patients with acute antibiotic-associated bloody diarrhea

Patient number	<i>Clostridium difficile</i> toxin A + B	Stool culture	WBC (10 <sup>9</sup> /l)	CRP (0–5 mg/l)
1	Negative	<i>K. oxytoca</i>	12.7	75
2	Positive	<i>K. oxytoca</i>	14	80
3	Positive	<i>K. oxytoca</i>	13.5	82
4	Positive	<i>K. oxytoca</i>	12.4	322
5	Positive	<i>K. oxytoca</i>	12.6	210
6	Positive	<i>K. oxytoca</i>	7.6	100
7	Positive	<i>K. oxytoca</i>	16.4	101
8	Negative	<i>K. oxytoca</i>	17.2	90
9	Negative	<i>K. oxytoca</i>	9	70
10	Negative	<i>K. oxytoca</i>	11	18
11	Negative	<i>K. oxytoca</i>	12	60
12	Negative	No growth	9.5	1
13	Negative	No growth	7.1	8
14	Negative	No growth	9.8	20
15	Negative	No growth	13.6	48
16	Negative	No growth	10.8	100
17	Negative	No growth	13	80
18	Negative	No growth	6.4	20
19	Negative	No growth	21.1	90
20	Negative	No growth	15	70
21	Negative	No growth	29	77

CRP, C-reactive protein; *K. oxytoca*, *Klebsiella oxytoca*; WBC, white blood cells.

Spontaneous resolution usually occurs after cessation of the antibiotic [13]. Moreover, in experiments performed by two groups of researchers in Japan, some *K. oxytoca* strains isolated from patients with AAHC were shown to be capable of producing a cytotoxin that was toxigenic in cell cultures and inducing mucosal damage and epithelial cell death in isolated loops from rabbit ileum [17–19]. The ability of *K. oxytoca* to induce disease after antibiotic treatment most likely represents an overgrowth of the toxin-producing bacterium because of an alteration in the colonic microbiota [20].

The clinical features of AAHC in our patients were similar to those described previously [4,5,7]. We did not perform cytotoxicity assays with cell cultures for bacteria isolated from our patients. However, *K. oxytoca* was detected in large quantities in all the patients who had AAHC in our study, suggesting that the administration of

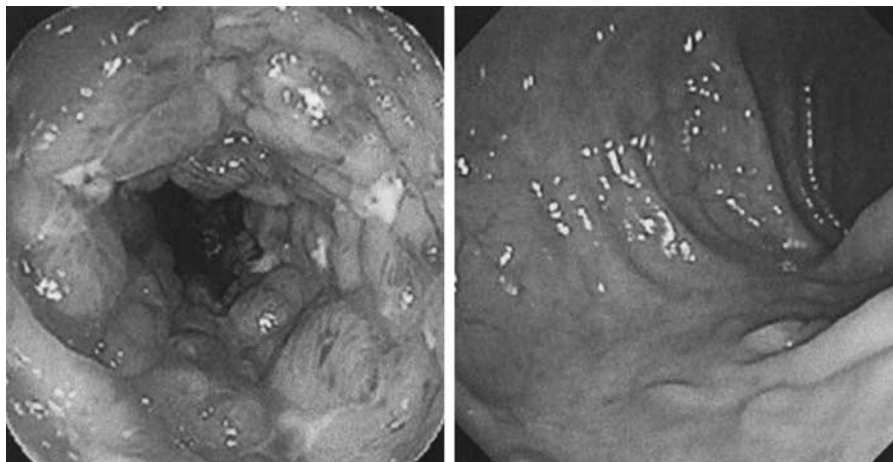
antibiotics alters the intestinal flora and promotes the growth of *K. oxytoca*. Large quantities of this microorganism apparently produce large amounts of cytotoxin, thus causing hemorrhagic colitis. It is currently not known whether patients who develop AAHC are colonized with *K. oxytoca* before or following antibiotic therapy. The prevalences of *K. oxytoca* among healthy individuals in Turkey and our patient group are 3 and 52%, respectively, which suggests a strong correlation between *K. oxytoca* and AABD ( $P < 0.05$ ,  $\chi^2$ ) [21]. Nevertheless, any presence of healthy carrier individuals may make one think whether *K. oxytoca* is a cause, consequence or innocent bystander in patients with AAHC.

Diarrhea in patients with AABD may be either bloody from the beginning or the appearance of blood may even take longer than 48 h [19]. Diarrhea was bloody at the onset in 16 (76%) of our patients and progressed to hematochezia in most of the patients in less than 24 h.

AAHC has been observed mainly in young and otherwise healthy outpatients after a brief treatment with penicillin derivatives. Either amoxicillin or amoxicillin/clavulanic acid seems to be responsible for the majority of AAHC cases in the literature [6,10,12,13,16,22–25]. Eighteen (86%) of 21 patients with AABD and 10 (91%) of 11 patients with AAHC had a history of oral ampicillin/sulbactam use in our study. Poor absorption of the drug may have caused an overgrowth of *K. oxytoca*, resulting in high cytotoxin concentrations that induce mucosal damage, which may have been responsible for the high rate of ampicillin/sulbactam causing AAHC in our patients [26,27].

There are increasing numbers of case reports and small case series in the literature suggesting *K. oxytoca* as the cause of AAHC; two case reports, in which *K. oxytoca* was the presumed cause of colitis in patients who had not received antibiotic therapy, are noteworthy [9,28]. They suggest that, under certain circumstances, *K. oxytoca* may be pathogenic even in the absence of antibiotics.

Fig. 2



Severe circumferential pancolitis of the patient with antibiotic-associated bloody diarrhea receiving NSAIDs (left) and control colonoscopy (right).

To our knowledge, the coexistence of *K. oxytoca* with *C. difficile* toxin A + B has not been noted previously in the literature. In our study, all the patients who tested positive for *C. difficile* toxin A + B also had positive stool cultures for *K. oxytoca*. This coexistence may be the result of common risk factors including exposure to antibiotics or some specific antibiotic (ampicillin/sulbactam)-related issues, but this requires further study.

The patients who tested positive for *C. difficile* toxin A + B were outpatients. A recent article by Kuntz *et al.* [29] reported that the epidemiology of *C. difficile* infection (CDI) is changing, with community-associated CDI occurring in populations not traditionally considered 'high risk' for the disease.

The level of CRP as a marker of inflammation in AAHC has not been studied in the literature. The CRP levels of the patients with the coexistence of *C. difficile* toxin A + B and *K. oxytoca* were significantly higher than those who had one or none (149 vs. 55 mg/l,  $P = 0.002$ ), which may imply that the presence of both *K. oxytoca* with *C. difficile* could cause a more severe inflammation of the colonic mucosa.

Histologic findings in patients with AAHC are similar to those in patients with other toxin-induced forms of colitis, such as colitis because of EHEC or *Shigella* spp., or in patients with ischemic colitis with abnormalities mainly in the right colon [14,30,31]. Colonoscopic findings were similar in our patients, affecting the right colon and some segments of the transverse colon without any suggestive evidence of specific macroscopic morphology.

We observed the use of NSAIDs in four (19%) of our patients with AABD, as have other investigators [6,7,14].

The use of NSAIDs has also been reported to be associated with colitis and diarrhea of various causes [32–36]. In their experiments in rats, Högenauer and colleagues showed that the concomitant administration of indomethacin and inoculation of *K. oxytoca* tended to cause more severe colitis and to induce erosion. Thus, NSAIDs appear to aggravate colitis caused by potentially pathogenic bacteria in the intestinal lumen [6]. One of the three patients with AABD, who was excluded from the study because of a lack of a stool culture, was regularly taking NSAIDs for osteoarticular disease. She had presented with diarrhea and melena. Her colonoscopy revealed severe circumferential pancolitis with ileitis (Fig. 2, left). Although the clinical picture resembled underlying severe IBD, the disappearance of symptoms and colonoscopic findings upon cessation of NSAID and antibiotics supported the role of the combination of both drugs in aggravation of colitis in patients with AABD (Fig. 2, right).

The toxicity of NSAIDs in the small bowel and the colon is considered to be related primarily to the direct mucosal effects of these drugs. Exposure of the small bowel mucosa to NSAIDs is believed to lead to the loss of intracellular integrity and an increase in permeability. This damage to the small intestinal barrier then allows further injury and subsequent inflammation because of intraluminal factors, such as bile and bacteria including toxigenic strains of *K. oxytoca* [37]. There is some evidence to support an association between NSAID use and flares in IBD [37], but little data that associate the use of antibiotics directly with flares.

Antibiotics may have a triggering effect on mucosal inflammation in patients with subclinical IBD. A significant link between the use of antibiotics and an exacerbation of symptoms may be through the development of CDI [38,39].

However, it is unclear whether these infections simply trigger symptoms in patients with IBD that resolve on resolution of the infection or whether they actually trigger a flare of intestinal inflammation that outlasts the infection [40]. The clinical and endoscopic profiles of both conditions might not be very different from each other. Only persistent disease or intermittent recurrence might be an indicator of IBD, as found in one of our patients.

AAHC is usually a self-limiting condition following the cessation of antibiotics. Metronidazole was given empirically to 10 of 11 patients with AAHC. As metronidazole is not effective against *K. oxytoca*, which suggests spontaneous remission of AAHC, only patients with *C. difficile* toxin A + B may have benefitted from empiric metronidazole.

This study confirms that AAHC, as a distinct entity in relation to *K. oxytoca*, is seen in half of the patients with AABD. However, whether any hitherto unrecognized organism other than *K. oxytoca* and *C. difficile* or a non-infectious etiology might have been responsible for the rest of the AABD cases is still a debate. Nearly all cases with AABD developed within a week following the use of antibiotics and remained flare free during the long-term antibiotic-free follow-up. The use of antibiotics may trigger a subclinical IBD in patients who initially present with AABD. In some of the patients with AAHC, *K. oxytoca* may coexist with *C. difficile* toxin A + B.

## Acknowledgements

Dr Mesut Yilmaz and Dr Yesim Aybar Bilir wrote the article, performed the microbiology laboratory work, and recruited some of the patients and collected data. Dr Gokhan Aygün recruited some of the patients and helped in the writing of the article. Dr Yusuf Erzin and Dr Aykut Ferhat Celik recruited some of the patients, performed colonoscopies, and followed the patients in the gastroenterology department, and finally Dr Aykut Ferhat Celik and Dr Recep Ozturk conceived and coordinated the study and edited the article.

## Conflicts of interest

There are no conflicts of interest.

## References

- Bartlett JG. Management of *Clostridium difficile* infection and other antibiotic-associated diarrhoeas. *Eur J Gastroenterol Hepatol* 1996; **8**:1054–1061.
- Beaugerie L, Metz M, Barbut F, Bellaiche G, Bouhnik Y, Raskine L, *et al.* *Klebsiella oxytoca* as an agent of antibiotic-associated hemorrhagic colitis. *Clin Gastroenterol Hepatol* 2003; **1**:370–376.
- Ayyagari A, Agarwal J, Garg A. Antibiotic associated diarrhoea: infectious causes. *Indian J Med Microbiol* 2003; **21**:6–11.
- Toffler RB, Pingoud EG, Burrell MI. Acute colitis related to penicillin and penicillin derivatives. *Lancet* 1978; **2**:707–709.
- Koga H, Aoyagi K, Yoshimura R, Kimura Y, Iida M, Fujishima M. Can quinolones cause hemorrhagic colitis of late onset? Report of three cases. *Dis Colon Rectum* 1999; **42**:1502–1504.
- Högenauer C, Langner C, Beubler E, Lippe IT, Schicho R, Gorkiewicz G, *et al.* *Klebsiella oxytoca* as a causative organism of antibiotic-associated hemorrhagic colitis. *N Engl J Med* 2006; **355**:2418–2426.
- Sakurai Y, Tsuchiya H, Ikegami F, Funatomi T, Takasu S, Uchikoshi T. Acute right-sided hemorrhagic colitis associated with oral administration of ampicillin. *Dig Dis Sci* 1979; **24**:910–915.
- Podschun R, Ullmann U. *Klebsiella* spp. as nosocomial pathogens: epidemiology, taxonomy, typing methods, and pathogenicity factors. *Clin Microbiol Rev* 1998; **11**:589–603.
- Chen J, Cachay ER, Hunt GC. *Klebsiella oxytoca*: a rare cause of severe infectious colitis: first North American case report. *Gastrointest Endosc* 2004; **60**:142–145.
- Kato S, Ebina K, Ozawa A, Naganuma H, Nakagawa H. Antibiotic-associated hemorrhagic colitis without *Clostridium difficile* toxin in children. *J Pediatr* 1995; **126**:1008–1010.
- Miller AM, Bassett ML, Dahlstrom JE, Doe WF. Antibiotic-associated hemorrhagic colitis. *J Gastroenterol Hepatol* 1998; **13**:1115–1118.
- Moulis H, Vender RJ. Antibiotic-associated hemorrhagic colitis. *J Clin Gastroenterol* 1994; **18**:227–231.
- Philbrick AM, Ernst ME. Amoxicillin-associated hemorrhagic colitis in the presence of *Klebsiella oxytoca*. *Pharmacotherapy* 2007; **27**:1603–1607.
- Yonei Y, Yoshizaki Y, Tsukada N, Inagaki Y, Miyamoto K, Suzuki O, *et al.* Microvascular disturbances in the colonic mucosa in antibiotic-associated hemorrhagic colitis: involvement of platelet aggregation. *J Gastroenterol Hepatol* 1996; **11**:681–685.
- Bartlett JG. Clinical practice. Antibiotic-associated diarrhea. *N Engl J Med* 2002; **346**:334–339.
- Zollner-Schwetz I, Hogenauer C, Joainig M, Weberhofer P, Gorkiewicz G, Valentin T, *et al.* Role of *Klebsiella oxytoca* in antibiotic-associated diarrhea. *Clin Infect Dis* 2008; **47**:e74–e78.
- Higaki M, Chida T, Takano H, Nakaya R. Cytotoxic component(s) of *Klebsiella oxytoca* on HEp-2 cells. *Microbiol Immunol* 1990; **34**:147–151.
- Minami J, Okabe A, Shiode J, Hayashi H. Production of a unique cytotoxin by *Klebsiella oxytoca*. *Microb Pathog* 1989; **7**:203–211.
- Minami J, Katayama S, Matsushita O, Sakamoto H, Okabe A. Enterotoxin activity of *Klebsiella oxytoca* cytotoxin in rabbit intestinal loops. *Infect Immun* 1994; **62**:172–177.
- Joainig MM, Gorkiewicz G, Leitner E, Weberhofer P, Zollner-Schwetz I, Lippe I, *et al.* Cytotoxic effects of *Klebsiella oxytoca* strains isolated from patients with antibiotic-associated hemorrhagic colitis or other diseases caused by infections and from healthy subjects. *J Clin Microbiol* 2010; **48**:817–824.
- Bayramoglu G, Esen S, Belet N, Hokelek M, Karadag A, Gunaydin M. Investigation of colonization with resistant bacteria and parasites among newborn unit staff. *Ankem Derg* 2002; **16**:44–47.
- Flueckiger T, Froehli P, Baltisser I. Antibiotic-associated segmental hemorrhagic colitis: a case report. *Z Gastroenterol* 1992; **30**:262–263.
- Benoit R, Dorval D, Loulergue J, Bacq Y, Oliver JM, Audurier A, *et al.* Post-antibiotic diarrheas: role of *Klebsiella oxytoca*. *Gastroenterol Clin Biol* 1992; **16**:860–864.
- Mrowka C, Munch R, Rezzonico M, Greminger P. Acute segmental hemorrhagic penicillin-associated colitis. *Dtsch Med Wochenschr* 1990; **115**:1750–1753.
- Heer M, Sulser H, Hany A. Segmental hemorrhagic colitis following amoxicillin therapy. *Schweiz Med Wochenschr* 1989; **119**:733–735.
- Wildfeuer A, Zimmermann T, Eibel G, Lach P, Yeates R, Pfaff G. Relative bio-availability of sulfamonomethoxime in healthy volunteers following administration of two tablet formulations. *J Int Med Res* 1992; **20** (Suppl 1):4A–11A.
- Willing BP, Russell SL, Finlay BB. Shifting the balance: antibiotic effects on host-microbiota mutualism. *Nat Rev Microbiol* 2011; **9**:233–243.
- Soussi F, Tchirikhtchian K, Ramaholimihaso F, Yaziji N, Coussinet S, Diebold MD, *et al.* Diclofenac-induced colitis complicated by *Klebsiella oxytoca* infection. *Gastroenterol Clin Biol* 2001; **25**:814–816.
- Kuntz JL, Chrischilles EA, Pendergast JF, Herwaldt LA, Polgreen PM. Incidence of and risk factors for community-associated *Clostridium difficile* infection: a nested case-control study. *BMC Infect Dis* 2011; **11**:194.
- Griffin PM, Olmstead LC, Petras RE. *Escherichia coli* O157:H7-associated colitis. A clinical and histological study of 11 cases. *Gastroenterology* 1990; **99**:142–149.
- O'Loughlin EV, Robins-Browne RM. Effect of Shiga toxin and Shiga-like toxins on eukaryotic cells. *Microbes Infect* 2001; **3**:493–507.
- Etienny I, Beaugerie L, Viboud C, Flahault A. Non-steroidal anti-inflammatory drugs as a risk factor for acute diarrhoea: a case crossover study. *Gut* 2003; **52**:260–263.
- Gleeson MH, Davis AJ. Non-steroidal anti-inflammatory drugs, aspirin and newly diagnosed colitis: a case-control study. *Aliment Pharmacol Ther* 2003; **17**:817–825.
- Graham DY, Opekun AR, Willingham FF, Qureshi WA. Visible small-intestinal mucosal injury in chronic NSAID users. *Clin Gastroenterol Hepatol* 2005; **3**:55–59.

- 35 Kurahara K, Matsumoto T, Iida M, Honda K, Yao T, Fujishima M. Clinical and endoscopic features of nonsteroidal anti-inflammatory drug-induced colonic ulcerations. *Am J Gastroenterol* 2001; **96**:473–480.
- 36 Matsumoto T, Kudo T, Esaki M, Yano T, Yamamoto H, Sakamoto C, *et al.* Prevalence of non-steroidal anti-inflammatory drug-induced enteropathy determined by double-balloon endoscopy: a Japanese multicenter study. *Scand J Gastroenterol* 2008; **43**:490–496.
- 37 Feagins LA, Cryer BL. Do non-steroidal anti-inflammatory drugs cause exacerbations of inflammatory bowel disease? *Dig Dis Sci* 2010; **55**:226–232.
- 38 Clayton EM, Rea MC, Shanahan F, Quigley EM, Kiely B, Hill C, *et al.* The vexed relationship between *Clostridium difficile* and inflammatory bowel disease: an assessment of carriage in an outpatient setting among patients in remission. *Am J Gastroenterol* 2009; **104**:1162–1169.
- 39 Ananthakrishnan AN, Issa M, Binion DG. *Clostridium difficile* and inflammatory bowel disease. *Gastroenterol Clin North Am* 2009; **38**:711–728.
- 40 Singh S, Graff LA, Bernstein CN. Do NSAIDs, antibiotics, infections, or stress trigger flares in IBD? *Am J Gastroenterol* 2009; **104**:1298–1313, quiz 314.