

## Successful Cryoablation of Atrioventricular Nodal Reentrant Tachycardia and Coexisting Accessory Pathways without Fluoroscopy

Enes Elvin Gul, MD, Fatma Seyma Ugur, PhD, Celal Akdeniz, MD, and Volkan Tuzcu, MD

Department of Pediatric Cardiology/Electrophysiology, Medipol University, Istanbul, Turkey

### ABSTRACT

We report the case of a 14-year-old boy patient admitted to our outpatient clinic with palpitations and documented supraventricular tachycardia. Electrophysiological study and ablation were planned. In the electrophysiological study, two tachycardias with different cycle lengths and morphologies were induced. After elimination of the slow pathway, left posterior accessory pathway was detected and successfully ablated. Another pathway was detected following that ablation. Due to the slow retrograde conduction of this pathway, diltiazem infusion was started to uncover the accessory pathway. The second accessory pathway was at the left posteroseptal region and was successfully ablated. After a 30-minute waiting period, no tachycardia was induced. In addition, no fluoroscopy was used during the procedure.

**Key Words.** AVNRT; Accessory Pathway; Cryoablation; Fluoroscopy

### Introduction

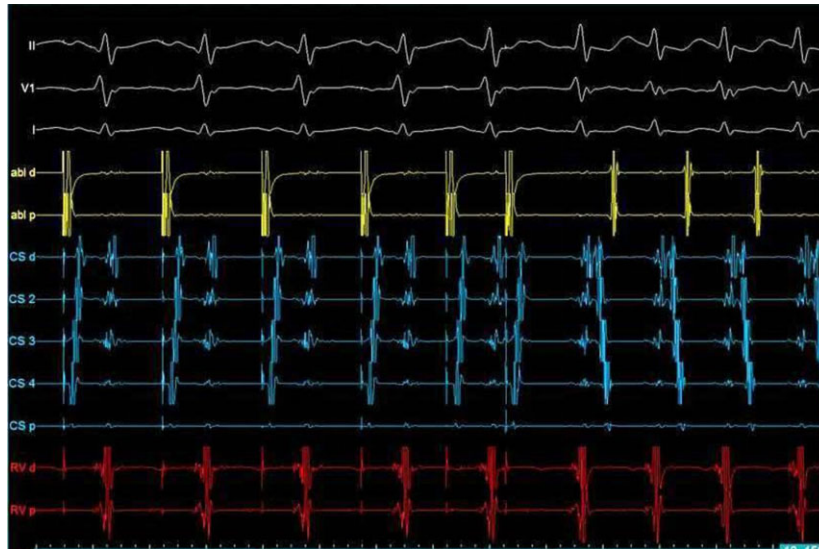The prevalence of coexistent atrioventricular reentrant tachycardia (AVNRT) and AVRT has been rarely reported in the literature. The bypass tract is usually first targeted for ablation because of the concept that dual atrioventricular (AV) nodal physiology is more physiological for the heart than accessory pathway (AP). In this article, we briefly discuss that multiple supraventricular arrhythmia substrates can be successfully eliminated without fluoroscopy with the aid of electroanatomical systems.

### Case Presentation

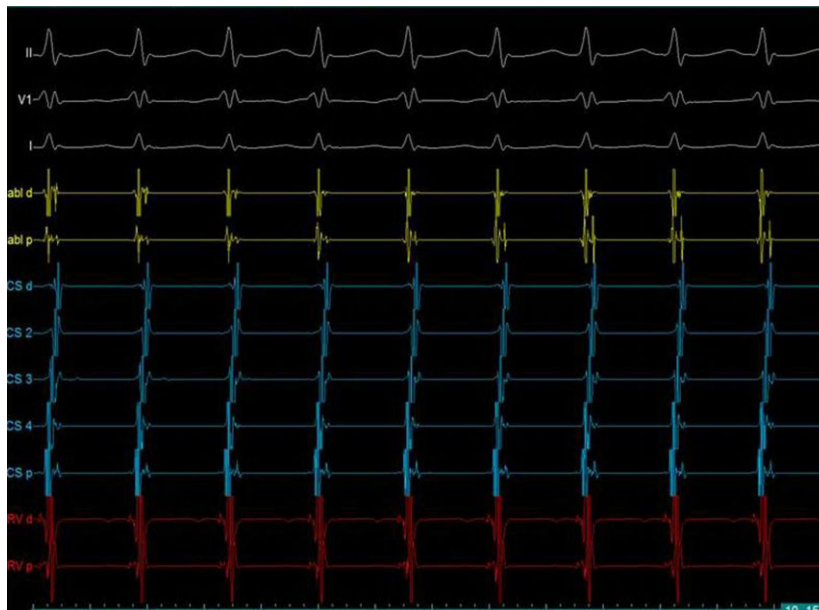
A 14-year-old boy presented with recurrent palpitations, despite the treatment with metoprolol. Twelve-lead resting electrocardiography (Mortara Instrument, Inc., Milwaukee, WI, USA) showed normal sinus rhythm without preexcitation. An event recorder revealed supraventricular tachycardia with a rate of 167 bpm. There was no family history of syncope, sudden death, or arrhythmias. Admission physical examination was unremarkable. Echocardiography (Vivid S6, GE Healthcare, Wauwatosa, WI, USA) revealed a structurally normal heart. Electrophysiology study and abla-

tion were recommended due to recurrent tachycardia under medical treatment.

An electrophysiological study was performed under general anesthesia without intubation. Quadripolar catheters were positioned at the high atrium, His-bundle area, and right ventricular apex. A steerable decapolar catheter was inserted into the coronary sinus for a positional reference. The EnSite NavX system (St. Jude Medical, St. Paul, MN, USA) was used for three-dimensional mapping and catheter navigation. Right atrial anatomy was reconstructed without fluoroscopy. Baseline electrophysiologic (EP) measurements were obtained. During incremental ventricular pacing, ventriculoatrial conduction was eccentric, and block was at 420 ms. After intravenous orciprenaline injection, tachycardia with a 375-ms cycle length was induced. During the tachycardia, the earliest ventriculoatrial conduction was from the left posterior wall (Figure 1). Another form of tachycardia with a different cycle length (305 ms) consistent with AVNRT was induced (Figure 2). A 6-mm tip cryoablation catheter (Freezor, Medtronic Inc., MN, USA) was inserted via the right femoral vein. Cryoablation of the slow pathway was initiated, and the tachycardia was terminated at 12 seconds of the ablation. Six lesions,



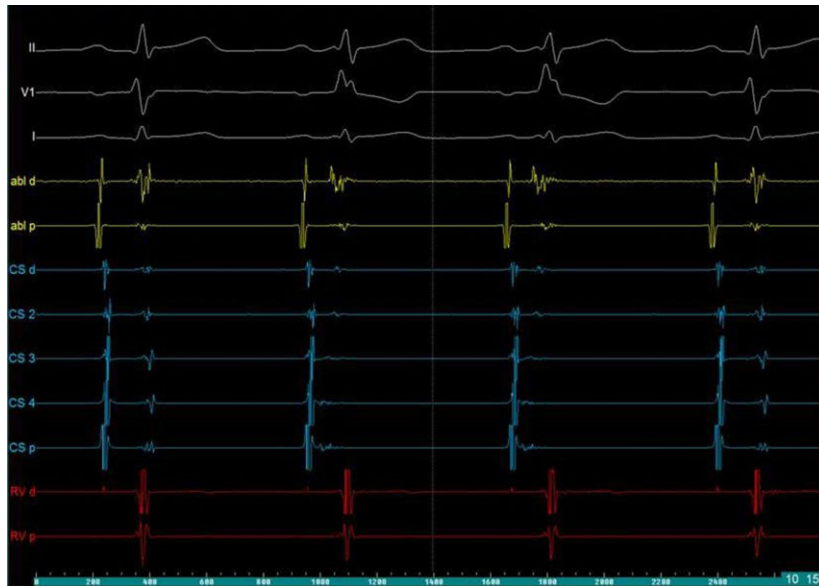
**Figure 1.** S1 and S2 stimulations from coronary sinus before ablation. VA conduction after pacing is eccentric: the earliest atrial activation is at distal coronary sinus suggesting left posterior AP. VA, ventriculoatrial; AP, accessory pathway.



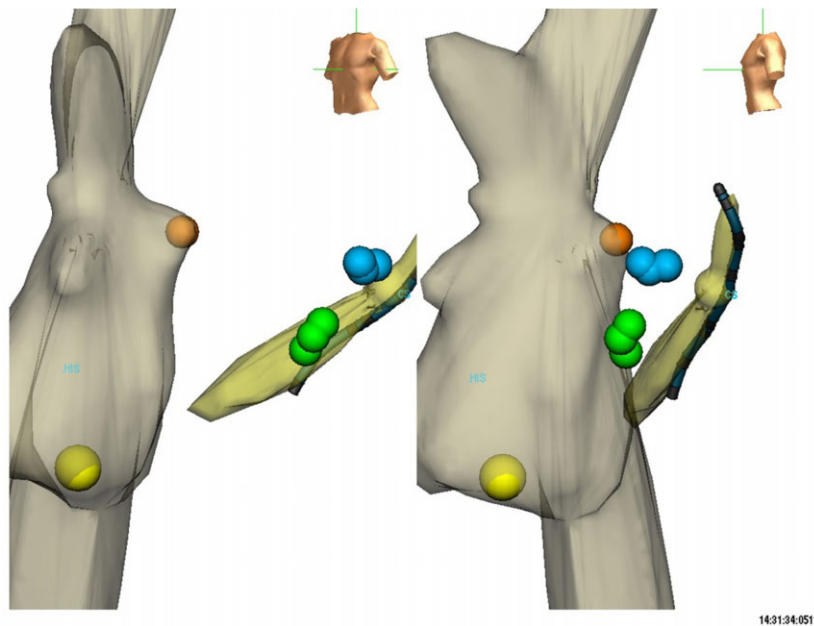
**Figure 2.** Electrophysiological study showing typical atrioventricular nodal reentrant tachycardia.

240 seconds each, were placed in the slow pathway region. To eliminate the left posterior pathway, a cryocatheter was inserted into the left side via patent foramen ovale. The left concealed accessory pathway was eliminated with cryoablation. In addition, Kent spikes were demonstrated during the cryoablation of the left posterior AP. Afterward, during the incremental ventricular pacing, the ventriculoatrial (VA) conduction was still eccentric with indication of a second left-sided pathway. The retrograde conduction was slow, and

AV nodal conduction was prominent. Therefore, intravenous diltiazem (15 mg) was started to uncover the second AP. After diltiazem, the second AP in the left posteroseptal location started to demonstrate intermittent preexcitation (Figure 3). Successful cryoablation with four lesions, each 240 seconds, were placed for the left posteroseptal AP (Figure 4). After a 30-minute waiting period, there was no inducible tachycardia with or without orciprenaline. In addition, during the AV block obtained after adenosine injection, no preexcita-



**Figure 3.** Manifest preexcitation is shown: the earliest atrial activity at CS 4, i.e., at the left posteroseptal region. CS, coronary sinus.



**Figure 4.** Three-dimensional anatomic mapping showing successful cryoablation sites of AVNRT (yellow lesion) and both APs: left posterior (blue lesions) and left posteroseptal (green lesions). Note that patent foramen ovale (PFO) was crossed. AVNRT, atrioventricular nodal reentrant tachycardia; AP, accessory pathway.

tion was manifested. The total procedure time was 330 minutes, and no fluoroscopy was used. No complications occurred.

### Discussion

The prevalence of coexistent AVNRT and AVRT has been reported in about 3–4% out of all

patients with supraventricular reentrant tachycardias.<sup>1,2</sup> The bypass tract is usually first targeted for ablation because of the concept that dual AV nodal physiology is more physiological for the heart than AP. The AV node slow pathway is ablated only when tachycardia is induced during the electrophysiological study. There are some reports that two different tachycardias were treated by the

ablation of the slow pathway alone when the APs are in high-risk regions (septal area) for complications.<sup>3,4</sup> The success of the abovementioned reports was due to the fact that the anterograde limb of the AP was the slow AV nodal pathway. However, in our case, we induced supraventricular tachycardia utilizing the left posterior AP following successful AVNRT ablation. In addition, a second AP with intermittent antegrade conduction was shown in the left posteroseptal area.

To minimize the risk of heart block, cryothermia mapping has been recently used.<sup>5</sup> Cryoablation is a safer option for ablation in close proximity to the AV node.<sup>6</sup> To the best of our knowledge, this is the first case where successful cryoablation of the AV node slow pathway and coexisting APs (left posterior and left posteroseptal) were performed under the guidance of a nonfluoroscopic, three-dimensional mapping system. Superiorities of cryoablation are as follows: (1) safety, (2) low risk of heart block, (3) better catheter stabilization, and (4) less thrombogenicity. Cryoablation is a newer method of ablation, which has proven to be safe in many studies.<sup>7,8</sup> An acute success rate of cryoablation is 95% for AVNRT.<sup>9</sup> Conventional method for left-sided AP ablation is radio frequency (RF) ablation. However, a recent study demonstrated significantly improved acute and long-term success rates for the left-sided APs using cryoablation when compared with RF ablation.<sup>8</sup>

Nonfluoroscopic method is a superiority of this case because radiation exposure during radiofrequency ablation carries known associated risks.<sup>10</sup> Three-dimensional anatomic mapping with the EnSite system mainly eliminates fluoroscopy use in majority of the procedures.<sup>11,12</sup> Some recent studies have demonstrated that children are especially vulnerable for cancer with increasing number of diagnostic and therapeutic radiation exposures and this risk appears to persist throughout life.<sup>13</sup> Very low doses of radiation may be more harmful than previously suspected and that the relationship may not, in fact, be linear in the pediatric population.<sup>14</sup> There are reasonable benefits to both patients and staff (especially pregnant women) in eliminating radiation exposure. Orthopedic complications related to lead aprons are relatively common.<sup>15</sup> In addition, left brain malignancies were reported among interventional cardiologists.<sup>16</sup>

In conclusion, this case demonstrates that multiple supraventricular arrhythmia substrates can be successfully eliminated without fluoroscopy with the aid of electroanatomical systems.

#### Author Contributions

Enes Elvin Gul: manuscript writing and literature search.

Fatima S. Ugur: language editing.

Celal Akdeniz: performed ablation.

Volkan Tuzcu: performed ablation, manuscript writing, editing, and supervision.

**Corresponding author:** Volkan Tuzcu, MD, Department of Pediatric Cardiology/Electrophysiology, Istanbul Medipol University, Istanbul 34093, Turkey. Tel: (+0090) 212-460-7782; Fax: (+90) (212) 460 70 70; E-mail: vtuzcu@gmail.com

*Conflict of interest and disclosure of funding:* The manuscript, as submitted or its essence in another version, is not under consideration for publication elsewhere and will not be published elsewhere while under consideration by *Congenital Heart Disease* journal. The authors have no commercial associations or sources of support that might pose a conflict of interest. All authors have made substantive contributions to the study, and all authors endorse the data and conclusions.

*Accepted in final form: November 13, 2012.*

#### References

- 1 Kuo JY, Tai CT, Chiang CE, et al. Mechanisms of transition between double paroxysmal supraventricular tachycardias. *J Cardiovasc Electrophysiol.* 2001;12:1339–1345.
- 2 Pritchett EL, Prystowsky EN, Benditt DG, Gallagher JJ. “Dual atrioventricular nodal pathways” in patients with Wolff-Parkinson-White syndrome. *Br Heart J.* 1980;43:7–13.
- 3 Padanilam BJ, Akula D, Vaughn P, Prystowsky EN. Successful elimination of concealed accessory pathway-mediated tachycardia by ablation of AV nodal slow pathway. *J Cardiovasc Electrophysiol.* 2006; 17:674–677.
- 4 Di Biase L, Bai R, Tritto M, Grimaldi M, Biasco MG. Ablation of atrioventricular nodal “slow pathway” for simultaneous treatment of coexisting atrioventricular and nodal reciprocating tachycardias. *J Interv Card Electrophysiol.* 2007;19:143–147.
- 5 Lanzotti ME, De Ponti R, Tritto M, Spadacini G, Salerno-Uriarte JA. Successful treatment of anteroseptal accessory pathways by transvenous cryomapping and cryoablation. *Ital Heart J.* 2002; 3:128–132.
- 6 Tuzcu V. Cryoablation of accessory pathways in children. *Pacing Clin Electrophysiol.* 2007;30:1129–1135.
- 7 Drago F, De Santis A, Grutter G, Silvetti MS. Transvenous cryothermal catheter ablation of re-entry

- circuit located near the atrioventricular junction in pediatric patients: efficacy, safety, and midterm follow-up. *J Am Coll Cardiol*. 2005;45:1096–1103.
- 8 Tuzcu V. Significant reduction of fluoroscopy in pediatric catheter ablation procedures: long-term experience from a single center. *Pacing Clin Electrophysiol*. 2012;35:1067–1073.
  - 9 de Sisti A, Tonet J. Cryoablation of atrioventricular nodal reentrant tachycardia: a clinical review. *Pacing Clin Electrophysiol*. 2012;35:233–240.
  - 10 Lindsay BD, Eichling JO, Ambos HD, Cain ME. Radiation exposure to patients and medical personnel during radiofrequency catheter ablation for supraventricular tachycardia. *Am J Cardiol*. 1992;70:218–223.
  - 11 Smith G, Clark JM. Elimination of fluoroscopy use in a pediatric electrophysiology laboratory utilizing three-dimensional mapping. *Pacing Clin Electrophysiol*. 2007;30:510–518.
  - 12 Tuzcu V. A nonfluoroscopic approach for electrophysiology and catheter ablation procedures using a three-dimensional navigation system. *Pacing Clin Electrophysiol*. 2007;30:519–525.
  - 13 Kleinerman RA. Cancer risks following diagnostic and therapeutic radiation exposure in children. *Pediatr Radiol*. 2006;36(suppl 2):121–125.
  - 14 Beels L, Bacher K, De Wolf D, Werbrouck J, Thierens H. gamma-H2AX foci as a biomarker for patient X-ray exposure in pediatric cardiac catheterization: are we underestimating radiation risks? *Circulation*. 2009;120:1903–1909.
  - 15 Goldstein JA, Balter S, Cowley M, Hodgson J, Klein LW. Occupational hazards of interventional cardiologists: prevalence of orthopedic health problems in contemporary practice. *Catheter Cardiovasc Interv*. 2004;63:407–411.
  - 16 Roguin A, Goldstein J, Bar O. Brain tumours among interventional cardiologists: a cause for alarm? Report of four new cases from two cities and a review of the literature. *EuroIntervention*. 2012;7:1081–1086.