



Effect of anti-inflammatory treatment on Sever's disease management

Anti-inflammatory treatment of Sever's disease

Şafak Sayar¹, Hasan Hüseyin Ceylan², Barış Çaypınar³

¹Ortopedi ve Travmatoloji Bölümü, Op. Dr. Medipol Üniversitesi Esenler Uygulama ve Araştırma Hastanesi,

²Ortopedi ve Travmatoloji Kliniği, Op. Dr. Lütfiye Nuri Burat Devlet Hastanesi,

³Fizyoterapi ve Rehabilitasyon Bölümü, Yrd. Doç. Dr. Gelişim Üniversitesi, Sağlık Meslek Yüksekokulu, İstanbul, Türkiye

Abstract

Aim: Sever's disease is a calcaneal apophysitis condition and common childhood problem. Despite various treatment methods, there is not a gold standard treatment. In this study, we aimed to report the efficacy of anti-inflammatory treatment on Sever's disease during a four-year period. **Material and Method:** The study includes the pediatric patients, between 6-17 years old, who presented to the outpatient clinic with heel pain and had a Sever's disease diagnosis between 2014 and 2017. Demographics and treatment records of patients were reviewed. **Results:** Of the 74 children who had a diagnosis of Sever's disease, 59 were boys. Mean age was 10.77 (6.87-15.73) years at the time of diagnosis. Mean age was 11.14 (8.04-15.73) and 9.28 (6.87-13.20) years for boys and girls, respectively. Complaints were bilateral in 46 (62.16%) of 74 children. Mean symptomatic period between pain and diagnosis was 12.7 (range 2-108) weeks. Except for one patient, all of the 69 (93.2%) patients' pain was resolved. Two weeks of ibuprofen usage was found to be sufficient for Sever's disease treatment in 68 (91.89%) of our overall patient cohort. **Discussion:** Non-steroidal anti-inflammatory medication seems to be sufficient to treat most Sever's disease patients. Simple anti-inflammatory treatment is enough for most primary cases; there is no evidence of the positive effect of expensive heel insoles or orthoses.

Keywords

Sever's Disease; Calcaneal Apophysitis; Heel Pain; Ibuprofen

DOI: 10.4328/JCAM.5839 Received: 26.03.2018 Accepted: 08.05.2018 Published Online: 14.05.2018 Printed: 01.01.2019 J Clin Anal Med 2019;10(1): 54-7
Corresponding Author: Şafak Sayar, Medipol Üniversitesi Esenler Hastanesi, Birlik Mah. Bahçeler Cad. No:5 34230, Esenler, İstanbul, Türkiye.
Tel: +90 2124401000 GSM: +905306966045 E-Mail: safaksayar@gmail.com
ORCID ID: 0000-0003-1293-4436

Introduction

Calcaneus apophysitis (called Sever's disease) is a clinical entity that is common in pediatric patients with heel pain [1]. First described by James Warren Sever in 1912 [2] and typically characterized by pain that can be localized by palpation on the calcaneus postero-inferior, it is clinically aggravated by excessive physical activities such as football [3]. Symptoms are usually associated with activity, but resting pain can also be observed in chronic cases. Because the disease is often benign, it rarely requires an extended casting duration or causes the active athlete to withdraw from sporting activities [4, 5]. Scharfbillig and colleagues reported negative effects of calcaneal apophysitis on quality of life [6].

Even in persistent cases, it is rarely necessary to fix with resting plaster. In addition to clinical diagnosis, X-ray graphics confirm the diagnosis, but magnetic resonance imaging is recommended to exclude fracture, tumor, or infection [7, 8]. Sever's disease is seen in girls 8 to 13 years. In boys it is frequently seen in the age range of 11 to 15 years [4]. The frequency of the disease has been reported between 2% and 16% in all musculoskeletal injuries [1]. Sever's disease's incidence is thought to be higher in the active pediatric population [4]. Treatment is conservative. In addition to anti-inflammatory drugs, resting, stretching, strengthening of the calf muscles, heel lifting supports, and personalized orthosis are recommended for treatment [1, 4, 5, 9]. In this study, anti-inflammatory treatment results were discussed for children who applied with heel pain and were diagnosed with Sever's disease.

Material and Method

The patients between 6 and 17 years old were retrospectively researched between 1.1.2014 and 15.12.2017. We searched for the terms "heel", "calc", and "Sever" in the database. All available data was recorded in a table and details were confirmed. Patients with an anamnesis and diagnosis record other than Sever's were excluded. Patients with a suspicious diagnosis and missing anamnesis files were eliminated.

Seventy-four patients who were admitted with a bilateral heel pain complaint and who had no history of acute trauma over a four-year period were identified. Pediatric patients who admitted with a heel pain complaint and diagnosed with Sever's disease were included in this study. The patients' age, gender, side, admission period, and symptom duration records were noted. The treatment efficacy was questioned by examining all patients who were diagnosed with Sever's disease and treated with ibuprofen. The results were compared statistically (SPSS Statistics for Windows, Version 20.0, IBM Corp., Armonk, NY, USA).

Results

There were 31 patients in 2014, 19 in 2015, 11 in 2016, and 21 in 2017 who were diagnosed with Sever's disease (Figure 1). Of 74 patients who were diagnosed with Sever's disease, 59 were boys and 15 were girls. The mean age of the patients was 10.77 (6.87-15.73) years. The mean age of boys was 11.14 (8.04-15.73) year, while that of girls was 9.28 (6.87-13.20) years. It was found that the disease was seen in girls relatively younger than boys ($p = 0.00116$). Symptoms were bilateral

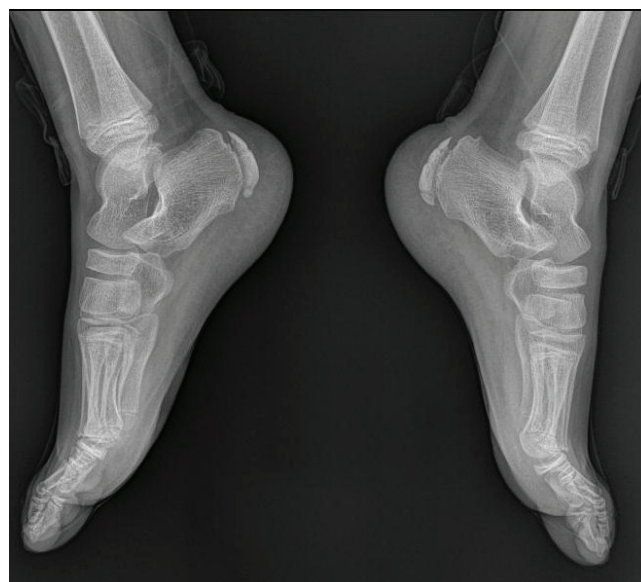

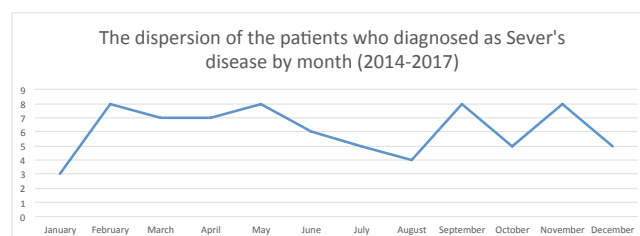
Figure 1. Lateral calcaneus X-ray graphy of a 10-year-old boy with bilateral heel pain.

in 46 (62.16%) of 74 patients, while the rest had pain in one heel. There was no significant difference between the groups in terms of the distribution of the sides ($p = 0.68705$). The average time between the onset of complaints and referral to clinic was 12.7 weeks (range 2-108). The patient with the longest complaint was an 11-year-old girl at the time of admission.

All patients were treated with an ibuprofen suspension or tablet according to their weight. Total dose was divided into two and treated with a half-dose every 12 hours. Additionally, stretching exercises were described and recommended. All patients were called in during the second week. At the end of two weeks, this treatment was found to be ineffective for only one of the 69 patients. Magnetic Resonance (MR) examination was performed for the differential diagnosis of a nine-year-old male patient who did not benefit from anti-inflammatory therapy. There was only a calcaneal apophyseal edema shown in MR imaging. The patient was treated with a short-leg plaster without mobilization for four weeks. Because of continuing complaints after plaster removal, the patient underwent passive stretching exercises for two weeks under physiotherapist control. Although the patient experienced pain during the eighth week after treatment, it was seen to be relatively less severe than the first application.

The disease was often associated with bilateral involvement and seen more often in boys. There was no significant difference between the seasons in terms of periodical submissions ($p=0.246$) (Table 1). As a result of this study, it was determined that two weeks of ibuprofen treatment in Sever's disease was sufficient in 68 (91.89%) of 74 patients.

Table 1. Patients who are diagnosed with Sever's disease often appear to have been hospitalized in the spring.



Discussion

In this study, it was confirmed that anti-inflammatory treatment alone was effective despite the range of treatment options for Sever's disease. There is little information in the literature on the efficacy of non-steroid anti-inflammatory therapy in the treatment of Sever's disease. Karahan and colleagues, in addition to heel support and stretching exercises, treated their patients with 3x400 mg ibuprofen and topical diclofenac for three weeks and reported good results [10]. Oral non-steroid anti-inflammatory therapy and short-leg casting can be used for two to four weeks [3, 7]. We have seen that ibuprofen treatment at an appropriate dose based on weight is an effective agent against Sever's disease.

Although it is the general principle to use conservative methods as a basis for the treatment of Sever's disease, there is not much evidence showing which conservative treatment is more effective [1]. Some recent publications advise using heel supports and restricting sporting activities [1, 5, 9]. Ice, stretching, resting, and activity restraint are the most important treatment methods in many studies [11, 12]. James et al. showed that heel lifting supports, taping methods, and orthoses have no significant contribution to the healing of calcaneal apophysitis-induced heel pain [12]. In published studies that suggest heel lifters are useful, simultaneous ice and stretching treatment had also been applied so the isolated effect of heel supports was not clarified [12]. There are no studies on Sever's disease treatment evaluating the efficacy of pre-marketed heel supports used in the treatment of plantar fasciitis [12]. In our patient group, we did not recommend heel support or orthosis. Only in one resistant case, we recommended an orthosis for four weeks with non-weight mobilization.

In the early 20th-century, childhood heel pain, which was defined radiologically and clinically by Sever, was reported in the literature as Sever's disease [2]. Sever's first definition of the disease was reported to be seen in overactive and overweight children [2]. The radiological findings of the disease were also emphasized in this first study. Lewin claimed that epiphyseal painful inflammation was caused by opposed traction by Achilles and plantar fascias [13]. Apophyseal traction, which occurs in the Achilles tendon insertion in adolescents at the time of rapid growth, may explain the mechanism of pain [14, 15]. This calcaneal apophysitis situation is a benign, self-limiting disease [16]. Finally, fusion of the apophysis with calcaneus terminates the disease [2]. Inflammation process rarely results in apophyseal fracture [17]. Apophyseal fracture was not found in our patient groups.

Sever's disease is seen between 8 and 15 years of age [12]. A case with a six-year-old was reported in the literature [18]. In males, it is two or three times more common than in females and symptoms are bilateral in 60% of cases [4]. There was no study on the incidence and prevalence of the disease in the general population until 2013 [12]. Sports traumatology clinics reported 2-16% incidence of disease, but this was considered insufficient to reflect the overall incidence rate [12, 13]. In another study in the Netherlands, Sever's disease incidence was reported as 3.7 / 1000 [19]. There is no study of incidence in our country.

Although high calcaneal apophyseal densities and fragmentation are observed in lateral calcaneal X-ray graphics, this image is not pathognomonic for the disease and may be seen in healthy children [11, 20]. Diagnosis can be made clinically using a history of the patient and X-ray graphy can be used to exclude potential pathologies [7]. Stress fracture, osteomyelitis, Achilles tendinitis, and calcaneus cysts should be considered in the differential diagnosis [7]. MR examination can be performed for this purpose. Bone marrow edema and increased involvement after gadolinium administration can be observed in MR imaging [7]. In our patient group, it was seen that there was no need for further examination except for the one patient who had MR imaging due to persistent pain. A calcaneus lateral X-ray graphy was taken in all patients for confirmation in addition to clinical diagnosis.

In summary, as awareness of calcaneal apophysitis increases, more studies on diagnosis and treatment will be published. Although it is relatively common, it does not have a worse clinical course, and usually it is spontaneously healed, which may be another reason why doctors are not too interested in this topic. However, increased awareness of clinical diagnosis is important to reduce unnecessary radiological examination and orthopedic outpatient admission rates. There is no up-to-date literature data supporting the prescribing of devices such as insoles and orthoses that add cost to both the patient and the healthcare system, rather than the improvement that can be achieved with simple anti-inflammatory therapy.

Our study has certain limitations. In this retrospective study, some patients may not be included because of failure to access their information and inadequate anamnesis forms of probable diagnosed patients. There may be patients who did not come to the control visit at the hospital despite the fact that there was no diminution in complaints and easy hospital transportation. Some patients may have received additional treatment by referral to other centers. This obstacle can be overcome with a prospective study where the data record is complete. In addition, prospective comparative studies with different drugs can be made in more patient series.

Scientific Responsibility Statement

The authors declare that they are responsible for the article's scientific content including study design, data collection, analysis and interpretation, writing, some of the main line, or all of the preparation and scientific review of the contents and approval of the final version of the article.

Animal and human rights statement

All procedures performed in this study were in accordance with the ethical standards of the institutional and/or national research committee and with the 1964 Helsinki declaration and its later amendments or comparable ethical standards. No animal or human studies were carried out by the authors for this article.

Funding: None

Conflict of interest

None of the authors received any type of financial support that could be considered potential conflict of interest regarding the manuscript or its submission.

References

1. Scharfbillig RW, Jones S, Scutter SD. Sever's disease: what does the literature really tell us? *Journal of the American Podiatric Medical Association*. 2008;98(3):212-23.
2. Sever J. Apophysis of os calcis. *NY State J Med*. 1912;95:1025.
3. Madden CC, Mellion MB. Sever's disease and other causes of heel pain in adolescents. *American family physician*. 1996;54(6):1995-2000.
4. Micheli LJ, Ireland ML. Prevention and management of calcaneal apophysitis in children: an overuse syndrome. *Journal of pediatric orthopedics*. 1987;7(1):34-8.
5. Weiner DS, Morscher M, Dicintio MS. Calcaneal apophysitis: simple diagnosis, simpler treatment. *The Journal of family practice*. 2007;56(5):352-5.
6. Scharfbillig RW, Jones S, Scutter S. Sever's disease--does it effect quality of life? *Foot (Edinburgh, Scotland)*. 2009;19(1):36-43.
7. Lawrence DA, Rolan MF, Morshed KA, Moukaddam H. MRI of heel pain. *AJR American journal of roentgenology*. 2013;200(4):845-55.
8. Mustapic M, Boric I, Lepur D, Zadavec D, Viskovic K. Sever's disease complicated with osteomyelitis. *Acta clinica Croatica*. 2014;53(2):252-5.
9. Bizzi M, Junge A, Bahr R, Dvorak J. Injuries of football referees: a representative survey of Swiss referees officiating at all levels of play. *Scandinavian journal of medicine & science in sports*. 2011;21(1):42-7.
10. Karahan YA, Salbaş E, Tekin L, Yaşar O, Küçük A. Sever Hastalığı: Çocuklarda topuk ağrısının önemli bir nedeni; Olgu Sunumu. *Turkish Journal of Osteoporosis/ Turk Osteoporoz Dergisi*. 2014;20(2).
11. Hussain S, Hussain K, Hussain S, Hussain S. Sever's disease: a common cause of paediatric heel pain. *BMJ case reports*. 2013;2013.
12. James AM, Williams CM, Haines TP. Effectiveness of interventions in reducing pain and maintaining physical activity in children and adolescents with calcaneal apophysitis (Sever's disease): a systematic review. *Journal of Foot and Ankle Research*. 2013;6(1):16.
13. Lewin P. Apophysitis of the os calcis. *Surg Gynecol Obstet*. 1926;41:578.
14. Ogden JA, Ganey TM, Hill JD, Jaakkola JI. Sever's injury: a stress fracture of the immature calcaneal metaphysis. *Journal of Pediatric Orthopedics*. 2004;24(5):488-92.
15. Hunt GC, Stowell T, Alnwick GM, Evans S. Arch taping as a symptomatic treatment in patients with Sever's disease: A multiple case series. *The foot*. 2007;17(4):178-83.
16. Orava S, Virtanen K. Osteochondroses in athletes. *British journal of sports medicine*. 1982;16(3):161-8.
17. Lee KT, Young KW, Park YU, Park SY, Kim KC. Neglected Sever's disease as a cause of calcaneal apophyseal avulsion fracture: case report. *Foot & ankle international*. 2010;31(8):725-8.
18. Volpon JB, de Carvalho Filho G. Calcaneal apophysitis: a quantitative radiographic evaluation of the secondary ossification center. *Archives of orthopaedic and trauma surgery*. 2002;122(6):338-41.
19. Wiegerinck JI, Yntema C, Brouwer HJ, Struijs PA. Incidence of calcaneal apophysitis in the general population. *European journal of pediatrics*. 2014;173(5):677-9.
20. Rachel JN, Williams JB, Sawyer JR, Warner WC, Kelly DM. Is radiographic evaluation necessary in children with a clinical diagnosis of calcaneal apophysitis (sever disease)? *Journal of Pediatric Orthopaedics*. 2011;31(5):548-50.

How to cite this article:

Sayar Ş, Ceylan HH, Çaypınar B. Effect of anti-inflammatory treatment on sever's disease management. *J Clin Anal Med* 2019;10(1): 54-7.