

Olanzapine Associated Acute Peripheral Edema and Pericardial Effusion: A Case Report

Mehmet ARSLAN¹ , Ümit BULUT² , Deniz Dilan NAKI³ 

¹Department of Psychiatry, Kırklareli Babaeski State Hospital, Kırklareli, Turkey

²Department of Cardiology, Kırklareli Babaeski State Hospital, Kırklareli, Turkey

³Department of Cardiology, Medipol University Faculty of Medicine, İstanbul, Turkey

ABSTRACT

Olanzapine is a potent atypical antipsychotic drug used for the treatment of schizophrenia and bipolar disorder with approved efficiency. Olanzapine is superior to the typical antipsychotic drugs with low incidence of extrapyramidal side effects, especially tardive dyskinesia. The most common side effects associated with olanzapine are constipation, dyspepsia, weight gain, somnolence, asthenia, dry mouth and dizziness. Peripheral edema associated with olanzapine is rarely reported and as far as we know there is no report in the literature about peripheral

edema concomitant with pericardial effusion related to olanzapine. The mechanism of these side effects associated with olanzapine is still unclear and there are different hypotheses in the literature. Herein we report the first case that developed both peripheral edema and pericardial effusion after olanzapine administration. Although very rarely encountered, clinicians should be aware of these possible side-effects.

Keywords: Olanzapine, atypical antipsychotic, adverse reaction, pericardial effusion, edema

Cite this article as: Arslan M, Bulut Ü, Naki DD. Olanzapine Associated Acute Peripheral Edema and Pericardial Effusion: A Case Report. Arch Neuropsychiatry 2019;56:79-81. <https://doi.org/10.29399/npa.22860>

INTRODUCTION

Olanzapine is a widely prescribed potent antipsychotic drug with approved efficiency for the treatment of schizophrenia and bipolar disorder. Low incidence of extrapyramidal side-effects, especially tardive dyskinesia is the advantage of olanzapine against typical antipsychotics. Constipation, dyspepsia, weight gain, somnolence, asthenia, dry mouth and dizziness are the most common side effects associated with olanzapine (1).

Peripheral edema may occur as a consequence of medical conditions such as renal disease, congestive heart disease, hepatic cirrhosis, protein deficiency or as a drug adverse effect associated with non-steroid anti-inflammatory drugs, steroids, immunotherapy agents and antihypertensive medications. On the other hand, idiopathic edema is defined as accumulation of fluid in the body with the absence of cardiac, renal, hepatic or allergic disease (2). Also, peripheral edema has been reported as a side effect of olanzapine (3).

Pericardial effusion may occur secondary to metabolic diseases, reduced lymphatic drainage (congestive heart failure, cirrhosis, nephrotic syndrome), autoimmune diseases, malignancy, cardiac injury, uremia, drug hypersensitivity, traumatic or idiopathic (4).

Herein, we report a patient developing peripheral edema along with pericardial effusion following olanzapine administration which is, as far as we know, the first case in the literature.

CASE

51-year old, married, high school-educated female patient referred to our hospital with manic symptoms that had been for two weeks. The patient had been having recurrent episodes of depression for 20 years and had used different antidepressant medications. For the last 8 months, she had been using duloxetine 60 mg/daily, trazodone 100 mg/daily. The patient was diagnosed with bipolar disorder in manic episode. Antidepressant treatment was discontinued, olanzapine 10 mg/daily was initiated and increased to 15 mg/daily in two weeks. Two days after dosage increase, the patient referred to our clinic with bilateral swellings on the legs, ankles and hands and was diagnosed as peripheral edema. Edema was confirmed by inspection and classified as grade 3 with pitting of the skin by palpation. There was no erythema, ulceration or color change on the edematous areas. The patient had no history of cardiac or systemic disease and no history of drug usage other than olanzapine within two weeks. There was no recent viral infection. Blood tests including renal (urea, creatinine), hepatic (AST, ALT, GGT, alkaline phosphatase, bilirubins, total protein and albumin), thyroid function tests (TSH, fT4, fT3), complete blood count and serum electrolyte levels, urine test and x-ray chest graph showed no abnormality. The patient was consulted to the internal medicine specialist and cardiologist to rule out possible etiologies that may cause edema such as venous stasis, cardiac failure and etc. Electrocardiogram showed normal sinus rhythm. On echocardiography, pericardial effusion surrounding the heart circumferentially with a width up to 1 cm was detected (Figure 1). Diagnosis of pericarditis was excluded as there

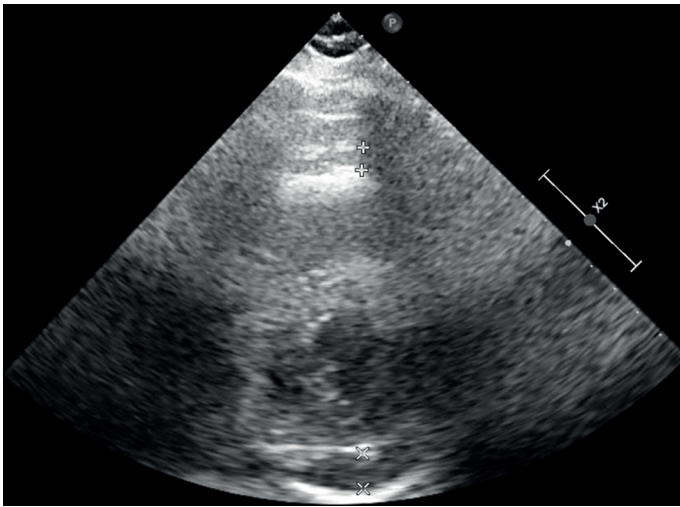


Figure 1. Echocardiography image of patient's pericardial effusion.

was no fever, chest pain, dyspnea or coughing symptom and troponin level, sedimentation rate, total blood count and c-reactive protein levels were within normal limits. Besides, no other cardiac or internal disease that may contribute to patient's complaint was detected. With these findings, peripheral edema and pericardial effusion was presumed as possible olanzapine adverse effect. Olanzapine was discontinued and therapy was modified as risperidone 2 mg/daily and gradually increased to 4 mg/daily. Pericardial effusion and peripheral edema regressed in approximately in two weeks. After one month follow up, the patient's complaints were resolved and manic symptoms declined. Informed consent was obtained from the patient for this case report.

DISCUSSION

This case was regarded as probable olanzapine associated side-effect because the patient has no other risk factor than olanzapine usage. Antidepressant treatment was discontinued before olanzapine administration, symptoms emerged two weeks after olanzapine initiation and clinical findings resolved gradually after drug discontinuation. The patient also had no history of systemic disease. Moreover, according to Naranjo Adverse Drug Reaction Scale, the score was calculated as 7 points, which suggested a probable drug reaction (5).

The mechanism of edema secondary to olanzapine is unclear and has been related to olanzapine induced receptor profile (6). Another suggested mechanism is allergic reaction which was supported with histopathological findings and moderate eosinophilia (7). In our case we did not run histopathological studies. However, blood test showed no eosinophilia.

Reports in the literature demonstrate diverse data about incidence of olanzapine related edema, time of onset (days to months), time to resolution and localization of edema. Although the most effected site was ankle, edema was also reported on hands, face and eyelids (3).

Olanzapine associated edema was reported in different range of dosages (2.5–20 mg). However some authors claim it may occur as dose dependent manner (8). In our case edema occurred after the dosage of olanzapine is increased from 10 to 15 mg/daily, which supports a dose dependent manner. However, it is difficult to make a strong claim, as we did not gradually decrease the dosage after edema occurrence.

Some of the cardiac side effects related to antipsychotic medication are orthostatic hypotension, tachycardia, hypertension, elongation of QT

interval and sudden death. Cardiomyopathy and myocarditis are rarely seen but are potential mortal cardiotoxic effects of antipsychotic medication which are most commonly reported with clozapine treatment (9,10). There are also reports about clozapine related pericarditis, pericardial effusion and polyserositis in the literature (11). Moreover, in a previous case report, paliperidone was associated with pericardial effusion (12).

As far as we know, there is only one case with olanzapine associated pericardial effusion. Alagha et al reported a patient with pleural and pericardial effusion that referred to hospital with chest pain and effort dyspnea that started 3 weeks after olanzapine initiation. There was no peripheral edema and biochemical evaluation of the pleural effusion revealed exudative fluid with 75% eosinophil predominance and also peripheral eosinophilia was detected by blood tests. (13).

To our knowledge, this is the first case in the literature about peripheral edema along with pericardial effusion associated with olanzapine. As there was no blood eosinophilia or pleural effusion, we presume a distinct mechanism for this adverse effects than previous reports.

The underlying mechanisms of cardiotoxic effects like myocarditis, pericarditis or pericardial effusions secondary to atypical antipsychotics is still unclear. The speculations were made according to clinical findings related to clozapine that has a close chemical structural and receptor-blocking profile resembling to olanzapine (14). IgE mediated hypersensitivity reaction (type-1 hypersensitivity) and immunomodulatory hypothesis are the most speculated mechanisms for the adverse effects of clozapine. Hypersensitivity hypothesis was supported by clinical and laboratory findings such as timing in relation to clozapine initiation, papular rash, eosinophilia, elevated serum IgE levels and eosinophilic infiltration in the heart muscle secondary to clozapine usage. However, these findings are contradictory. On the other hand, immunomodulatory hypothesis is supported by the presence of fever, neutrophilia and elevated serum CRP levels (9,11). In our case, we neither evaluated serum IgE levels nor sampled pericardial fluid, but no other abnormality was detected.

Another important hypothesis about cardio toxic effect of clozapine is the rise of catecholamine levels, especially noradrenaline. This hypothesis is supported by development of left ventricle dysfunction as a result of elevated serum noradrenaline levels as seen in Takotsubo cardiomyopathy (15). Despite pericardial effusion, no cardiac symptom or ECG abnormality was detected in our patient and ejection fraction was normal.

Other mechanisms proposed for clozapine associated cardio toxic effects are lack of cytochrome P450 1A2/1A3 enzymes, blockage of calcium dependent ion canal and decrease in serum selenium levels (9).

In conclusion, current data are insufficient to clarify the psychopathological mechanisms contributing to peripheral edema and pericardial effusion secondary to antipsychotic medications. It is of great importance that clinicians should be aware of these rare side effects, observe patients carefully after drug initiation and shift immediately to a less risky antipsychotic treatment in case any side effect is encountered.

Ethics Committee Approval: This study was carried out in accordance with the Helsinki Declaration.

Informed Consent: Informed consent was obtained from the patient for this case report.

Peer-review: Externally peer-reviewed.

Author Contributions: Concept - MA, ÜB, DDN; Design - MA, DDN; Supervision - MA, ÜB; Resource - MA, ÜB; Materials - MA, ÜB; Data Collection and/ or Processing - MA, ÜB, DDN; Analysis and/ or Interpretation - MA, ÜB, DDN; Literature Search - MA, ÜB, DDN; Writing - MA, ÜB; Critical Reviews - MA, ÜB, DDN.

Conflict of Interest: No conflict of interest was declared by the authors.

Financial Disclosure: The authors declared that this study has received no financial support.

REFERENCES

1. Stahl SM. Antipsychotic agents. *Essential Psychopharmacology*, 4th ed. Cambridge: Cambridge University Press; 2015. pp.129–236.
2. Longo DL, Kasper DL, Jameson JL, Fauci AS, Hauser SL, Lascenzo J, editors. Edema. *Harrison's Principles of Internal Medicine*, 18th ed. New York: McGraw-Hill; 2012. pp.797–807.
3. Umar MU, Abdullahi AT. Self-limiting Atypical Antipsychotics-induced Edema: Clinical Cases and Systematic Review. *Indian J Psychol Med* 2016;38:182–188. [\[CrossRef\]](#)
4. Vakamudi S, Ho N, Cremer PC. Pericardial Effusions: Causes, Diagnosis, and Management. *Prog Cardiovasc Dis* 2017;59:380–388. [\[CrossRef\]](#)
5. Naranjo CA, Busto U, Sellers EM, Sandor P, Ruiz I, Roberts EA, Janecek E, Domecq C, Greenblatt DJ. A method for estimating the probability of adverse drug reactions. *Clin Pharmacol Ther* 1981;30:239–245. [\[CrossRef\]](#)
6. Ng B, Postlethwaite A, Rollnik J. Peripheral oedema in patients taking olanzapine. *Int Clin Psychopharmacol* 2003;18:57–59. [\[CrossRef\]](#)
7. Honma M, Minami-Hori M, Tsuji H, Komatsu S, Iizuka H. Olanzapine-induced limb edema simulating episodic angioedema with eosinophilia. *J Dermatol* 2012;39:1105–1106. [\[CrossRef\]](#)
8. Yaluğ I, Tufan AE, Özten E, Alemdar M, Cerit C. Bilateral pedal edema associated with olanzapin use in manic episode of bipolar disorder: report of two cases. *Prog Neuropsychopharmacol Biol Psychiatry* 2007;31:1541–1542. [\[CrossRef\]](#)
9. Yağcıoğlu EA, Ertuğrul A. Antipsikotik ilaçların kardiyovasküler yan etkileri. *Psikiyatride Güncel Yaklaşımlar Derg* 2011;13:157–252.
10. Polcwiartek C, Kragholm K, Schjerning O, Graff C, Nielsen J. Cardiovascular safety of antipsychotics: a clinical overview. *Expert Opin Drug Saf* 2016;15:679–688. [\[CrossRef\]](#)
11. Mouaffak F, Gaillard R, Burgess E, Zaki H, Olié JP, Krebs MO. Clozapine-induced serositis: review of its clinical features, pathophysiology and management strategies. *Clin Neuropharmacol* 2009;32:219–223. [\[CrossRef\]](#)
12. Şahpolat M, Küçükdurmaz Z, Kavakçı Ö, Kurt R. Paliperidone: As a Possible Cause of Pericardial Effusion. *Noro Psikiyatırs Ars* 2014;51:169–171. [\[CrossRef\]](#)
13. Alagha K, Tummino C, Sofalvi T, Chanez P. Iatrogenic eosinophilic pleural effusion. *Eur Respir Rev* 2011;20:118–120. [\[CrossRef\]](#)
14. Schatzberg AF, Nemeroff CB. *The Textbook of Psychopharmacology*, 4th ed. American Psychiatric Publishing 2009. pp.573–599.
15. Elman I, Goldstein DS, Eisenhofer G, Folio J, Malhotra AK, Adler CM, Pickar D, Breier A. Mechanism of peripheral noradrenergic stimulation by clozapine. *Neuropsychopharmacol* 1999;20:29–34. [\[CrossRef\]](#)