

Posterior cruciate-retaining versus posterior-stabilized total knee arthroplasty for osteoarthritis with severe varus deformity



Ethem Ayhan Ünkar ^a, Yusuf Öztürkmen ^{b,*}, Erhan Şükür ^b, Engin Çarkçı ^c, Murat Mert ^d

^a Kartal State Hospital, Department of Orthopedics and Traumatology, Istanbul, Turkey

^b Istanbul Training and Research Hospital, Department of Orthopedics and Traumatology, Istanbul, Turkey

^c Medipol University Sefakoy Hospital, Department of Orthopedics and Traumatology, Istanbul, Turkey

^d Yeni Yuzyl University Gaziosmanpasa Hospital, Department of Orthopedics and Traumatology, Istanbul, Turkey

ARTICLE INFO

Article history:

Received 27 February 2016

Received in revised form

19 June 2016

Accepted 2 September 2016

Available online 17 January 2017

Keywords:

Posterior cruciate ligament-retaining
Posterior cruciate ligament-stabilization
Total knee arthroplasty
Varus deformity

ABSTRACT

Objective: The aim of this study was to compare the radiological and functional results of posterior cruciate ligament (PCL) – retaining and posterior-stabilized total knee arthroplasties in patients with severe varus gonarthrosis.

Methods: Medical records of 112 knees of 96 patients who underwent total knee arthroplasty for severe varus ($\geq 15^\circ$) were reviewed. PCL-retaining and PCL-stabilizing groups consisted of 58 and 54 knees, respectively. Mean follow-up time was 56.6 months (range: 24–112 months). Knee Society (KS) clinical rating system was used in clinical evaluation. Range of motion, degree of flexion contracture, post-operative alignment, and complication rates were compared between the groups.

Results: Mean preoperative mechanical tibiofemoral angle was 20.1° in varus alignment, and was restored to 4.6° in valgus postoperatively. No statistically significant differences were found between PCL-stabilizing and PCL-retaining groups when KS knee scores, function scores, and flexion arc were evaluated. Two patients in PCL-retaining group underwent revision surgery due to aseptic loosening of tibial component. One patient in PCL-stabilizing group needed arthrotomy due to patellar clunk syndrome.

Conclusion: There were no notable differences between the 2 groups and PCL-retaining design had outcomes as good as PCL-stabilizing total knee implant in osteoarthritic knees with severe varus deformity.

Level of evidence: Level III, Therapeutic study.

© 2016 Turkish Association of Orthopaedics and Traumatology. Publishing services by Elsevier B.V. This is an open access article under the CC BY-NC-ND license (<http://creativecommons.org/licenses/by-nc-nd/4.0/>).

Patients with pain and restrictions to daily functions that impair quality of life, have deformity, or instability of arthritic knee joint can be successfully treated with total knee arthroplasty (TKA).^{1,2} Performing TKA in severe varus knees is technically more challenging than routine primary TKA of neutrally aligned knees. It remains controversial, and the literature is also indecisive about fate of posterior cruciate ligament (PCL) in TKA with severe varus deformity of knee.^{3–7} Some surgeons decide to preserve or sacrifice PCL preoperatively based on their experience and training, while others decide intraoperatively after evaluating morphology of PCL,

knee alignment, range of motion (ROM) and stability of knee. Several papers have been published comparing outcomes of PCL-retaining and PCL-stabilizing types of prostheses in neutrally aligned knees,^{8–23} but as far as we know, there are no novel studies comparing results of the 2 designs in severe varus knees. Although supporters of PCL-stabilizing type of prostheses claim that use of PCL-retaining TKA in severe varus deformity is relatively contraindicated, the present study was performed to test the hypothesis that it is possible to have comparable results with PCL-retaining designs.

Patients and methods

Between March 2002 and December 2013, 2158 TKA were performed at our institution. When our institutional computerized

* Corresponding author.

E-mail address: yozturkmen@gmail.com (Y. Öztürkmen).

Peer review under responsibility of Turkish Association of Orthopaedics and Traumatology.

database was reviewed, 176 patients (214 knees) who underwent TKA due to severe varus deformity of the knee were identified.

Patients who had previous distal femoral or proximal tibial osteotomies, defects in the cut proximal tibia condyle that needed bone grafting or metal wedges to achieve stable axial implantation of tibial prosthesis, previous knee arthroplasty, diagnosis of malignant disease or infection, previous patellectomy, extra-articular deformity, or less than 2 years of follow-up were excluded from the study. In 6 patients (5 female, 1 male), metal wedges were implanted due to bone defects in proximal tibial condyle to achieve stable axial implantation of tibial component. Tibial trays of both implants evaluated in this study were not suitable for application of metal wedges, therefore revision-type, long-stemmed tibial components were used in these patients. Stem extension changes biomechanical design of the prosthesis and may affect implant survival rate.²⁴ Using just one particular prosthetic design is a strength of our study and eliminated bias. Design of the components was dissimilar, and though it was rather small number of patients, we found it more convenient to exclude these patients from the study.

Total of 96 patients (112 knees) with preoperative and postoperative clinical and radiological assessments and minimum 2 years of follow-up were included in this study. Of the 96 patients, 64 were female (72 knees) and 32 were male (40 knees), with mean age of 69 ± 6.4 years (range: 48–83 years).

Knee alignment was defined mechanically on long-standing radiograph as the angle between mechanical axes of femur and tibia (Fig. 1). Knee Society (KS) criteria group severity of knee deformity as: mild ($\leq 5^\circ$), moderate ($6-10^\circ$), marked ($11-15^\circ$), or severe ($> 15^\circ$).²⁵ According to these criteria, we defined participant knees with coronal angle $\geq 15^\circ$ in varus direction as severe varus deformity.

In all cases, standard medial parapatellar approach was used. Distal femoral cuts were made using intramedullary alignment jig at 6° of valgus. After determining epicondylar axis for anatomic rotation of femur, posterior referencing instrumentation was used. Tibial cuts were made with extramedullary guiding. Sequential ligament releases were done starting from deep medial collateral ligament (MCL), then superficial MCL, and posteromedial capsule, if needed, until well-aligned and stable knee was obtained. Flexion contractures were corrected with removal of posteromedial tibial osteophytes and, when necessary, by elevation of capsule from posterior femur. Surgery was not terminated unless flexion and extension spaces were balanced and leg and components were thought to be properly aligned. No residual flexion contracture was observed. With trial components in place, limb stability and balance were evaluated.

All procedures were performed by 3 experienced staff surgeons using standardized approach, and all patients received 1 of 2 designs of cemented, fixed-bearing total knee replacement. PCL-stabilizing prostheses used in this study comprised 21 Performance Total Knee System (Biomet Spain Orthopaedics, Valencia, Spain) and 33 Vanguard Complete Knee System (Biomet Inc., Warsaw, IN, USA). PCL-retaining designs used were 19 Performance Total Knee System (Biomet Spain Orthopaedics, Valencia, Spain) and 39 Vanguard Complete Knee System (Biomet Inc., Warsaw, IN, USA). Implant selection was at the discretion of the surgeon. One of the operating surgeon preferred PCL-stabilizing type of prosthesis, believing that it theoretically confers advantages such as joint stability and physiological kinematics.

In 18 patients (13 female, 5 male), 22 patellae were resurfaced. Cemented, polyethylene components were used. Remaining patients underwent osteophyte resection and patellar denervation.

All patients received 1 gr cefazolin intravenously 60 min before the procedure, and antibiotics prophylaxis, which was discontinued

within 24 h postoperatively. For venous thromboembolism prophylaxis, low-molecular-weight heparin was administered to all patients for 21 days. Identical rehabilitation program was administered for all patients. They were allowed to bear weight as tolerated at first postoperative day and ROM increased in the following days.

Clinical evaluation was done using KS clinical rating system in preoperative assessment and throughout follow-up. Anteroposterior and lateral knee radiographs were taken preoperatively, once again 1, 3, and 6 months postoperatively, and then annually. Postoperative periprosthetic radiolucency was evaluated in order to determine any aseptic loosening. All patients were assessed with orthoroentgenographs preoperatively and at last follow-up visit, and analog goniometer was used for mechanical tibiofemoral angle measurements. Postoperative varus alignment was recorded as negative degrees. Radiolucent lines and their progression were noted using KS radiographic evaluation system. Radiological evaluation of patients was performed only by the senior surgeon. Preoperative and postoperative flexion arc measurements were recorded using standard manual goniometer.

This study was approved by our institutional ethics committee (approval number 380/2013) and written, informed consent was obtained from all patients for their demographic and radiological data to be used.

SPSS software version 15.0 for Windows (SPSS Inc., Chicago, IL, USA) was used for statistical analyses. Descriptive statistics have been stated as number and percentage, and numerical statistics have been presented as mean, standard deviation, minimum, and maximum values. Since numerical values between 2 independent groups were not normally distributed, Mann–Whitney U test was used to compare these groups. Ratios of categorical variables between the groups were analyzed using chi-square test. As conditions for parametric tests were not met, Spearman's correlation analysis was used to evaluate numerical variables. Alpha level for statistical significance was accepted as less than 0.05 ($p < 0.05$).

Results

Mean follow-up with complete clinical and radiological data was 56.6 ± 19.8 months (range: 24–112 months). There were no significant differences in patient demographics (Table 1). Among the 96 patients, indication for TKA was idiopathic arthritis in 88 (101 knees), rheumatoid arthritis in 5 (8 knees), and post-traumatic arthritis in 3 patients (3 knees).

Preoperative mean mechanical tibiofemoral angle was $20.1 \pm 3.0^\circ$ (range: $15-28^\circ$) in varus alignment. Tibiofemoral angle was restored to mean of $4.6 \pm 2.1^\circ$ (range: $-2-8^\circ$). Of 112 knees, 76 (68%) were in acceptable range of $4-6^\circ$ of valgus. Mean preoperative and postoperative alignments according to implant designs are provided in Table 2.

Mean KS knee score was 45 ± 5.5 (range: 22–56) preoperatively. Mean postoperative KS knee score was 90 ± 7.9 (range: 40–100). Mean KS function score was 32.1 ± 8.1 (range: 5–45) preoperatively and 83.6 ± 11.4 (range: 20–95) postoperatively. Scores distributed according to prosthesis design are given in Table 3.

Both mean KS knee score and mean KS function score were significantly improved postoperatively ($p = 0.022$, $p = 0.018$). Since patients were grouped according to design of prosthesis implanted, there were no significant difference between the 2 groups based on postoperative KS knee scores ($p = 0.823$) and KS function scores ($p = 0.269$).

Patients were then grouped based on postoperative alignment: neutrally aligned ($4-6^\circ$ valgus) and others. There was no statistically significant difference between PCL-stabilizing and PCL-retaining design with regard to postoperative neutral alignment

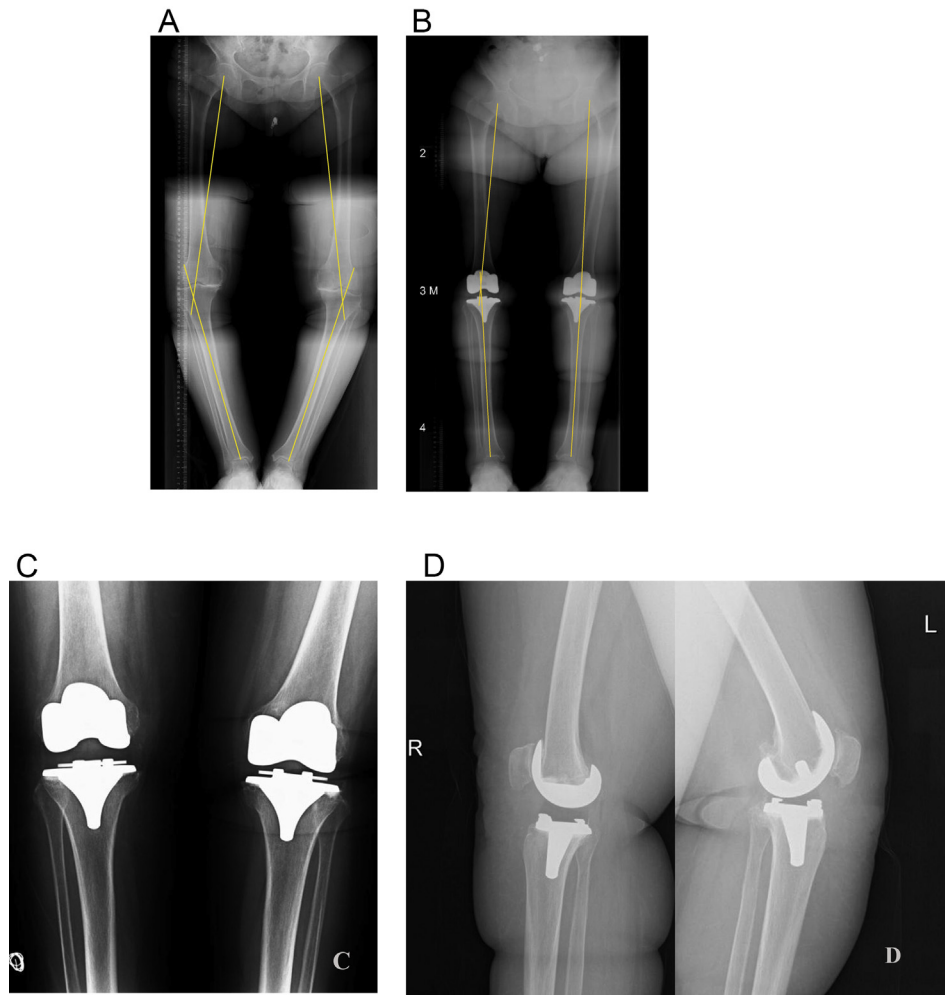


Fig. 1. A 68-year-old woman with bilateral osteoarthritis of knee with severe varus deformity. (a) Preoperative orthoroentgenography revealed right and left varus alignment of 17° and 19°, respectively. (b) At 56 months follow-up for right knee and 62 months for left knee, postoperative orthoroentgenography revealed right and left valgus alignment of 2° and 6°, respectively. (c) Anteroposterior radiography at last follow-up visit. (d) Lateral radiographs of the same patient showing implantation of posterior cruciate ligament (PCL)-stabilizing prosthesis on right knee and PCL-retaining prosthesis on left knee.

Table 1

Demographic data of the patients who underwent total knee arthroplasty due to severe varus deformity of the knee.

	PCL-retaining	PCL-stabilizing	p
Age (years)	69.7 ± 5.9	68.2 ± 6.8	.332
Gender			.778
Female (n)	29	27	
Male (n)	20	20	
Mean follow-up (mo)	57.4 ± 18.8	55.7 ± 21.1	.433
Body mass index (kg/m ²)	26.6 ± 2.4	26.8 ± 3.1	.757

Table 2

Preoperative and postoperative alignments according to implant designs.

	PCL-stabilizing	PCL-retaining	p
Preoperative (Varus)	20.5° ± 2.8 (16°–26°)	19.8° ± 3.1 (15°–28°)	0.192
Postoperative (Valgus)	4.8° ± 2.1 (–2° to 8°)	4.4° ± 2.0 (0°–8°)	0.131

($p = 0.885$). Of patients with PCL-retaining model, 68% were within neutral alignment range, while the figure was 67% for PCL-stabilizing group.

In both groups, an increase in flexion arc was observed. Although there was no significant difference in postoperative mean

flexion degree reached between the 2 groups, patients in PCL-stabilizing group had 4.7° greater flexion arc (Table 4).

Patients had mean of $11.5 \pm 4.2^\circ$ (range: 0–30°) flexion contracture preoperatively. At last follow-up, no residual flexion contracture was noted.

Two knees failed and revision surgery was performed. Mean KS knee score was 42.5 ± 3.5 and mean KS function score was 22.5 ± 3.5 at final follow-up visit. Mean time for revision was 56 months (range: 54–58 months). Both patients had aseptic loosening of tibial component with radiolucencies exceeding 7 mm and had PCL-retaining type of total knee prosthesis. Incidence of aseptic loosening requiring revision surgery was not significantly different between the 2 groups ($p = 0.169$). A total of 3 patients had superficial infection (2 in PCL-stabilizing group, 1 in PCL-retaining group), which needed no additional surgical procedure and were treated with prolonged antibiotic administration ($p = 0.517$). One patient with PCL-stabilizing model of total knee prosthesis had patellar clunk and pain on extension. Arthrotomy was performed in sixth postoperative month and suprapatellar fibrous tissue that lodged in intercondylar notch of femoral component during flexion and dislodged on extension was removed, allowing patella to glide smoothly. Postoperatively, patient's symptoms resolved completely.

Table 3
Preoperative and postoperative knee society knee scores and function scores.

	Knee score		Function score	
	Preoperative	Postoperative	Preoperative	Postoperative
PCL-stabilizing	44.5 ± 5.9 (22–56)	90.9 ± 4.1 (80–100)	32.4 ± 7.9 (5–45)	83.9 ± 7.6 (60–95)
PCL-retaining	45.5 ± 5.1 (36–56)	89.2 ± 10.3 (40–100)	31.8 ± 8.4 (5–45)	83.4 ± 14.1 (20–95)
p	0.479	0.823	0.591	0.269

Table 4
Knee flexion in PCL-retaining and PCL-stabilizing implants.

	PCL-stabilizing	PCL-retaining	p
Preoperative	91.8 ± 8.7 (65–110)	90.6 ± 6.1 (60–110)	0.625
Postoperative	119.2 ± 5.1 (105–125)	114.5 ± 5.9 (100–125)	0.275

Discussion

All modern total knee prosthesis designs, when implanted by experienced surgeons, are very efficient at repairing deformity and instability of osteoarthritic knees with severe varus deformity. In the ongoing debate regarding use of PCL-retaining or PCL-stabilizing design for varus knee deformity, there are papers in favor of each model.^{25–32} A popular and logical belief is that PCL-retaining design may perform well in knees without preoperative deformity, but may perform poorly if preoperative deformity exists. This study presents well-documented intermediate-term results of PCL-retaining and PCL-stabilizing designs implanted in osteoarthritic knees with severe varus deformity.

Several studies have been conducted to determine clinical outcomes of particular design in severe varus knee. Mullaji et al²⁸ evaluated 173 knees of 117 patients with varus deformity exceeding 20°. In their study, PCL-substituting implants were used in all knees, and they reported that mean postoperative KS knee score and KS function score were 91.1 ± 22.8 and 72.1 ± 18.7, respectively, at an average follow-up period of 2.6 years. Karachalios et al²⁹ and Meftah et al³⁰ also reported similar results confirming that severe varus deformities can be successfully treated with PCL-stabilizing prostheses. Faris et al³⁰ reported satisfactory results with PCL-retaining prosthesis when good ligament balance was obtained. In their study, results of PCL-retaining prostheses used in deformed knees were evaluated. Of 473 knees, 96 had preoperative varus deformity of ≥11°. The overall results of our study are comparable to those of previous studies.

Degenerative changes varying from mild to severe were observed in PCL samples taken during TKA. Although it is suggested that PCL is absent or non-functional in most TKA patients, some studies have shown that PCL is intact in 94% of knees necessitating prosthesis and plays a role in normal recreation of knee kinematics.^{3,6} Conditt et al,⁷ compared the results of 49 patients with either PCL-retaining or PCL-stabilizing TKA. They concluded that PCL-stabilizing implants do not restore full functional capacity of PCL. PCL functions to stabilize the knee during flexion, as PCL prevents anterior femoral translation over tibia. Also, advocates of PCL-retaining designs offer preservation of PCL for proprioception and maintenance of femoral rollback over tibia. Harner et al⁴ compared PCL-retaining and PCL-stabilizing prostheses and concluded in their study that proprioception was better in PCL-retaining group and that it is important to maintain original anatomy when possible. However, a femoral roll-back without anterior cruciate ligament can cause high-contact stress on polyethylene of prosthesis and increase wear rates.

PCL-stabilizing prostheses were designed for better congruency between femoral component and tibial polyethylene insert. PCL-

stabilizing implants are made to resemble PCL with polyethylene post and femoral cam that collaborate to prevent anterior translation and to allow femoral roll-back during flexion.^{3,7,8} With improvements to femoral cam mechanism, increase in knee range of motion was observed. Harato et al¹⁰ reported that, at a minimum of 5 years follow-up, PCL-stabilizing prostheses had significantly higher flexion degree compared to PCL-retaining designs. Regarding postoperative alignment, ROM, and residual flexion contracture, Laskin et al²⁶ reported better outcomes with PCL-stabilizing prosthesis in severe varus knees. However, in some studies that compared ROM between 2 designs, no statistically significant differences were reported.^{11,12,14} Present study had similar results. Although PCL-stabilizing group mean postoperative flexion arc was 4.7° higher, the difference between the 2 groups was statistically insignificant (p = 0.275).

Our study showed no difference in postoperative complications between the groups. Other than aseptic loosening, there were no cases necessitating operative revision. Only 1 patient, who had PCL-stabilizing prosthesis, had symptoms of patellar clunk syndrome and needed arthroscopy to remove elastic fibrous tissue at junction of quadriceps tendon and superior pole of patella. Geometry of intercondylar box plays a significant role in development of patellar clunk syndrome.^{33,34}

One of the most used parameters to assess arthroplasty results is survival rate. Abdel et al²² reviewed 8117 TKA and compared survival rate in knees with preoperative deformity of >15°. Survival rate of knees at 15 years for PCL-retaining and PCL-stabilizing implants were 90% and 77%, respectively.²² Laskin et al²⁶ had contradictory results and reported increased revision rate in fixed deformities treated with PCL-retaining implants. Similarly, in our study, only 2 PCL-retaining prostheses were diagnosed with aseptic failure and revision surgery was performed.

Extensive medial soft tissue release is needed to achieve neutral limb alignment for severely varus-deformed knees. Equal flexion-extension gaps after medial release are very important for proper knee stability. Medial and lateral gap differences in varus knees after medial release have been compared between cruciate-retaining and PCL-sacrificing TKA.^{23,28} In a study by Kim et al,²³ medial gap showed greater increase in PCL-sacrificing groups than in cruciate-retaining groups. Based on this data, we were cautious to avoid over-release of medial soft tissue in PCL-stabilizing implants. Tibial component downsizing and resection of uncapped proximal medial bone were considered to reduce the amount of soft tissue release required to balance the knee. This technique was described by Dixon et al, and resulted in relative lengthening of medial ligamentous structures without compromising their integrity, which usually occurs with over-release techniques.³⁵ A tray that is 1 size smaller is selected and lateralized to cortical margin of lateral tibia. Remaining proximal medial bone overhanging medial aspect of tibial tray is removed. Release of semimembranosus extending posteromedial to capsule provides correction of associated flexion contracture. In rare cases where medial tightness persists, a multiple-needle puncture technique of posterior aspect of the MCL was performed with knee in extension and under tension. However, it is suggested that superiority of PCL-retaining using equal gap technique was not directly reflected to

clinical outcomes.^{36,37} Also, in a gait analysis study, it was observed that no differences existed in kinematics and kinetics between PCL-stabilizing and PCL-retaining designs.³⁸ But some authors advocate use of PCL-stabilizing prosthesis design for patients who have risk factors for balance disorder due to higher dynamic anteroposterior stability of this design.³⁹

The present study has some limitations. The relatively small number of patients, the retrospective nature of the study, and patient selection method limit the value of our conclusions. Also, absence of documentation of intraoperative findings may have affected our study results. Although all surgeries were performed with standardized technique, involvement of multiple surgeons may be defined as a limitation to this study. As measurement of radiographic data was conducted by only 1 senior surgeon, statistical evaluation for degree of interobserver reliance could not be performed. Also, not analyzing intraobserver reproducibility of the assessment is a shortcoming of this study. However, there are some strengths to the study. All surgeries were performed using the same technique. In addition, implant design was the same in terms of shape of femoral component and the shape of articular surface of the 2 different tibial inserts. Finally, since orthoroentgenography was obtained for each patient, alignment measurement inaccuracies and extra-articular deformities were eliminated as much as possible.

In conclusion, regarding intermediate-term results of clinical and functional parameters analyzed in our study, there were no notable differences between the 2 groups. PCL-retaining design had outcomes as good as PCL-stabilizing total knee implant in osteoarthritic knees with severe varus deformity. As our knowledge improves in the field of biomechanics and kinematics, results of randomized clinical trials will provide a better understanding of the outcomes of different designs of total knee prostheses used in severe varus knees.

References

- Gill GS, Joshi AB, Mills DM. Total condylar knee arthroplasty. 16- to 21-year results. *Clin Orthop Relat Res.* 1999;367:210–215.
- Rodriguez JA, Bhende H, Ranawat CS. Total condylar knee replacement: a 20-year followup study. *Clin Orthop Relat Res.* 2001;388:10–17.
- Scuderi GR, Pagnano MW. Review article: The rationale for posterior cruciate substituting total knee arthroplasty. *J Orthop Surg.* 2001;9(2):81–88.
- Harner CD, Xerogeanes JW, Livesay GA, et al. The human posterior ligament complex: an interdisciplinary study. Ligament morphology and biomechanical evaluation. *Am J Sports Med.* 1995;23(6):736–745.
- Yue B, Varadarajan KM, Rubash HE, Li G. In vivo function of posterior cruciate ligament before and after posterior cruciate ligament-retaining total knee arthroplasty. *Int Orthop.* 2012;36:1387–1392.
- Tatani I, Kouzelis A, Megas P. Long term clinical outcome of total knee arthroplasty. The effect posterior cruciate retaining design. In: Karachalios T, ed. *Total Knee Arthroplasty. Long Term Outcomes.* London: Springer-Verlag; 2015:125–133.
- Conditt MA, Noble PC, Bertolusso R, Woody J, Parsley BS. The PCL significantly affects the functional outcome of total knee arthroplasty. *J Arthroplasty.* 2004;19(7 Suppl 2):107–112.
- Lozano-Calderón SA, Shen J, Doumato DF, Greene DA, Zelicof SB. Cruciate-retaining vs posterior-substituting inserts in total knee arthroplasty. Functional outcome comparison. *J Arthroplasty.* 2013;28:234–242.
- Li N, Tan Y, Deng Y, Chen L. Posterior cruciate-retaining versus posterior-stabilized total knee arthroplasty: a meta-analysis of randomized controlled trials. *Knee Surg Sports Traumatol Arthrosc.* 2014;22(3):556–564.
- Harato K, Bourne RB, Victor J, Snyder M, Hart J, Ries MD. Midterm comparison of posterior cruciate-retaining versus-substituting total knee arthroplasty using the Genesis II prosthesis. A multicenter prospective randomized clinical trial. *Knee.* 2008;15(3):217–221.
- Victor J, Banks S, Bellemans J. Kinematics of posterior cruciate ligament-retaining and-substituting total knee arthroplasty: a prospective randomized outcome study. *J Bone Joint Surg Br.* 2005;87(5):646–655.
- Sando T, McCalden RW, Bourne RB, MacDonald SJ, Somerville LE. Ten-year results comparing posterior cruciate-retaining versus posterior cruciate-substituting total knee arthroplasty. *J Arthroplasty.* 2015;30(2):210–215.
- Scott DF, Smith RR. A prospective, randomized comparison of posterior stabilized versus cruciate-substituting total knee arthroplasty: a preliminary report with minimum 2-year results. *J Arthroplasty.* 2014;29(9 Suppl):179–181.
- Tanzer M, Smith K, Burnett S. Posterior-stabilized versus cruciate-retaining total knee arthroplasty: balancing the gap. *J Arthroplasty.* 2002;17(7):813–819.
- Bercik MJ, Joshi A, Parvizi J. Posterior cruciate-retaining versus posterior-stabilized total knee arthroplasty: a meta-analysis. *J Arthroplasty.* 2013;28:439–444.
- Mouttet A, Sourdet V. EUROP total knee prosthesis with or without posterior cruciate ligament retention? Comparative study at mid-term follow-up. *Orthop Traumatol Surg Res.* 2014;100(8):895–900.
- Udomkiat P, Meng BJ, Dorr LD, Wan Z. Functional comparison of posterior cruciate retention and substitution knee replacement. *Clin Orthop Relat Res.* 2000;378:192–201.
- Chaudhary R, Beauprè LA, Johnston DW. Knee range of motion during the first two years after use of posterior cruciate-stabilizing or posterior cruciate-retaining total knee prostheses. A randomized clinical trial. *J Bone Joint Surg Am.* 2008;90(12):2579–2586.
- Kawakami Y, Matsumoto T, Takayama K, et al. Intermediate-term comparison of posterior cruciate-retaining versus posterior-stabilized total knee arthroplasty using the new knee scoring system. *Orthopedics.* 2015;38(12):e1127–e1132.
- Dorr LD, Ochsner JL, Gronley J, Perry J. Functional comparison of posterior cruciate-retained versus cruciate-sacrificed total knee arthroplasty. *Clin Orthop Relat Res.* 1988;236:36–43.
- Clark CR, Rorabeck CH, MacDonald S, MacDonald D, Swafford J, Cleland D. Posterior-stabilized and cruciate-retaining total knee replacement: a randomized study. *Clin Orthop Relat Res.* 2001;392:208–212.
- Abdel MP, Morrey ME, Jensen MR, Morrey BF. Increased long-term survival of posterior cruciate-retaining versus posterior cruciate-stabilizing total knee replacements. *J Bone Joint Surg Am.* 2011;93(22):2072–2078.
- Kim SM, Jang SW, Seo JG, Lee SS, Moon YW. Comparison of cruciate retaining and PCL sacrificing TKA with respect to medial and lateral gap differences in varus knees after medial release. *J Arthroplasty.* 2015;30:26–30.
- Vasarheyi EM, MacDonald SJ, Della Valle CJ, Vail TP. Let's do a revision total knee arthroplasty. *Instr Course Lect.* 2014;53:239–251.
- Lee BS, Lee SJ, Kim JM, Lee DH, Cha EJ, Bin SI. No impact of severe varus deformity on clinical outcome after posterior stabilized total knee arthroplasty. *Knee Surg Sports Traumatol Arthrosc.* 2011;19:960–966.
- Laskin RS. The Insall Award. Total knee replacement with posterior cruciate ligament retention in patients with a fixed varus deformity. *Clin Orthop Relat Res.* 1996;331:29–34.
- Ritter MA, Faris GW, Faris PM, Davis KE. Total knee arthroplasty in patients with angular varus or valgus deformities of $\geq 20^\circ$. *J Arthroplasty.* 2004;19(7):862–866.
- Mullaji AB, Padmanabhan V, Jindal G. Total knee arthroplasty for profound varus deformity: technique and radiological results in 173 knees with varus of more than 20 degrees. *J Arthroplasty.* 2005;20(5):550–561.
- Karachalios T, Sarangi PP, Newman JH. Severe varus and valgus deformities treated by total knee arthroplasty. *J Bone Joint Surg Br.* 1994;76(6):938–942.
- Meftah M, Blum YC, Raja D, Ranawat AS, Ranawat CS. Correcting fixed varus deformity with flexion contracture during total knee arthroplasty: the "inside-out" technique: AAOS exhibit selection. *J Bone Joint Surg Am.* 2012;94(10):e66.
- Faris PM, Herbst SA, Ritter MA, Keating EM. The effect of preoperative knee deformity on the initial results of cruciate-retaining total knee arthroplasty. *J Arthroplasty.* 1992;7(4):527–530.
- Kubiak P, Archibeck MJ, White RE. Cruciate retaining total knee arthroplasty in patients with at least fifteen degrees of coronal plane deformity. *J Arthroplasty.* 2008;23(3):366–370.
- Hozack WJ, Rothman RH, Booth Jr RE, Balderston RA. The patellar clunk syndrome. A complication of posterior stabilized total knee arthroplasty. *Clin Orthop Relat Res.* 1989;241:203–208.
- Yau WP, Wong JW, Chiu KY, Ng TP, Tang WM. Patellar clunk syndrome after posterior stabilized total knee arthroplasty. *J Arthroplasty.* 2003;18(8):1023–1028.
- Malkani AL, Hitt KD, Badarudeen S, et al. The difficult primary total knee arthroplasty. *Instr Course Lect.* 2016;65:243–266.
- Matsumoto T, Muratsu H, Kawakami Y, et al. Soft-tissue balancing in total knee arthroplasty: cruciate-retaining versus posterior-stabilized, and measured-resection versus gap technique. *Int Orthop.* 2014;38:531–537.
- Matsuzaki T, Matsumoto T, Muratsu H, et al. Kinematic factors affecting post-operative knee flexion after cruciate-retaining total knee arthroplasty. *Int Orthop.* 2013;37:803–808.
- Van den Boom LG, Halbertsma JP, Van Raaij JJ, Brouwer RW, Bulstra SK, Van den Akker-Scheek I. No difference in gait between posterior cruciate retention and the posterior stabilized design after total knee arthroplasty. *Knee Surg Sports Traumatol Arthrosc.* 2014;22:3135–3141.
- İşyar M, Saral I, Güler O, Çakar E, Mahiroğulları M. Can prosthesis design of total knee arthroplasty affect balance? *Eklemler Hastalıkları Cerrahisi.* 2015;26(2):72–76.