



Contents lists available at ScienceDirect

## International Journal of Surgery Case Reports

journal homepage: [www.casereports.com](http://www.casereports.com)

## Nerve sheath myxoma of the dorsal paravertebral space

Melih Malkoc<sup>a,\*</sup>, Tugrul Ormeci<sup>b</sup>, Mert Keskinbora<sup>a</sup>, Adem Yılmaz<sup>c</sup>, Ozgur Korkmaz<sup>a</sup>, Canan Besleyici Tanik<sup>d</sup><sup>a</sup> Department of Orthopedics and Traumatology, Istanbul Medipol University, School of Medicine, Turkey<sup>b</sup> Department of Radiology, Istanbul Medipol University, School of Medicine, Turkey<sup>c</sup> Department of Neurosurgery, Sisli Research and Education Hospital Istanbul, Turkey<sup>d</sup> Department of Pathology, Sisli Research and Education Hospital Istanbul, Turkey

## ARTICLE INFO

## Article history:

Received 24 April 2014

Received in revised form 31 July 2014

Accepted 6 October 2014

Available online 16 October 2014

## Keywords:

Nerve sheath tumor

Myxoma

Neurothekeoma

Paravertebral space

## ABSTRACT

**INTRODUCTION:** Nerve sheath myxomas (NSM) are rare benign soft tissue tumors. The dorsal paravertebral placed NMS diagnosis can be difficult.**PRESENTATION OF CASE:** This article presents clinical, radiological findings and treatment of the NSM of the dorsal paravertebral space in a 32-year-old man presented with a right shoulder and back pain for 4 years.**DISCUSSION:** NSM is a rare and benign tumor and that most often occurs in the skin of the head, neck or upper limbs of younger patients. Rare locations such as intracranial, spinal canal, trunk, lower limb and oral cavity were also reported. The appropriate treatment of NSM is surgical excision. Diagnosis is difficult in an uncommon presentation.**CONCLUSION:** Although the most presented case of NMS are dermal tumors, it may also be found extremely rare locations. We conclude that, the definitive treatment of NSM is surgical excision with safe margins even when it is possible.© 2014 The Authors. Published by Elsevier Ltd. on behalf of Surgical Associates Ltd. This is an open access article under the CC BY-NC-SA license (<http://creativecommons.org/licenses/by-nc-sa/3.0/>).

## 1. Introduction

Nerve sheath myxomas (NSM) are rare benign soft tissue tumors that have a predilection to head–neck region and upper limbs.<sup>1</sup> Although, the majority of NSM are commonly dermal, other locations like mucosal, intracranial and intraspinal have also been described. We report a case of dorsal NSM with misdiagnose of nearly 4 years. To the best of our knowledge, it was the first case of NSM involving the dorsal paravertebral space, reported in the English literature to date.

## 2. Presentation of case

A 32-year-old otherwise healthy man presented with a right shoulder and back pain for 4 years. Recently, pain starts to continue at rest and patient describing difficulty in falling asleep and had difficulty to perform his daily activities and working schedule.

Positivity of Jobe test, dropping sign, Hawkins test, Yergason test and Speed test observed in the physical examination of right shoulder. Scapular instability was determined. The patient defines

\* Corresponding author at: Department of Orthopedic and Traumatology, Istanbul Medipol University, School of Medicine, Tem Avrupa Otoyolu Goztepe Cikisi, No. 1 Bagcilar, 34214 Istanbul, Turkey. Tel.: +90 212 4607777; fax: +90 212 4607070.

E-mail address: [memalkoc@yahoo.com](mailto:memalkoc@yahoo.com) (M. Malkoc).

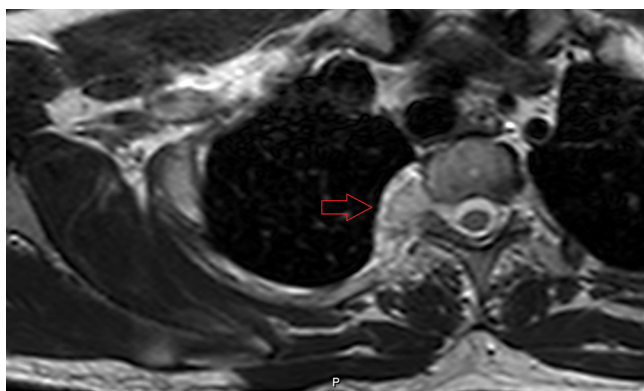
<http://dx.doi.org/10.1016/j.ijscr.2014.10.003>

2210-2612/© 2014 The Authors. Published by Elsevier Ltd. on behalf of Surgical Associates Ltd. This is an open access article under the CC BY-NC-SA license (<http://creativecommons.org/licenses/by-nc-sa/3.0/>).

slight tenderness with deep palpation of spinal process between T2 and T5, but no mass identified. There was no motor and sensorial deficiency determined on the shoulder and arm musculature. Many different diagnostic and treatment modalities was performed initially, like acupuncture, electromyography or shoulder and cervical magnetic resonance imaging (MRI). None of these modalities could achieve to show an abnormality or reduce the pain. A thoracal MRI was performed in our hospital.

Magnetic resonance imaging showed an ill-defined, solid tumor located in the right paravertebral space between T2 and T4 vertebrae. The lesion extends into thorax with an extrapulmonary fashion at the level of T2–3 where it develops destruction on the adjacent rib and transverse process. The lesion had slight heterogeneous high intensity when compared with muscle tissue on T1- and bright signal intensity echo on T2-weighted images. Enhancement identified in the lesion after intravenous contrast administration. The lesion measured 15 mm × 17 mm in the axial plane (Fig. 1) and 20 mm in the coronal plane (Fig. 2).

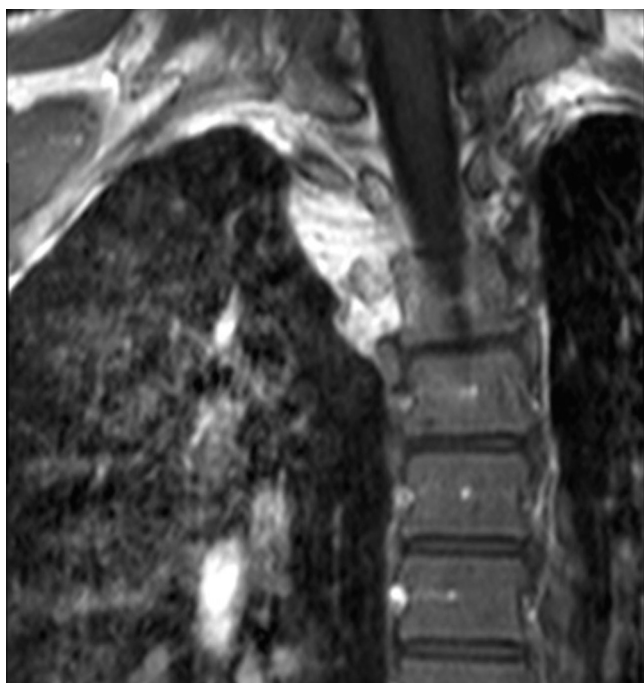
In the differential diagnosis of nerve sheath myxoma, aggressive angiomyxoma, myxoid neurofibroma, low grade fibro myxoid sarcoma, myxoid liposarcoma, low grade myxo fibrosarcoma, cellular myxoma, juxta-articular myxoma, nodular fasciitis must be in mind. For this reason patient undergone a closed biopsy with administration of local anesthesia and sedation. From a lancet tip small incision, a Jamshidi needle inserted by the guidance of Computerized Tomography. Three tissue samples were taken from



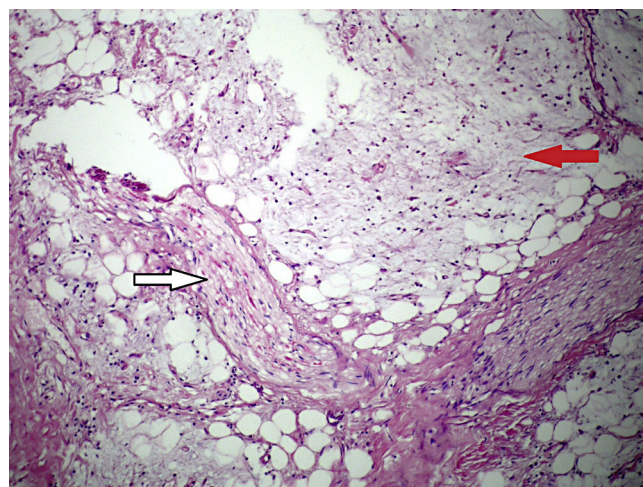
**Fig. 1.** In axial TSE T2 MR image; there is slightly heterogeneous hyperintense lesion is seen at the level of T2–T3.

different parts of the lesion. Pathological interpretation revealed a myxomatous lesion without any signs of malignancy (Figs. 3 and 4).

Complete excision of the lesion was performed by a longitudinal midline incision over the lesion side. By blunt dissections of the right paravertebral muscles, pseudocapsule of the lesion was reached. Although, the close relation of the mass with the nearby vertebral bodies and the ribs, no invasion to the bony tissue was observed. The adjacent pleural membrane was intact. Intra-operative frozen section was confirmed the benign nature of the lesion. Two pieces of grayish-pink tumor tissue was excised by careful blunt dissections. According to pathology report there was no mitotic activity and no lipoblasts. The excised material was hypocellular, composed of bland cells and scant blood vessels. The tumor was immunohistochemically characterized as a NSM given its positive immunoreactivity for S-100 protein, CD10 and epithelial membrane antigen, with no immunoreactivity to cytokeratin.



**Fig. 2.** Post contrast coronal SPIR TSE T1 image shows contrast enhanced lesion located between T2 and T4 vertebrae with extrapulmonary fashion.



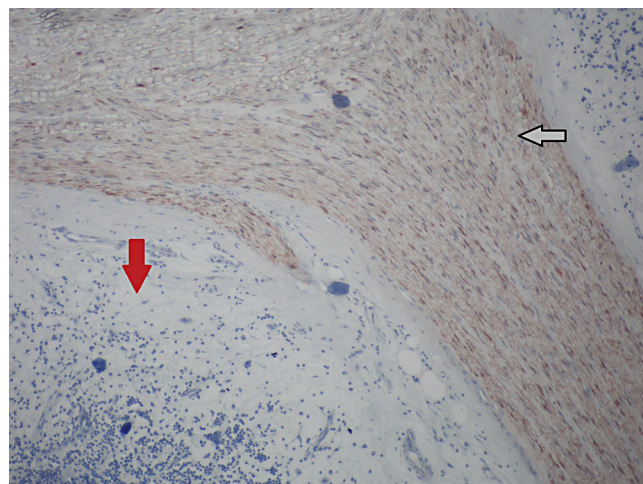
**Fig. 3.** microscopy of nerve sheath myxoma, red arrow indicate the tumoral tissue, white arrow indicates the peripheral nerve.

The patient’s symptoms disappeared immediately after the operation. The post-operative course was uneventful. One year after his operation, clinical follow-up and MRI showed no evidence of a recurrent lesion at 3rd, 6th, 9th and in the last follow up 1 year after surgery. Patient returned to his daily activities without pain and restriction.

### 3. Discussion

NSM is a rare tumor that most often occurs in the skin of the head, neck or upper limbs of younger patients. Like our dorsally paravertebral located case, some rare locations such as intracranial, spinal canal, trunk, lower limb and oral cavity were also reported. The reported ages of the patients range between 15 months and 84 years.<sup>2</sup> The previously reported cases had a peak incidence in the fourth decade of life, but are extremely rare in infancy.<sup>3</sup> It has a remarkable predilection for the female gender.<sup>4</sup>

These benign lesions were first described in 1969 by Harkin and Reed. Although, the tumor was later re-named by Gallager and Helwig as neurothekeoma, recent gene studies strongly supports that, nerve sheath myxomas and neurothekeomas are distinct neoplasms. Schwann-cell differentiation in the ultrastructural observation of NSM cells, suggests an origin from nerve sheath



**Fig. 4.** microscopy of nerve sheath myxoma, red arrow indicates the tumoral tissue, white arrow indicates peripheral nerve.

precursor cells. However, there are still some theories proposing a proliferation of other perineural cells, which brings controversies to the cell of origin.<sup>5</sup> There are some similar features of NSM with other neural tissue tumors, like schwannoma and neurofibroma. That seems the reason why various names such as pacinian neurofibroma, cutaneous lobular neurofibroma and perineural neurofibroma have been used for this lesion. These overlapping features are leading to difficulties in diagnosis.

Three variants of NSM were described based on histopathological evaluation. These subtypes include the myxoid type, the cellular type and the mixed type. The classical myxoid type is characterized by low cellularity and large amounts of myxoid matrix. The lesion usually bordered and diffusely positive for S-100. As in our case, the strong positivity of tumor cells for S-100, which is a well-established marker for Schwann cells and myelin sheath, favors the Schwann cell origin. The cellular types of NSM typically are not well circumscribed, and the mixed type includes varied cellularity within focal myxoid regions.<sup>6,7</sup> The differential diagnoses include schwannoma (also the malignant type), neurofibroma, neurilemmoma, leiomyoma, intramuscular myxoma and low-grade sarcoma.

The appropriate treatment of NSM is surgical excision. In our case, the close relation of the tumoral mass with pleura and adjacent vertebra-rib junction makes the total excision difficult to get with safe margins. After an intra-operative frozen section that revealed the benign nature of the lesion, a marginal excision was performed. An intra-operative consultation from thoracic surgery was also taken, in order not to penetrate the pleural membrane. Although a marginal excision was performed in our patient, no recurrence observed in the patients first year follow-up. Usually, NSM supposed to have a low recurrence rate after local recurrence, but some authors reported a recurrence rate in about 7% of patients.<sup>8,9</sup>

#### 4. Conclusion

Although the majority of reported cases are dermal tumors, NSM may also be located in the extremely rare locations. We aimed to increase the awareness about this disease, in order to avoid delays in diagnosis. We conclude that, the definitive treatment of NSM is surgical excision with safe margins even when it is possible.

#### Conflict of interest

None.

#### Funding

None.

#### Ethical approval

Written informed consent was obtained from the patient for publication of this case report and accompanying images.

#### Author contributions

Melih Malkoc contributed to study design. Tugrul Ormeci contributed to data collecting. Mert Keskinbora contributed to writing. Adem Yilmaz contributed to data collecting and analysis. Ozgur Korkmaz contributed to figure preparation. Canan Besleyici Tanik contributed to pathologic specimen analysis.

#### References

- Vij M, Jaiswal S, Agrawal V, Jaiswal A, Behari S. Nerve sheath myxoma (neurothekeoma) of cerebellopontine angle: case report of a rare tumor with brief review of literature. *Turk Neurosurg* 2013;**23**(1):113–6.
- Papadopoulos EJ, Cohen PR, Hebert AA. Neurothekeoma: report of a case in an infant and review of the literature. *J Am Acad Dermatol* 2004;**50**(January (1)):129–34.
- Fetsch JF, Laskin WB, Miettinen M. Nerve sheath myxoma: a clinicopathologic and immunohistochemical analysis of 57 morphologically distinctive, S-100 protein- and GFAP-positive, myxoid peripheral nerve sheath tumors with a predilection for the extremities and a high local recurrence rate. *Am J Surg Pathol* 2005;**29**(December (12)):1615–24.
- O'Rourke H, Meyers SP, Katzman PJ. Neurothekeoma in the upper extremity: magnetic resonance imaging and computed tomography findings. *J Comput Assist Tomogr* 2005;**29**(November–December (6)):847–50.
- Gallager RL, Helwig EB. Neurothekeoma – a benign cutaneous tumor of neural origin. *Am J Clin Pathol* 1980;**74**(December (6)):759–64.
- Lee D, Suh YL, Han J, Kim ES. Spinal nerve sheath myxoma (neurothekeoma). *Pathol Int* 2006;**56**(March (3)):144–9.
- Akhtar K, Zaheer S, Ray PS, Sherwani RK. Myxoid neurothekeoma: a rare soft tissue tumor of hand in a male toddler. *Niger J Surg* 2013 Jan;**19**(1):32–4.
- Hornick JL, Fletcher CD. Cellular neurothekeoma: detailed characterization in a series of 133 cases. *Am J Surg Pathol* 2007;**31**:329–40.
- Wollina U, Hansel G, Schönlebe J, Haroske G. Myxoid neurothekeoma – a painful case in a less common location. *Dermatol Online J* 2009;**15**(April (4)):3.

#### Open Access

This article is published Open Access at [sciedirect.com](http://sciedirect.com). It is distributed under the [IJSCR Supplemental terms and conditions](#), which permits unrestricted non commercial use, distribution, and reproduction in any medium, provided the original authors and source are credited.