



This work is licensed under a Creative Commons Attribution-NonCommercial 4.0 international license

Van Tıp Derg. 30(2):193-199,2023
DOI: 10.5505/vtd.2023.22556

Comparison of the Early Results of Preterm Infants who Underwent the Surgical Ligation of Patent Ductus Arteriosus with two Different Surgical Approaches

İki Farklı Cerrahi Yaklaşım ile Patent Duktus Arteriozus Ligasyonu Uygulanan Preterm İnanların Erken Dönem Sonuçlarının Karşılaştırılması

Fatih Özdemir¹, Onur Doyrgan², Handan Bezirganoğlu³, Mehmet Dedemoğlu⁴, Serhat Bahadır Genç⁵, Osman Uzundere⁶, Murat Sürücü⁷, Bedri Aldudak⁸

¹Dr.Siyami Ersek Thoracic And Cardiovascular Surgery Education Research Hospital, Department of Pediatric Cardiovascular Surgery, Istanbul, Türkiye

²Gazi Yaşargil Education Research Hospital, Department of Pediatric Cardiovascular Surgery, Diyarbakir, Türkiye

³Kanuni Education Research Hospital, Department of Neonatology, Trabzon, Türkiye

⁴Ümraniye Education Research Hospital, Department of Pediatric Cardiovascular Surgery, Istanbul, Türkiye

⁵Medipol University, Department of Pediatric Cardiovascular Surgery, Istanbul, Türkiye

⁶Gazi Yaşargil Education Research Hospital, Department of Anesthesiology and Reanimation, Diyarbakir, Türkiye

⁷Dr.Siyami Ersek Thoracic And Cardiovascular Surgery Education Research Hospital, Department of Pediatric Cardiology, Istanbul, Türkiye

⁸Gazi Yaşargil Education Research Hospital, Department of Pediatric Cardiology, Diyarbakir, Türkiye

Abstract

Introduction: Patent ductus arteriosus (PDA) is the most common congenital heart disease in preterm infants. Surgical ligation is still the gold standard technique, especially in low birth weight patients. To reduce surgical trauma and possible complications, the anterior mini-thoracotomy (AMT) technique has been defined. However, conventional lateral thoracotomy (LT) is still the method preferred by many centers today. In our study, we aimed to compare the early results of preterm infants who underwent PDA ligation with two different surgical techniques in a newly established center.

Materials and Methods: A total of 26 patients (12 males, 14 females; median gestational age at surgery 32 weeks [IQR: 29-37]) who underwent surgical PDA ligation in preterm infants between January 2018 and February 2020 were retrospectively analyzed. PDA closure was performed through the left anterior mini-thoracotomy approach in 15 of the patients and left lateral thoracotomy in 11 patients. The early outcomes of the two groups were compared.

Results: The median weight at operation was 1000 g (IQR: 720-1200) in AMT group and 1200 g (IQR: 1000 – 2800) in the LT group. The difference between weights at operation was found statistically significant. The operation time of the AMT group was found to be statistically significantly shorter.

Conclusion: Anterior mini-thoracotomy technique provides an effective surgical closure in the low-weight preterm infant at least lateral thoracotomy technique. Based on the results of our series and our opinion, it should be considered the first choice surgical method, especially in very low and extremely low-weight preterm infants.

Keywords: Patent ductus arteriosus; thoracotomy; preterm infants.

Özet

Amaç: Patent duktus arteriozus (PDA), prematür infantlarda en sık görülen doğumsal kalp hastalığıdır. Cerrahi ligasyon, özellikle düşük doğum ağırlıklı hastalarda hala altın standart tekniktir. Cerrahi travmayı ve olası komplikasyonları azaltmak için anterior mini torakotomi (AMT) tekniği tanımlanmıştır. Ancak konvansiyonel lateral torakotomi (LT) günümüzde hala daha fazla merkez tarafından tercih edilmektedir. Çalışmamızda yeni kurulan bir merkezde iki farklı cerrahi teknikle PDA ligasyonu uygulanan prematüre infantların erken dönem sonuçlarını karşılaştırmayı amaçladık.

Gereç ve Yöntem: Ocak 2018 ve Şubat 2020 tarihleri arasında cerrahi PDA ligasyonu uygulanan toplam 26 prematür infant (12 erkek, 14 kadın; ameliyatta medyan gebelik yaşı 32 hafta [IQR: 29-37]) retrospektif olarak incelendi. 15 hastaya sol anterior mini torakotomi ve 11 hastaya sol lateral torakotomi yaklaşımı ile PDA ligasyonu yapıldı. İki grubun erken dönem sonuçları karşılaştırıldı.

Bulgular: Operasyondaki medyan ağırlık AMT grubunda 1000 gr. (IQR: 720-1200) ve LT grubunda 1200 gr. (IQR: 1000 – 2800) idi. Ameliyat ağırlığı arasındaki fark istatistiksel olarak anlamlı bulundu. AMT grubunun ameliyat süresi istatistiksel olarak anlamlı olarak daha kısa bulundu.

Sonuç: Anterior mini torakotomi tekniği, düşük ağırlıklı prematüre bebeklerde en az lateral torakotomi tekniği kadar etkin cerrahi kapama sağlar. Serimiz sonuçlarına bakılarak özellikle çok düşük ve aşırı düşük kilolu prematür infantlarda anterior mini-torakotomi tekniğinin öncelikli olarak tercih edilmesi gerektiğini düşünmekteyiz.

Anahtar Kelimeler: Patent duktus arteriozus; torakotomi; preterm infant

*Corresponding Author: Fatih Özdemir Tıbbiye st. No: 13 Usküdar, Istanbul, Türkiye E-posta: fatih.ozdemir.83@gmail.com Orcid: Fatih Özdemir [0000-0002-0409-3588](https://orcid.org/0000-0002-0409-3588) Onur Doyrgan [0000-0002-4198-3504](https://orcid.org/0000-0002-4198-3504) Handan Bezirganoğlu [0000-0002-5720-7104](https://orcid.org/0000-0002-5720-7104) Mehmet Dedemoğlu [0000-0002-5532-4307](https://orcid.org/0000-0002-5532-4307) Serhat Bahadır Genç [0000-0003-2715-6972](https://orcid.org/0000-0003-2715-6972) Osman Uzundere [0000-0002-5968-4561](https://orcid.org/0000-0002-5968-4561) Murat Sürücü [0000-0002-7012-6579](https://orcid.org/0000-0002-7012-6579) Bedri Aldudak [0000-0002-7842-5012](https://orcid.org/0000-0002-7842-5012)

Introduction

The survival rates of low-birth-weight babies have increased thanks to current treatment options in neonatal intensive care units (NICU) and new invasive or non-invasive mechanical ventilation modalities. On the other hand, the rate of encountering some problems specific to prematurity is increasing as well (1). Patent ductus arteriosus (PDA) is the most common congenital heart disease in preterm infants (2). In literature, the incidence of PDA in preterm infants is found between 20-60 % and the frequency increases as birth weight decreases (3). Although percutaneous closure is applicable in preterm infants owing to developments in catheter technology, surgical ligation is still the gold standard technique, especially in low birth weight patients (4). To reduce surgical trauma and possible complications, the anterior mini-thoracotomy (AMT) technique has been defined and started to be applied in a few specific centers. However, conventional lateral thoracotomy (LT) is still the method preferred by many centers today. The practice and the preference of the surgeon are mostly decisive for which method to be applied. In our study, we aimed to compare the early results of preterm infants who underwent PDA ligation with two different surgical techniques in a newly established center.

Materials and Methods

This single-center, retrospective study was conducted between January 2018 and February 2020. A total of 26 patients (12 males, 14 females; median gestational age in operation: 32 weeks [IQR: 29-37]) underwent surgical PDA ligation in preterm infants. PDA closure was performed via the left anterior mini-thoracotomy approach in 15 of the patients and left lateral thoracotomy in 11 patients. The term infants who underwent surgical PDA ligation were excluded. The data, including patient characteristics, preoperative conditions (such as mechanical ventilation time, bronchopulmonary dysplasia, necrotizing enterocolitis) and echocardiographic findings, intraoperative findings (such as operation time, need of reintubation, bleeding, bradyarrhythmia, low arterial pressure, use of inotropic agents) and also postoperative outcomes (such as mechanical ventilation time, chylothorax, phrenic nerve paralysis, in-hospital mortality) were noted.

Surgical technique: In the operating room, a pulse oximeter and three-lead electrocardiography, noninvasive arterial pressure monitor were used for monitoring the vital parameters. Hypothermia

was prevented via both the radiant and bed heater during the operation. A peripherally inserted central catheter (PICC) or two peripheral catheters was considered adequate for the management of the operation. Adrenalin infusion was started as the first choice inotropic agent in case of hemodynamic instability. In the anterior mini-thoracotomy approach, the patient was placed in the supine position and approximately 2–3 cm incision was made through the second or third left anterior intercostal space. (Figure 1). The thymus gland was gently displaced medially. The left lung retracted laterally with very small wet gauze. Thus, the phrenic nerve was visualized and the incision was made 8-10 mm above it.

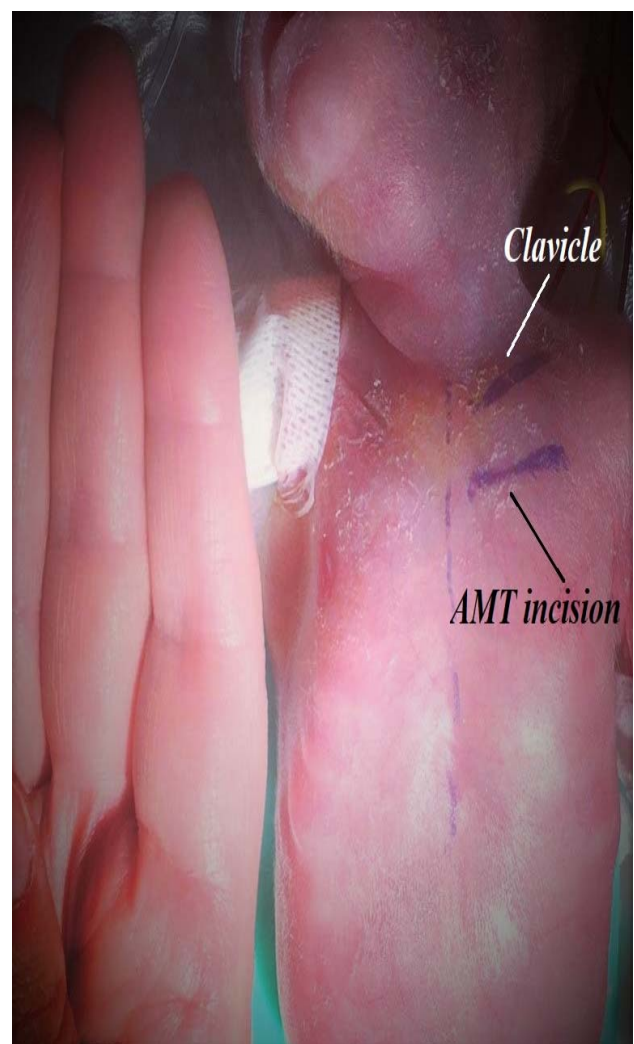


Figure 1: The incision line of the anterior mini-thoracotomy approach

Then, stay sutures were placed on the pericardium to reach the pulmonary artery and patent ductus arteriosus. (Figure 2).

Table 1: Patient Characteristics

Variables %, med (IQR)	AMT Group (n: 15)	LT Group (n:11)	All Patients (n:26)	P value
Gestational age (week)	25 (24-27)	28 (26-35)	26 (25-30)	0.06
Birth weight (g)	700 (650-980)	1450 (700-2450)	855 (688-1513)	0.10
Age at operation (GW)	31 (29-34)	34 (30-42)	32 (29-37)	0.13
Weight at operation (g)	1000 (720-1200)	1200 (1000-2840)	1140(960-1665)	0.03*
Gender				0.13
Female	10 (66.7)	4 (36.4)	14 (53.8)	
Male	5 (33.3)	7 (63.6)	12 (46.2)	
Type of Delivery				0.18
Vaginal	8 (53.3)	3 (27.3)	11 (42.3)	
Cesarean Section	7 (46.7)	8 (72.7)	15 (57.7)	
Maternal Antepartum Bleeding	3 (20.0)	0	3 (11.5)	0.06
Maternal Chorioamnionitis	3 (20.0)	1 (9.1)	4 (15.4)	0.44
Maternal Preeclampsia	2 (13.3)	1 (9.1)	3 (11.5)	0.74
Use of Antenatal Steroid	8 (53.3)	5 (45.5)	13 (50.0)	0.69
Maternal DM	2 (13.3)	0	2 (7.7)	0.13
Maternal Comorbidity	2 (13.3)	0	2 (7.7)	0.13

AMT: Anterior Mini-Thoracotomy **DM:** Diabetes Mellitus, **GW:** Gestational week, **IQR:** inter quartile range **LT:** Lateral Thoracotomy

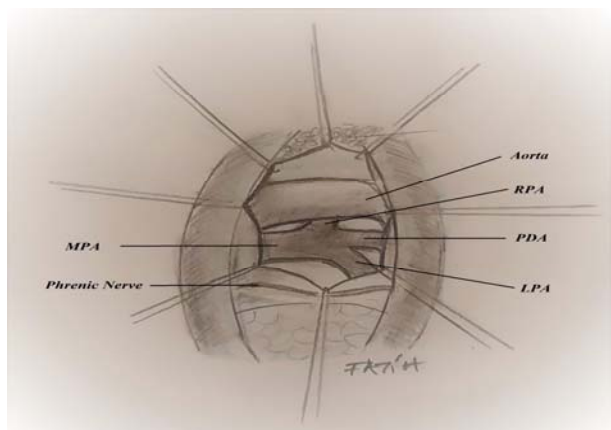


Figure 2: Figure of the anterior mini-thoracotomy approach -**LPA:** Left Pulmonary Artery, **MPA:** Main Pulmonary Artery, **PDA:** Patent Ductus Arteriosus, **RPA:** Right Pulmonary Artery

After exploration of the left and right pulmonary arteries and the limited dissection of the ductus arteriosus, a medium clip was gently placed on the PDA. After the deairing of the thorax, the muscles were sutured via degradable sutures. The skin and subcutaneous tissue were closed with interrupted 4.0 or 5.0 polypropylene mattress sutures without inserting a chest tube. In the lateral thoracotomy approach, the patient was placed in a lateral decubitus position and approximately 8-10 cm incision was made through the 3rd or 4th intercostal space. The left lung retracted medially, descending aorta and the PDA visualized, completely dissected, and looped with a 2.0 silk suture. Lastly, PDA was ligatured gently. Finally, a chest tube is inserted into the left thorax. The

muscles were sutured via degradable sutures. The skin and subcutaneous tissue were closed with interrupted 4/0 or 5.0 polypropylene mattress sutures. All patients were transferred to the neonatal intensive care unit after the operation and immediately had a chest X-ray to exclude possible pneumothorax.

Ethical consent: The study protocol was approved by the Diyarbakır Gai Yasargil Training and Research Hospital Ethics Committee (Date: 30/12/2022 No: 288). The study was conducted by the principles of the Declaration of Helsinki.

Statistical analysis: The SPSS (Statistical Package for the Social Sciences) software was used for data analysis. In descriptive analyses, categorical variables were presented as frequency (percentage) and numerical variables (because they were not normally distributed) were presented as median (interquartile range). For statistical comparison of group data, Chi-Square Fisher Extract test was used for categorical and Mann–Whitney U-test for numerical variables. A p-value of < 0.05 was considered statistically significant.

Results

The median gestational age was 26 weeks (IQR: 25-30) and the median age at the time of operation was 32 gestational weeks (IQR: 29-37) in all patients. The median weight at operation was 1000 g (IQR: 720-1200) in Anterior mini-thoracotomy group and 1200 g (IQR: 1000 – 2800) in the lateral thoracotomy group. The difference between weights at operation was

found statistically significant ($p: 0.03$). There was no significant difference between groups in terms of other patient characteristics and delivery-related

parameters. The patient characteristics are shown in table 1. The median APGAR score (5th min)

Table 2: Preoperative Condition and Echocardiographic findings

Variables %, med (IQ range)	AMT Group (n: 15)	LT Group (n:11)	All Patients (n:26)	P value
APGAR score (5 th minute)	4 (3-5)	5 (4-9)	4 (3-6)	0.06
Need of Oxygen	15 (100.0)	11 (100.0)	26 (100.0)	-
Need for Mechanical Ventilation	12 (80.0)	10 (90.9)	22 (84.6)	0.44
Mechanical Ventilation Time	31 (15-42)	34 (5-45)	32 (12-43)	0.88
Use of Inotrope	5 (33.3)	1 (9.1)	6 (23.1)	0.13
NEC	4 (26.7)	2 (18.2)	6 (23.1)	0.61
BPD	11 (73.3)	6 (54.5)	17 (65.4)	0.32
Intracranial Hemorrhage	6 (40.0)	1 (9.1)	7 (26.9)	0.07
Renal failure	2 (13.3)	0	2 (7.7)	0.13
Hepatic failure	2 (13.3)	0	2 (7.7)	0.13
Colostomy	3 (20.0)	0	3 (11.5)	0.06
Genetic Syndrome	1 (6.7)	4 (36.4)	5 (19.2)	0.06
Hydrops fetalis	0	1 (9.1)	1 (3.8)	0.18
Echocardiography				
PDA diameter (mm)	3.0 (2.6-3.5)	3.5 (2.5-6.0)	3.0 (2.5-3.6)	0.31
Heart Rate	148 (142-154)	160 (150-160)	152 (144-160)	0.11
EF %	70 (65-72)	66 (65-70)	68 (65-71)	0.47
LA/Ao Diameter	1.8 (1.6-1.9)	1.7 (1.5-4.7)	1.8 (1.6-1.9)	0.44
LVEDD	17 (15-17)	18 (15-22)	17 (15-19)	0.29

AMT: Anterior Mini-Thoracotomy, **Ao:** Aorta, **BPD:** Bronchopulmonary Displasia, **IQR:** inter quartile range **LA:** Left Atrium **LT:** Lateral Thoracotomy, **LVEDD:** Left Ventricle End Diastolic Diameter **NEC:** Necrotizing Enterocolitis

Table 3: Intraoperative Findings and Postoperative Outcomes

Variables %, med (IQ range)	AMT Group (n: 15)	LT Group (n:11)	All Patients (n:26)	P value
Intraoperative Findings				
Operation time (min)	55 (42-62)	70 (50-110)	55 (45-73)	0.03*
Low arterial pressure	3 (20.0)	0	3 (11.5)	0.06
Bradycardia	1 (6.7)	0	1 (3.8)	0.29
Bleeding	0	0	0	-
Re-intubation	3 (20.0)	1 (9.1)	4 (15.4)	0.44
Need of inotropic support	6 (40.0)	1 (9.1)	7 (26.9)	0.07
Operative Mortality	0	0	0	-
Postoperative Outcomes				
Residual PDA (operation day)	4 (26.7)	4 (36.4)	8 (30.8)	0.60
Residual PDA diameter (mm)	0 (0-1)	0 (0-1)	0 (0-1)	0.61
EF %	71 (70-74)	69 (65-70)	70 (68-73)	0.04*
Heart Rate	152 (140-160)	145 (142-156)	150 (141-159)	0.44
Mechanical Ventilation Time	20 (7-38)	28 (5-42)	22 (6-39)	0.61
Chylothorax	0	2 (18.2)	2 (7.7)	0.06
Bleeding	0	0	0	-
Phrenic Nerve Paralysis	1 (6.7)	0	1 (3.8)	0.29
Pneumothorax	0	2 (18.2)	2 (7.7)	0.06
Wound Infection	0	1 (9.1)	1 (3.8)	0.18
Sepsis	0	1 (9.1)	1 (3.8)	0.18
In-Hospital Mortality	1 (6.7)	3 (27.3)	4 (15.4)	0.15

AMT: Anterior Mini-Thoracotomy, **EF:** Ejection Fraction, **LT:** Lateral Thoracotomy, **PDA:** Patent Ductus Arteriosus

was 4 (IQR: 3-6) and 22 (84%) of the patients needed mechanical ventilator support preoperatively. There was no significant difference found between groups according to the preoperative conditions of the patients. The median diameter of PDA was 3.0 mm (IQR: 2.5–3.6) and the median ratio of diameters of the left atrium and aorta (LA/Ao) was 1.8 (IQR: 1.6-1.9). Medical closure treatment was tried at least once in all patients before the operation. Preoperative conditions and echocardiographic findings are listed in table 2. The median operation time was 55 minutes in the AMT group and 70 minutes in the LT group. The operation time of the AMT group was statistically significantly shorter than the LT group (p: 0.03). There was no difference found in terms of other intraoperative findings. No operative mortality was observed in either group. In postoperative echocardiography, residual PDA was detected in 8 (30.8%) of the patients which was hemodynamically insignificant. In the control echocardiography which was performed on the postoperative 7th day, all of the residual defects were seen as closed spontaneously. In-hospital mortality was observed in 4(15%) patients and all of the deaths were related to non-cardiac causes. Chylothorax was seen in 2 (8%), pneumothorax was seen in 2 (8%), and wound infection was seen in 1(4%) patients. These complications were observed only in the lateral thoracotomy group. Left phrenic nerve paralysis was seen in 1(4%) patient who was in the anterior mini-thoracotomy group. The intraoperative findings and postoperative outcomes are summarized in Table 3.

Discussion

In our study, although the weight of the anterior mini-thoracotomy group was lower, there was no difference in intraoperative and postoperative outcomes. The operation time was also found shorter in the AMT group. Hemodynamically insignificant residual PDA was detected in the echocardiography -which was performed immediately after the operation- in 8 patients and both groups, 4 in the AMT group and 4 in the LT group. The residual defects in both groups were seen as closed in the first week of controls. There was no operative mortality occurred in any patient. In-hospital mortality was seen in 4 patients and was associated with non-cardiac causes. In preterm infants, PDA is known to be associated with mortality, as well as bronchopulmonary dysplasia (BPD), necrotizing enterocolitis (NEC), pulmonary hypertension, pulmonary and intraventricular hemorrhage,

cerebral perfusion anomalies, retinopathy of prematurity, sepsis, and infective endocarditis (5-6). Conservative treatment options such as fluid restriction, cyclooxygenase inhibitors, diuretics, and positive pressure ventilation are the first-line treatment methods in hemodynamically significant PDA. (7-8). Even though the treatment strategy for low birth weight infants being controversial, surgical ligation is the most frequently used and life-saving strategy in this group when medical treatment methods fail (9-10). Although PDA closure seems to be possible in young infants with the developments in catheter technology; surgical PDA ligation is still the standard treatment method, especially in low-weight preterm infants, due to both difficulties in vascular access and long procedure times (5). In our series, chylothorax was seen in 2 (8%), pneumothorax was seen in 2 (8%), and wound infection was seen in 1(4%) patient and all of these complications were seen in the lateral thoracotomy group. As a surgical method, the lateral thoracotomy approach is preferred as a proven method in most centers. However, it is known that this method brings many surgical risks and serious surgical trauma, especially in low-weight preterm infants (11). There are some common complications of the lateral thoracotomy method mentioned in the literature such as bleeding, pneumothorax, lymphatic leakage, vocal cord paralysis, phrenic nerve injury and lung injury (12). In this technique, the surgical field is relatively deeper, and a fairly wide thoracotomy incision is required for good exposure. Although in our series these findings are not statistically significant, it can be speculated that the anterior mini-thoracotomy technique is advantageous in terms of such complications. The anterior mini-thoracotomy method provides close and direct exposure without requiring special surgical instruments. The application of the technique in the supine position allows the anesthetist to intubate the patient more easily in case of self-extubation that may occur during the operation. To enter the thoracic cavity, a small incision of approximately 2 cm to be made in the left 2nd or 3rd intercostal space will be sufficient. Especially in very low-weight patients, the second intercostal space promises pretty good exposure. In addition, while it is not possible to preserve the serratus anterior and latissimus dorsi muscles in the LT technique, the AMT technique allows these muscles to be preserved. The incision must be limited to close to the left internal mammary artery. There is no need for a thoracic retractor in this technique, since only nerve retractors, and pericardial stay sutures are sufficient for adequate

exploration. The apex of the left lung is retracted minimally laterally to expose the pericardium, phrenic nerve, and thymus. The thymus is scraped anteriorly and the pericardium is opened 8-10 mm anterior to the phrenic nerve. The main pulmonary artery is gently manipulated with vascular forceps or with a 7.0 polypropylene stay suture to explore the right and left pulmonary artery and PDA. Blunt dissection of lateral margins of the duct, without interfering with the posterior, eliminates the risk of recurrent nerve damage. After the right and left pulmonary artery origins are seen, PDA closure is done with a medium size clip. It may be unsafe to close a fragile PDA of a low-weight preterm infant with suture or ligation. During clipping, it should be kept in mind that the PDA tissue of the premature baby is very fragile, and should be avoided excessive pressure while clipping, despite the possibility of not complete closure of the PDA. In addition, it should be kept in mind that closing a fragile PDA of a low-weight preterm infant with sutures or ligation may be unsafe and cause complications. In the lateral thoracotomy method, as the patient's weight decreases, surgical exposure becomes more difficult, while in the anterior mini-thoracotomy method, as the weight decreases, the anterior-posterior distance of the chest is shorter, so the exposure becomes better. When the two groups were compared in our series, the operation time of the AMT group was found to be statistically significantly shorter. This reduces the risk of hypothermia during the operation and minimizes the negative effects of hypothermia. Insensible fluid loss is also minimized thanks to the mini-incision and short operation time. Considering that the risk of hypothermia increases especially in very low and extremely low-weight infants, the short operation time can be seen as the most important advantage of the AMT technique.

Study limitations: Despite being followed by the same neonatology and anesthesia team, the fact that operations were performed by different surgeons is an important limitation of the study. Its retrospective nature and relatively few numbers of cases are the other limitations of the study.

Conclusion

The anterior mini-thoracotomy technique provides an effective surgical closure in the low-weight preterm infant at least lateral thoracotomy technique. Based on the results of our series and our opinion, it should be considered as the first choice surgical method, especially in very low and extremely low weight preterm infants, with its easy

applicability, fewer complications, less surgical trauma, short operation time, and no need for special surgical material. Prospective randomized controlled studies with a large number of cases are needed to reach more definitive conclusions.

Ethical Consent: The study protocol was approved by the Diyarbakır Gazi Yasargil Training and Research Hospital Ethics Committee (Date: 30/12/2022 No: 288)

Conflict of Interest: The authors declare that there is no conflict of interest in this study.

Financial Support: The study was not financially supported.

Author Contributions: FÖ: Conception, Design, Materials, Data Collection, Supervision and Analysis, Literature Review, Writing, Critical Review. OD: Data Collection, Writing. HB: Data Collection, Critical Review. MD: Supervision and Analysis, SBG: Literature Review, Writing. OU: Writing MS: Literature Review, Writing. BA: Literature Review, Writing

Figures: The figures were illustrated by the author, Fatih Özdemir.

References

1. Hack M, Fanaroff AA. Outcomes of children of extremely low birthweight and gestational age in the 1990s. *Semin Neonatol* 2000;5(2):89-106.
2. Banioghal B. Physiological marker and surgical ligation of patent ductus arteriosus in neonates. *Afr J Paediatr Surg* 2016;13(3):109-113.
3. Fanaroff AA, Hack M, Walsh MC. The NICHD neonatal research network: changes in practice and outcomes during the first 15 years. *Semin Perinatol* 2003;27(4):281-287.
4. Karaci A.R, Sasmazel A, Turkay S, Aydemir N, Harmandar B, Erdem H, et al. Closure of a patent ductus arteriosus in pre-term neonates using a left anterior mini-thoracotomy. *J Card Surg* 2013;28(4):461-464.
5. Kim HS, Schechter MA, Manning PB, Eghtesady P, Balzer DT, Shahanavaz S, et al. Surgical Versus Percutaneous Closure of PDA in Preterm Infants: Procedural Charges and Outcomes. *J Surg Res* 2019;243:41-46.
6. Almeida-Jones M, Tang NY, Reddy A, Zahn E. Overview of transcatheter patent ductus arteriosus closure in preterm infants. *Congenital Heart Disease* 2019;14:60-64.
7. Stankowski T, Aboul-Hassan SS, Fritzsche D, Misterski M, Marczak J, Szymańska A, et al. Surgical closure of patent ductus

- arteriosus in extremely low birth weight infants weighing less than 750 grams. *Kardiol Pol* 2018; 76(4): 750-754,
8. Chock VY, Goel VV, Palma JP, Luh TM, Wang NA, Gaskari S, et al. Changing management of the patent ductus arteriosus: effect on neonatal outcomes and resource utilization. *Am J Perinatol* 2017; 34(10):990-995.
 9. Letshwiti JB, Semberova J, Pichova K, Dempsey EM, Franklin OM, Miletin J. A conservative treatment of patent ductus arteriosus in very low birth weight infants. *Early Hum Dev* 2017;104:45-49.
 10. Ngo S, Profit J, Gould JB, Lee HC. Trends in Patent Ductus Arteriosus Diagnosis and Management for Very Low Birth Weight Infants. *Pediatrics* 2017; 139(4): e20162390.
 11. Mandhan P, Brown S, Kukkady A, Samarakkody U. Surgical closure of the patent ductus arteriosus in preterm low-birthweight infants. *Congenit Heart Dis* 2009; 4:34-37.
 12. Malviya MN, Ohlsson A, Shah SS. Surgical versus medical treatment with cyclooxygenase inhibitors for symptomatic patent ductus arteriosus in preterm infants. *Cochrane Database Syst Rev* 2013; 2013(3): CD003951.