

# Examination of root canal morphology of teeth affected by Molar Incisor Hypomineralization (MIH): Frequency of accessory canals

Can Özükoç<sup>1</sup> 

<sup>1</sup> Istanbul Medipol University, Faculty of Dentistry, Department of Pediatric Dentistry, Istanbul, Turkey

## Correspondence:

Dr. Can ÖZÜKOÇ

Istanbul Medipol University, Department of Pediatric Dentistry, Istanbul, Turkey  
E-mail: ozukoccan@gmail.com

Received: 22 March 2020

Accepted: 2 September 2020

## Abstract

**Aim:** The aim of this study was to investigate the incidence of the presence of accessory canals in the root canal of the maxillary first molar teeth affected by Molar Incisor Hypomineralization (MIH).

**Methodology:** A total of 12 maxillary first molar teeth affected by MIH were obtained from 10 children aged from 10 to 12 years. The frequency of the presence of accessory canals was examined by using microcomputed tomography and 3D image software.

**Results:** Accessory canals were observed in the mesiobuccal (MB) canal in all of the samples with a statistically significant difference ( $p < 0.05$ ). It was observed that the accessory canals were mostly in communication with the canals in the MB root and that furcal accessory canals were found in 10 (83.33%) teeth. The incidence of accessory canals was 75% in the distobuccal (DB) canal, and it was 66.66% in the palatal (P) canal.

**Conclusion:** The incidence of the presence of accessory canals in DB and P canals and furcation is higher in the teeth affected by MIH.

**Keywords:** Accessory canal, Micro-computed tomography, molar Incisor hypomineralization, pediatric dentistry

## Access Online



DOI:

10.5577/intdentres.2021.vol11.no1.3

**How to cite this article:** Özükoç C. Examination of root canal morphology of teeth affected by Molar Incisor Hypomineralization (MIH): Frequency of accessory canals. Int Dent Res 2021;11(1):12-5. <https://doi.org/10.5577/intdentres.2021.vol11.no1.3>

## Introduction

Cleaning, remodeling, and filling of root canals is substantial for achieving successful endodontic treatment. The internal morphology of the root canal must be well known so that the abovementioned steps can be accomplished (1,2).

MIH is defined as morphological enamel defects caused by hypomineralization due to systemic causes (3). Clinically, MIH is observed in the occlusal surfaces of permanent molars and in one-third or more of the incisal surfaces of incisors. Causing changes in the

immunocytochemistry and vascularization, altered innervation, and an accumulation of immune cells; MIH causes a subclinical inflammation in the pulp (4). As a result of this inflammation, the occurrence of a certain degree of changes in the root canal morphology is inevitable in the early period. It is important that pediatric dentists should be aware of the potential of these morphological changes in advance as the presence of these morphological changes will affect the success of endodontic treatment. Of these changes, the primary one is the occurrence of the accessory canals in the root canal.

A review of the studies evaluating the root canal morphology shows that a variety of methods have been used in examining the morphology of the root canals; including decalcification, radiography, vertical and cross-sectional cutting, histological evaluation, stereomicroscopic analyses, surgical microscopy, plastic casts, scanning electron microscopy, cone beam computed tomography, and micro-computed tomography (5-8).

Micro-computed tomography is a noninvasive, nondestructive, and reproducible method and is nowadays considered the most accurate method for the investigation of the morphology of root canal systems combined with 3D software imaging (9,10). Therefore; in our study, we aimed to evaluate the incidence of the presence of accessory canals in the MIH-affected teeth by using microcomputed tomography.

## Materials and Methods

The study started after obtaining approval from the Medical Research Ethics Committee of Istanbul Medipol University (Approval no:562). A total of 12 maxillary first molar teeth affected by MIH were included in the study. These teeth were extracted due to various reasons (e.g., for orthodontic treatment, etc.) from 10 children in the age range from 10 to 12 years. Apex closure was found in the included teeth and these teeth had no signs of caries, root fractures or coronal or radicular resorption. Furthermore, there was not a history of undergoing endodontic treatment in these teeth. The collected maxillary first molar human teeth were stored in 5.25% sodium hypochlorite solution until they were studied. After the teeth were left for one hour in an ultrasonic bath containing 3% hydrogen peroxide, they were stored in 70% alcohol so that the overlying calculus and soft tissue like gingiva would be removed.

A total of 2000-2200 sections were taken from each tooth with a microtomography device set (mCT

40, Scanco Medical, Basel, Switzerland) to 120 mA at 70 kV power. The 3D images of the sections were obtained using the 3D image processing software (Photoshop CC, Adobe Inc, Boston, USA).

## Statistical analysis

The data were analyzed using computerized Statistical Package for Social Sciences (SPSS) 21 for windows (SPSS Inc, Chicago, IL, USA). ANOVA test was used to compare the means of multiple variables. An Independent-Samples T-test was used to compare the means of two variables, while the Chi-Square test was used when proportions were compared. The level of statistical significance was chosen at  $p < 0.05$ .

## Results

It was determined that all teeth examined had three roots, and there were two canals in the mesiobuccal (MB) root. While 5(41.66%) samples had two canals in the palatal (P) root, 4(33.33%) samples were found to have two canals in the distobuccal (DB) root. In the sections obtained from the 12 teeth examined by 3D microtomography, 10(83.33%) teeth were found to own a furcal accessory canal. It was determined that there was an accessory canal in the MB1 canal in all samples, and there was a statistically significant difference ( $p < 0.05$ ). Accessory canals were most commonly in communication with the canals in the MB root. It was found that MB1 and MB2 canals were connected in 7(58.33%) samples (Fig.1). The incidences of the presence of accessory canals in the DB and P canals were 75% and 66.66%, respectively. The number of accessory canals and the incidence of their presence in canals are presented in Table 1.

Table 1. Accessory Canals and their places.

Accessory	MB1	MB2	Connecting	DB	p
0	0 0%	4 33.33%	5 41.66%	3 25%	4 33.33%
1	*8 66.66%	7 58.33%	2 16.66%	5 41.66%	5 41.66%
2	4 33.33%	1 8.33%	5 41.66%	4 33.33%	3 25%

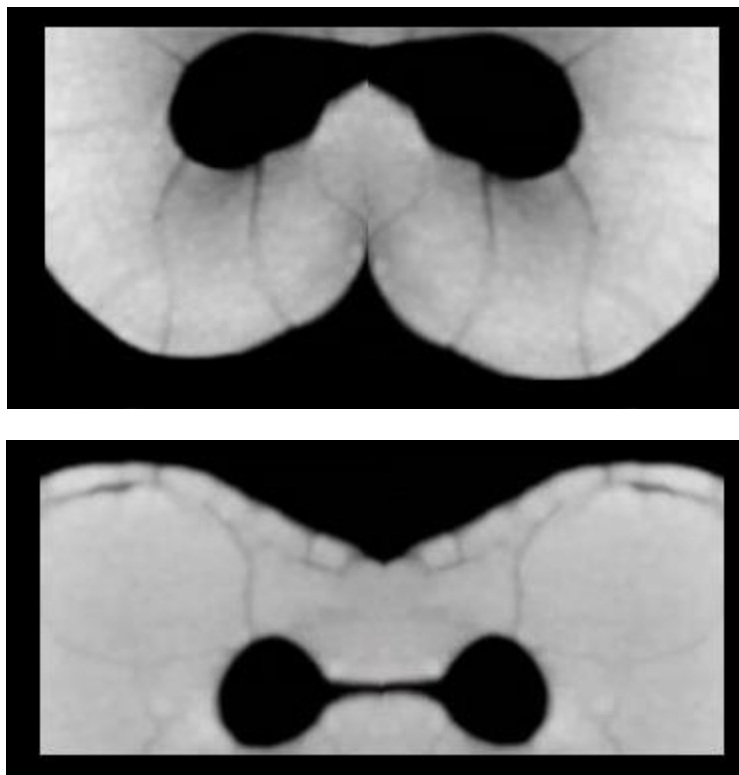


Figure 1. Accessory canals in mesiobuccal roots

## Discussion

MIH results in physical and chemical alterations in the structure of affected teeth. These alterations vary depending on the severity of the impact on the defect. Although MIH is caused by enamel defects, it is not only associated with abnormalities in the dental enamel but also coexists with immunohistochemical changes, altered innervation and vascularization, and accumulation of immune cells in the dentin-pulp complex, as indicated by several studies (4). In the literature, there are no studies evaluating the anomalies found in the root canals of the teeth affected by MIH.

The maxillary first molar tooth is the largest space-occupying tooth in the mouth, and it owns the most complex root canal anatomy as well (2). It was decided to conduct this study on the maxillary first molar teeth as they were the most frequently studied and the most commonly treated teeth associated with the highest treatment failure rates.

Seltzer et al. (11) defined the lateral canals as the ones located approximately vertical to the main root canal and the accessory canals as the ones branching from the main root canal, which is most commonly located in the apical region of the tooth. The accessory canals are usually more numerous in young teeth. Some of the accessory canals can be obliterated with excess dentin or cement at older ages, decreasing in number. Accessory canals can be found at all levels in the root, and they contain fibrous tissue (12). However, the vast

majority of them are located in the apical third of the root. One of the most common areas where they are found out to be present is the furcation of molar teeth (12). These canals allow the exchange of metabolic and degradation products between the pulp and periodontal tissues. The presence of deep periodontal pockets may cause inflammation or necrosis of the pulp. Conversely, degradation products of inflammatory pulp lesions can affect periodontal tissues through these canals. Many researchers (13,14) have observed the presence of accessory canals in the furcation area of molar teeth. In this study, furcal accessory canals were found at a rate of 83.33%, while Haznedaroglu et al. (14) and Vertucci and Anthony (15) found them at rates of 24% and 36%, respectively, in the maxillary first molar teeth. It may be suggested that a high incidence for the presence of furcal accessory canals has been observed in this present study because only young teeth affected by MIH were included for examination, with MIH resulting in immunocytochemical changes, altered innervation and vascularization, and the accumulation of immune cells in the dentin-pulp complex (4).

Fewer accessory canals are seen in the MB1 canal compared to the MB2 canal (16). Similar to Marroquín et al. (16) study, this study found a higher number of accessory canals in the MB1 canal. A review of the studies investigating the frequency of the presence of accessory canals showed that Marroquín et al. (16) found their frequency as 30.8% and 5.6% in the MB1 and MB2 canals, respectively that Kim et al. (17) and

Vertucci (2) found them at frequencies of 50% and 85%, respectively. Although the results in the literature (2,17) are significantly variable, they are in line with the results of this present study.

Somma et al. (18) conducted a study investigating the micro-computed tomographic sections, and they reported that MB canals were connected via accessory canals. Marroquín et al. found that these canals were connected at a rate of 2.9%. In our study, we found that they were connected in 7 (58.33%) samples.

The frequency of the presence of accessory canals in the DB and P canals of the maxillary first molar teeth is reported in the range from 11% to 15% (2,16,17). In this present study, the accessory canals were present in the DB and P canals at rates of 75% and 66.66%, respectively. The occurrence of these high rates is suggested to be due to increased vascular activity in the MIH-affected teeth and the failure of the accessory canals to be obliterated by dentine.

## Conclusions

In the MIH-affected teeth, the absence of narrowing in the root canals due to blood vessel dilatation resulting from the accumulated cells following subclinical pulp inflammation and the failure of accessory canals to be obliterated by dentin produced by osteoblasts leads to the more common presence of accessory canals in the furcation and the DB and P canals.

**Acknowledgments:** The authors wish to thank those who helped data collection at TETLab, Istanbul University, Istanbul, Turkey.

**Ethical Approval:** Ethics committee approval was received for this study from Istanbul Medipol University University Medical Research Ethics Committee, Ethics Committee in accordance with the World Medical Association Declaration of Helsinki, with the approval number: 2019/562.

**Peer-review:** Externally peer-reviewed.

**Author Contributions:** Conception - C.Ö.; Design - C.Ö.; Supervision - C.Ö.; Materials - C.Ö.; Data Collection and/or Processing - C.Ö.; Analysis and/or Interpretation - C.Ö.; Literature Review - C.Ö.; Writer - C.Ö.; Critical Review - C.Ö.;

**Conflict of Interest:** No conflict of interest was declared by the authors.

**Financial Disclosure:** The authors declared that this study has received no financial support.

## References

- Weine FS, Healey HJ, Gerstein H, Evanson L. Canal configuration in the mesiobuccal root of the maxillary first molar and its endodontic significance. *Oral Surg Oral Med Oral Pathol* 1969;28:419-25. ([Crossref](#))
- Vertucci FJ. Root canal anatomy of the human permanent teeth. *Oral Surg Oral Med Oral Pathol* 1984;58:589-99. ([Crossref](#))
- Weerheijm KL, Duggal M, Mejàre I, Papagiannoulis L, Koch G, Martens LC, Hallonsten AL. Judgement criteria for molar incisor hypomineralisation (MIH) in epidemiologic studies: A summary of the European meeting on MIH held in Athens, 2003. *Eur J Paediatr Dent* 2003;4:110-113.
- Rodd HD, Boissonade FM, Day PF. Pulpal status of hypomineralized permanent molars. *Pediatr Dent* 2007;29:514-520.
- De Deus QD. Frequency, location, and direction of the lateral, secondary, and accessory canals. *J Endod* 1975;1:361-366. ([Crossref](#))
- Kato A, Ohno N. Construction of three-dimensional tooth model by micro-computed tomography and application for data sharing. *Clin Oral Investig* 2009;13:43-46. ([Crossref](#))
- Tekin S, Adıgüzel Ö, Cangül S. An evaluation using micro-CT data of the stress formed in the crown and periodontal tissues from the use of PEEK post and PEEK crown: A 3D finite element analysis study. *Int Dent Res* 2018;8(3):144-50. ([Crossref](#))
- Baratto Filho F, Zaitter S, Haragushiku GA, Campos EA, Abuabara A, Correr GM. Analysis of the internal anatomy of maxillary first molars by using different methods. *J Endod* 2009;35:337-342. ([Crossref](#))
- Rhodes JS, Ford TR, Lynch JA. Micro-computed tomography: a new tool for experimental endodontology. *Int Endod J* 1999;32:165-70. ([Crossref](#))
- Keles A, Keskin C. Quantitative analysis of the anatomy of mesial roots of mandibular first molars with Vertucci type I root canal configuration by means of micro-computed tomography. *Int Dent Res* 2020;10(1):17-21. ([Crossref](#))
- Setzer FC, Boyer KR, Jeppson JR, Karabucak B, Kim S (2011) Long-term prognosis of endodontically treated teeth: a retrospective analysis of preoperative factors in molars. *Journal of Endodontics* 37, 21-5. ([Crossref](#))
- Bjørndal L, Carlsen O, Thuesen G, Darvann T, Kreiborg S (1999) External and internal macromorphology in 3Dreconstructed maxillary molars using computerized X-raymicrotomography. *International Endodontic Journal* 32, 3-9 ([Crossref](#))
- Goldberg F, Massone EJ, Soares I, Bittencourt AZ. Accessory orifices: anatomical relationship between the pulp chamber floor and the furcation. *J Endod.* 1987;4: 176-81. ([Crossref](#))
- Haznedaroğlu F, Ersev H, Odabaşı H, Yetkin G, Batur B, Açı S, İşsever H. Incidence of patent furcal accessory canals in permanent molars of a Turkish population. *Int Endod J.*2003;8: 515-519. ([Crossref](#))
- Vertucci FJ, Anthony RL. A scanning electron microscopic investigation of accessory foramina in the furcation and pulp chamber floor of molar teeth. *Oral Surg Oral Med Oral Pathol.*1986; 3: 319-326. ([Crossref](#))
- Marroquín BB, PhD, Paqué F, Willershausen B, Wolf TG (2015). Root Canal Morphology and Configuration of 179 Maxillary First Molars by Means of Micro-Computed Tomography. An Ex Vivo-Study. *Journal of Endodontics*, 41(12):2008-2013. DOI: <https://doi.org/10.1016/j.joen.2015.09.007> ([Crossref](#))
- Kim Y, Lee S-J, Woo J. Morphology of maxillary first and second molars analyzed by cone-beam computed tomography in a Korean population: variations in the number of roots and canals and the incidence of fusion. *J Endod* 2012;38:1063-8. ([Crossref](#))
- Somma F, Leoni D, Plotino G, Grande NM, Plasschaert A. Root canal morphology of the mesiobuccal root of maxillary first molars: a micro-computed tomographic analysis. *Int Endod J* 2009;42:165-74. ([Crossref](#))