

Melih MALKOÇ
Özgür KORKMAZ
Adnan KARA
İsmail OLTULU
Ali ŞEKER

Correspondance

Melih MALKOÇ
İstanbul Medipol University, Faculty of Medicine,
Department of Orthopedics and Traumatology, İSTANBUL

Phone: 0212 460 77 77
e-mail: memalkoc@yahoo.com

Received: 11/12/2014

Accepted: 26/12/2014

İstanbul Medipol University, Faculty of Medicine,
Department of Orthopedics and Traumatology, İSTANBUL



RESEARCH

RESULTS OF COMBINED CHEVRON OSTEOTOMY AND FIRST PROXIMAL PHALANGEAL CLOSE-UP OSTEOTOMY WITHOUT SOFT TISSUE PROCEDURE WITH SEVERE HALLUX VALGUS IN PATIENTS AGED OVER 60 YEARS OF AGE

ABSTRACT

Introduction: Hallux valgus is associated with a medial deviation of the first metatarsal and subluxation or dislocation of the first metatarsophalangeal joint. This deformity is one of the most common chronic foot complaints, with a prevalence of up to 35.7% in elderly patients. In the present study, we examined 23 feet of 15 patients with severe hallux valgus deformity between April 2008 and December 2013.

Materials and Method: The inclusion criteria were age and severe hallux valgus angle and intermetatarsal angle. Patients who had any other foot deformities, were younger than 60 years, were subjected to inadequate follow-up, had moderate and mild hallux valgus angle and intermetatarsal angle, or underwent any type of prior surgery were excluded from the study.

Results: The mean preoperative hallux valgus angle and intermetatarsal angle were 46.86° (range 45°–51°) and 17.6° (range 13°–21°), respectively. The postoperative corrections achieved by chevron osteotomy and first proximal phalangeal osteotomy for hallux valgus angle and intermetatarsal angle were 21.6° (range 19°–24°) and 12.6° (range 11°–14°), respectively ($p < 0.05$). The mean American Orthopaedic Foot and Ankle Society hallux score improved from 35.8 (range 31–38) to 89.8 (range 87–94) ($p < 0.05$).

Conclusion: Although most studies recommend chevron osteotomy only for patients younger than 50 years of age, we did not impose an age limit in our study.

Key Words: Hallux Valgus; Metatarsophalangeal Joint; Osteotomy.



ARAŞTIRMA

ALTMİŞ YAŞ ÜSTÜ İLERİ HALLUKS VALGUS DEFORMİTELİ HASTALARDA YUMUŞAK DOKU CERRAHİSİ YAPILMADAN KOMBİNE CHEVRON VE BİRİNCİ PARMAK PROKSİMAL FALANKS KAPALI KAMA OSTEOTOMİ SONUÇLARI

Öz

Giriş: Halluks valgus 1. metatarsın medial deviasyonu sonucunda birinci metatarsofalangeal eklemden sublüksasyonu veya dislokasyonu olarak tanımlanır. Yaşlı hastalarda kronik ayak sorunları içerisinde %35,7'nin prevalans gösteren en sık görülen deformitedir. Bu çalışmada Nisan 2008 Aralık 2013 tarihleri arasında ileri halluks valgus deformitesi olan 15 hasta (23 ayak) değerlendirilmiştir.

Gereç ve Yöntem: Çalışmaya dahil edilme kriterleri yaş, ileri halluks valgus açısı ve ileri intermetatarsal açıdır. Altmış yaşın altında olan, takipleri olmayan, diğer ayak deformitesi olan, orta derece halluks valgus açısı ile intermetatarsal açı olan ve ayak cerrahi hikayesi olan hastalar çalışmaya dahil edilmemiştir.

Bulgular: Ameliyat öncesi hastaların ortalama halluks valgus açısı ve intermetatarsal açıları sırasıyla 46,86° (45°-51°) ve 17,6° (13°-21°) olarak belirlenmiştir. Chevron ve 1 parmak proksimal falanks düzeltici osteotomileri sonrasında ortalama halluks valgus açısı ve intermetatarsal açı sırasıyla 21,6° (19°-24°) ve 12,6° (11°-14°) olarak belirlenmiştir. ($p < 0,05$). Ortalama Amerikan Ortopedi Ayak ve Ayakbileği skoru 35,8 (31-38) değerinden 89,8 (87-94) değerine yükselmiştir ($p < 0,05$).

Sonuç: Çoğu çalışmada Chevron osteotomisi 50 yaş ve altı olan hastalarda önerilmesine rağmen, çalışmamızda yaş sınırlaması yapılmamıştır.

Anahtar Sözcükler: Halluks Valgus, Metatarsofalangeal Eklem, Osteotomi.



INTRODUCTION

Hallux valgus is associated with a medial deviation of the first metatarsal and subluxation or dislocation of the first metatarsophalangeal joint (MTPJ). Pronation of the big toe and lateral shift of the sesamoid complex occur in the later stages of hallux valgus. This foot pathology can be idiopathic or secondary to rheumatoid arthritis (RA), poorly fitted shoes, or connective tissue and neuromuscular pathologies. Hallux valgus is one of the most common chronic foot complaints, with a prevalence of up to 35.7% in the elderly (1).

Conservative treatment using orthotics is usually ineffective, and only surgery leads to satisfactory results. Most surgical procedures for hallux valgus reconstruction require a combination of soft tissue procedures and several types of distal or proximal osteotomies with or without first proximal phalangeal osteotomy.

Surgical treatment of this deformity involves the correction of the alignment with an appropriately chosen metatarsal osteotomy (proximal or distal) and soft tissue releases. In general, distal osteotomies of the first metatarsal are recommended for mild to moderate hallux valgus deformities, whereas more proximal metatarsal osteotomies are suggested for severe deformities. The distal chevron procedure involves performing a V-shaped osteotomy of the distal first metatarsal used to treat mild to moderate hallux valgus deformities. This procedure was first described by Corless in 1976 (2). Lateralization and fixation of the distal fragment result in the narrowing of the forefoot. Thus, distal chevron osteotomy is frequently combined with additional osteotomies and soft tissue procedures to extend its indications to more severe deformities (3). Akin (4) suggested a medial wedge osteotomy of the proximal phalanx of the great toe in combination with a chevron procedure, named as chevron–Akin double osteotomy by Mitchell and Baxter (5). These authors also suggested that chevron–Akin double osteotomy may present several advantages over a single distal chevron procedure.

Akin osteotomy, first described in 1925, involves a medial closing wedge osteotomy and an excision of the medial protruding condylar eminence of the proximal phalanx (6). This procedure has been used to correct residual deformities of the great toe such as valgus deformities, axial rotations, or excessive length, either in isolation or in combination with other procedures. It is also often performed as a final step during the treatment of hallux valgus. In this case, it is used to create a medial deviation of the hallux by repositioning the flexor hallucis longus toward the midline, which can be effective for

achieving biomechanical and cosmetic improvements associated with residual hallux valgus deformity (7).

Despite its proven success for treating this type of deformity, chevron osteotomy has been consistently contraindicated for patients older than 50 years. This may be related to the high proportion of patients older than 50 years who report pain and stiffness in MTPJ, leading to decreased overall patient satisfaction in comparison with that in patients younger than this age (8,9).

The present study aimed to retrospectively assess the outcome of chevron osteotomy combined with proximal phalangeal osteotomy used to correct severe hallux valgus deformity in elderly patients.

MATERIALS AND METHOD

This retrospective study was approved by our institution's ethical board, and informed consent was obtained from all patients.

In the present study, we evaluated 23 feet from a total of 15 patients with severe hallux valgus deformity, between April 2008 and December 2013. The inclusion criteria were age and severe hallux valgus angle (HVA) and intermetatarsal angle (IMA). Patients who had any other foot deformities, were younger than 60, were subjected to inadequate follow-up, had moderate and mild HVA and IMA, or underwent any type of prior surgery were excluded from the study. All the measurements were performed using a picture archiving and communication system (IntelliSpace PACS DCX, Release R3.1 L1 SP2 Philips).

The mean age of the patients was 59.8 years for females (range 37–72 years) and 63 years for males (range 62–64 years). The mean follow-up time was 48.6 months (range 35–78 months). Standard weight bearing dorsoplantar and lateral X-ray radiographs (Figures 1 and 2) were obtained preoperatively and at 2, 6, and 12 weeks after the operation. These images were subsequently used to evaluate HVA and IMA (Figures 3 and 4).

HVA was measured as the angle between the intersection of the bisection of the first metatarsal and the proximal phalanx. Normal HVA values range between 10° and 15° (1). IMA was measured as the angle formed by the intersection of the bisection of the first and second metatarsals. Normal IMA values range between 7° and 9°.

All the patients completed an American Orthopaedic Foot and Ankle Society (AOFAS) hallux score questionnaire during the preoperative assessment and during the final follow-up

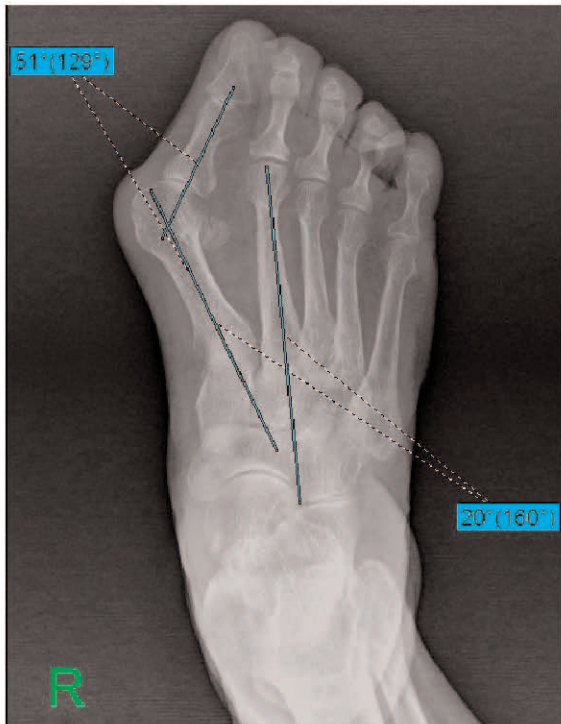


Figure 1— Preoperative antero-posterior weight-bearing x-ray radiography of a 62-year-old woman. Hallux valgus and intermetatarsal angles were 51° and 20°, respectively.

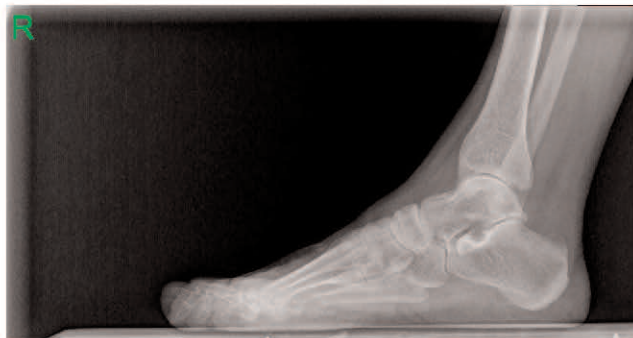

Figure 2— Preoperative lateral weight-bearing x-ray radiography of a 62-year-old woman.

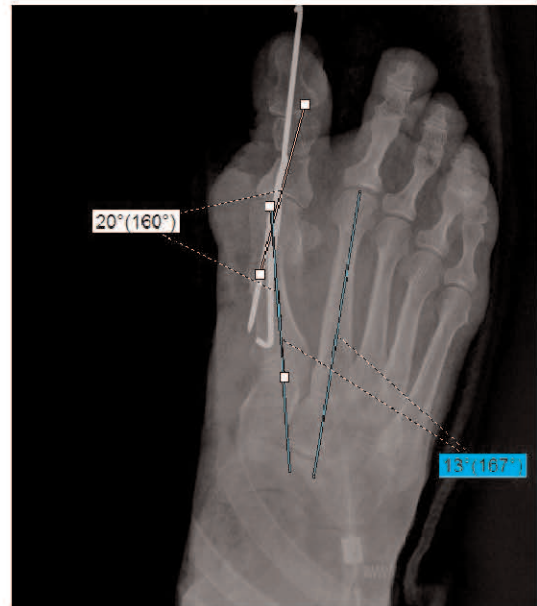

Figure 3— Postoperative antero-posterior x-ray radiography of the same patient. The hallux valgus angle improved by 20° and intermetatarsal angle improved by 13°.

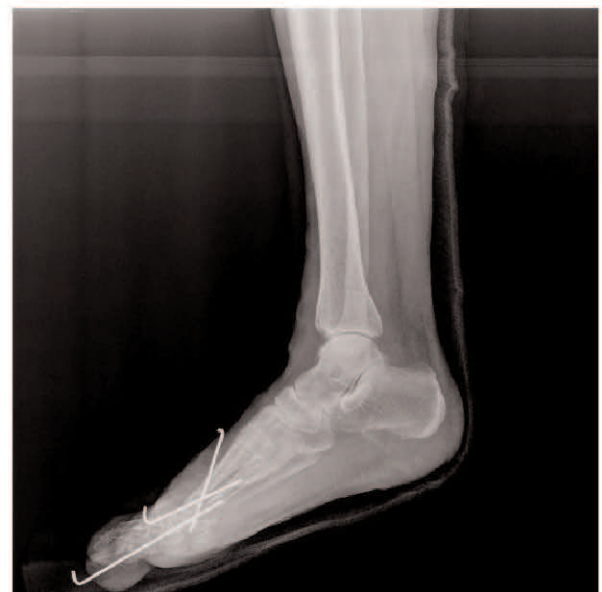

Figure 4— Postoperative lateral x-ray radiography of the same patient.

session. This scoring system consists of three main categories, namely pain, function, and alignment, scored from 0 to 100, with higher scores indicating better functions (10). The pain and function sections were answered by the patient.

All surgical procedures involved a 6-cm longitudinal incision centered in the first carpometacarpal joint. The capsula was then detached from the metacarp using a reverse U-shape and moved proximally. Subsequently, the bunion was



osteotomised using a 5-mm electrical saw to perform a V-shaped 60° chevron osteotomy of the distal metatarsal. This osteotomy enabled the first metatarsal head to be laterally shifted to correct the abnormal shape caused by a long standing valgus drift. The osteotomy side was fixed using two cross-pinned Kirschner wires. The detached capsule was strongly sutured to the metatarsal to maintain the varus alignment. No intraoperative complications, infections, or fractures were recorded. All surgeries were performed by the same surgeon to avoid surgeon bias.

Partial heel weightbearing using a postoperative shoe was allowed for the first week after surgery. Foot-flat weightbearing to tolerance was allowed between 2 and 6 weeks. After the sixth week, all the patients were advanced to regular shoe wear. The sutures were removed and the pin was pulled on the second week, and each patient began to use a daily elastic compression wrap and a gauze pad between toes one and two.

Preoperative and follow-up postoperative data were compared using a paired Student's t-test at the 95% significance level ($p < 0.05$).

RESULTS

The mean preoperative HVA and IMA were 46.86° (range 45°–51°) and 17.6° (range 13°–21°), respectively. Combining chevron osteotomy and first proximal phalangeal osteotomy for HVA and IMA resulted in a postoperative correction of 21.6° (range between 19°–24°) and 12.6° (range between 11°–14°), respectively ($p < 0.05$).

The mean AOFAS hallux score significantly improved from 35.8 (range 31–38) to 89.8 (range 87–94), ($p < 0.05$).

Four patients presented with superficial infections after surgery, which were treated with appropriate antibiotic administration. Nonunion, delayed union, or malunion of the osteotomy site was not recorded. No noticeable great toe stiffness was observed.

DISCUSSION

Mobilizing soft tissues during lateral release could potentially lead to damage to the articular surface and disturbance of the blood supply (11). In fact, the most serious complication that could appear following chevron osteotomy is avascular necrosis of the first metatarsal head. The blood supply to the first metatarsal head derives from a nutrient artery in the metatarsal diaphysis and from a second group of vessels entering the metatarsus around the capsule of the first

metatarsophalangeal joint (12). Mann (9) and Wilkinson et al. (13) described two types of avascular necrosis caused by osteotomy of the distal end of the metatarsal, partial, and whole-head avascular necrosis. None of the subjects presented with avascular necrosis that was identified clinically or radiologically. These results are similar to those reported by Johnson et al. (14) and Pochatko et al. (15). Compared with chevron osteotomy, chevron–Akin osteotomy may have the advantage of being able to eliminate the need for a lateral capsular release. On the other hand, it has been suggested that adductor tenotomy together with chevron osteotomy devascularizes the metatarsal head and leads to osteonecrosis (16).

After analyzing a series of parameters proposed to evaluate the surgical outcomes of the treatment of hallux valgus (9), previous studies have suggested that chevron osteotomy should only be considered for patients younger than 50 years (9) with an MTP angle $< 30^\circ$, IM angle $< 15^\circ$, and no degenerative changes in MTPJ (9,17). In addition to isolated chevron osteotomy, combined techniques performed with other operative measures are commonly used. Osteotomies of the first ray have been proposed in addition to other soft tissue procedures addressing the lateral capsular complex or the adductor tendon (15,18). Mitchell and Baxter (4) described the procedures to perform Akin osteotomy of the proximal phalanx for treating symptomatic hallux valgus, which may possibly lead to improved functional and radiological results. The authors reported the first results of 24 chevron–Akin double osteotomies performed to correct hallux valgus with a mean follow-up period of 29 months. These patients showed a 95% patient satisfaction with regard to pain and appearance of the foot. Furthermore, Mitchell and Baxter (4) presented excellent radiological results and a low complication rate in similar settings. These authors suggested that combined chevron–Akin osteotomy provides better results than chevron osteotomy alone. Tollison and Baxter (19) also reported good results after a follow-up period of 4 years and 6 months for patients with a mean age of 63 years who underwent chevron–Akin double osteotomy. Our results showed a statistically significant difference between preoperative and postoperative AOFAS scores, radiologic evaluation of HVA, and IMA ($p \leq 0.05$). However, in this case, chevron–Akin osteotomy was not restricted to younger patients.

Fixation using Kirschner wires can be inserted without disrupting the delicately corrected position, which is an advantage over other methods; however, this has been highlighted as an insecure method of stabilization (20). Stability can be enhanced by adding transverse Kirschner wires to the



longitudinal Kirschner wires or using multiple longitudinal Kirschner wires. In all these cases, irritation of the soft tissue surrounding the wires is frequent and hardware removal is often necessary (21,22). In our study, the osteotomy side was fixed using two cross-pinned Kirschner wires, and the pins were removed after 2 weeks. No cases of nonunion or instability were reported in our series.

With regard to postoperative treatment, most authors allow full weightbearing using a stiff-soled shoe or a cast during the first 2 weeks after surgery, while others only allow heel weightbearing throughout the same period (23,24). The patients in our study were allowed partial heel weightbearing using a postoperative shoe for the first week after surgery and foot-flat weightbearing to tolerance between two and six weeks. We did not detect any loss of correction or pain during the follow-up period.

Stiffness and pain on the first MTPJ can occur after bunion procedures. Mann and Coughlin (9) believed that the incidence is higher after a chevron procedure in patients older than 50 years; however, our results did not show a significant increase in stiffness or pain.

Previous studies have also suggested that AOFAS scores may be inadequate to assess clinical outcomes after surgical correction of hallux valgus (11,25). The major limitations of our study are a short follow-up period and the fact that this is a retrospective study designed to evaluate AOFAS scores associated with chevron-Akin osteotomy results.

In conclusion, most authors recommend chevron osteotomy only for patients younger than 50 years; however, we did not impose an age limit in our study. We only reviewed patients older than 60 years and found no evidence to support the age limitation currently placed on chevron procedures. Chevron osteotomy is the main procedure used to correct hallux valgus and metatarsus primus varus. Akin osteotomy helps align and derotate the toe without relying on extreme capsular imbrication. Thus, this procedure may help reduce the pressure on MTPJ, thereby reducing the incidence of postoperative pain and stiffness.

REFERENCES

1. Nix S, Smith M, Vicenzino B. Prevalence of hallux valgus in the general population: a systematic review and meta-analysis. *J Foot Ankle Res* 2010;3(1):21. (PMID:20868524).
2. Corless JR. A modification of the Mitchell procedure. *J Bone Joint Surg* 1976;55:138.
3. Schneider W, Aigner N, Pinggera O, Knahr K. Chevron osteotomy in hallux valgus. Ten-year results of 112 cases. *J Bone Joint Surg Br* 2004;86:1016–20. (PMID:15446530).
4. Akin O. The treatment of hallux valgus: a new operative procedure and its results. *Medical Sentinel* 1925;33:678-79.
5. Mitchell LA, Baxter DE. A Chevron-Akin double osteotomy for correction of moderate hallux valgus. *Foot Ankle* 1991;12:7–14. (PMID:1959838).
6. Brahms MA. Hallux valgus?the Akin procedure. *Clin Orthop Relat Res* 1981;157:47-9. (PMID:7249462).
7. Barouk LS, Barouk P, Baudet B, Touleec E. The great toe proximal phalanx osteotomy: the final step of the bunionectomy. *Foot Ankle Clin* 2005;10(1):141-55. (PMID:15831263).
8. Hatstrup SJ, Johnson KA. Chevron osteotomy: analysis of factors in patients' dissatisfaction. *Foot Ankle* 1985;5(6):327–32. (PMID:4018677).
9. Mann RA, Coughlin MJ. Adult hallux valgus. In: Mann RA, Coughlin MJ (Eds) *Surgery of the Foot and Ankle* (6th ed) St. Louis, MO: Mosby Year Book 1993, pp 167-296.
10. Baumhauer JF, Nawoczenski DA, DiGiovanni BF, Wilding GE. Reliability and validity of the American Orthopaedic Foot and Ankle Society Clinical Rating Scale: a pilot study for the hallux and lesser toes. *Foot Ankle Int* 2006;27:1014-9. (PMID:17207425).
11. Jones KJ, Feiwell LA, Freedman EL, Cracchiolo A 3rd. The effect of chevron osteotomy with lateral capsular release on the blood supply to the first metatarsal head. *J Bone Joint Surg Am* 1995;77(2):197-204. (PMID:7844125).
12. Jaworek TE. The intrinsic vascular supply to the first metatarsal. *J Am Pod Ass* 1973;63:555-62. (PMID:4747889).
13. Wilkinson SV, Jones RO, Sisk LE, Sunshin KF, Van Manen JW. Austin bunionectomy: postoperative MRI evaluation for avascular necrosis. *J Foot Surg* 1992;31(5):469-77. (PMID:1430828).
14. Johnson KA, Cofield RH, Morrey BE. Chevron osteotomy for hallux valgus. *Clin Orthop* 1979;142:44-7. (PMID:498646).
15. Pochatko DJ, Schlehr FJ, Murphey MD, Hamilton JJ. Distal chevron osteotomy with lateral release for treatment of hallux valgus deformity. *Foot Ankle Int* 1994;15(9):457-61. (PMID:7820236).
16. Meier PJ, Kenzora JE. The risks and benefits of distal first metatarsal osteotomies. *Foot Ankle* 1985;6(1):7-17. (PMID:4043893).
17. Johnson KA. Chevron osteotomy. In: Johnson KA, ed. *The foot and ankle: master techniques in orthopedic surgery*. Raven Press, New York 1994, pp 31-48.
18. Resch S, Stenström A, Reynisson K, Jonsson K. Chevron osteotomy for hallux valgus not improved by additional adductor tenotomy. A prospective, randomized study of 84 patients. *Acta Orthop Scand* 1994;65:541-4. (PMID:7801759).
19. Tollison ME, Baxter DE. Combination chevron plus Akin osteotomy for hallux valgus: should age be a limiting factor? *Foot Ankle Int* 1997;18(8):477-81. (PMID:9278741).
20. Lian GJ, Markolf K, Cracchiolo A 3rd. Strength of fixation constructs for basilar osteotomies of the first metatarsal. *Foot Ankle* 1992;13:509-14. (PMID:1478580).



21. Ford TC, Maurer LM, Myrick KW. Cortical bone pin fixation: a preliminary report on fixation of digital arthrodeses and distal chevron first metatarsal osteotomies. *J Foot Ankle Surg* 2002;41:23-9. (PMID:11858603).
22. Thompson FM. Complications of hallux valgus surgery and salvage. *Orthopedics* 1990;13:1059-67. (PMID:2235738).
23. Chow FY, Lui TH, Kwok KW, Chow YY. Plate fixation for crescentic metatarsal osteotomy in the treatment of hallux valgus: an eight-year follow up study. *Foot Ankle Int* 2008;29(1):29-33. (PMID:18275733).
24. Randhawa S, Pepper D. Radiographic evaluation of hallux valgus treated with opening wedge osteotomy. *Foot Ankle Int* 2009;30(5):427-31. (PMID:19439143).
25. Crevoisier X, Mouhsin E, Ortolano V, Udin B, Butoit M. The Scarf osteotomy for the treatment of hallux valgus deformity: a review of 84 cases. *Foot Ankle Int* 2001;22:970-6. (PMID:11783923).