

Unexpected Thoracic Injury Caused by a Falling Bullet in a Metropolis

Mustafa Akman

Department of Pediatric Surgery, Faculty of Medicine, Nisa Hospital, Medipol University, Istanbul/Turkey

Abstract

The incident of being wounded by free-falling bullets is not usual in provinces where there is limited civilian armament in large metropolises. Cases that are wounded by falling bullet wounding apply to health-care institutions with major clinical manifestations. The patient was admitted with minor complaints, which manifested itself with mild back pain and spotting bleeding. An ovoid-style open wound was detected on the left scapula. Radiographic examination showed a semi-ovoid bullet-like radiodensity image inside the thoracic wall. In the evaluation performed under general anaesthesia, a bullet was found in the thoracic wall and was removed. In the standard follow-ups after the procedure, full recovery was achieved in the early period. Bullet wounds might be experienced outside of the battlefields without any direct fire, and these cases might not manifest the signs of gunshot injury. The cruciality of radiography in tackling diagnostic challenges was put forward.

Keywords: Child thorax, falling bullet, injury

INTRODUCTION

Uncontrolled individual armament and falling bullet injuries on battlefields are common, and health-care professionals are not late in the diagnosis and treatment. It can be easy to avoid the primary and secondary effects of firearm injuries in these countries, such as Iraq and Libya. In large metropolises, where individual armament is not common and where conflicts are not experienced, non-direct firing bullet injuries may cause a delay in the diagnosis due to the silent occurrence of the injury. Even with minor thoracic injuries, getting help from radiography in early diagnosis will lead to rapid diagnosis and thus positively affect morbidity and mortality.

CASE REPORT

A 7-year-old male patient was admitted to Istanbul Haseki Hospital with minor complaints, which manifested itself with mild back pain and spotting bleeding while he was in an open-air amusement park. Upon the first assessment, it was detected that haemodynamics was stable, and there were no complaints or manifestations related to thoracic and abdominal lesions. Other system examinations were considered normal as well.

An ovoid-style open wound on the left scapula and redness around it was detected during the initial inspection, and a swelling of unknown origin was detected 8 cm distal and lateral to the initial external lesion [Figure 1a and b]. Since the simple medical history and physical examination did not elucidate the etiopathogenesis of open a wound and swelling, chest radiography was added to the examination.

A semi-ovoid radiodensity image, which was coherent with the location of swelling, was obtained in the bilateral chest radiography inside of the thoracic wall [Figure 2]. This opaque material has been likened to a bullet core. It was determined that the gunfire was not heard in his story, apparently due to the crowded scene. It was considered that the foreign body might have advanced to the left subscapular region with a 65° vertical entrance [Figure 3]. Pathology was not detected in the haematological assessment.

Upon it could not be reached from the open wound, the foreign body was removed under general anaesthesia with

Address for correspondence: Prof. Mustafa Akman, Department of Pediatric Surgery, Faculty of Medicine, Nisa Hospital, Medipol University, Fatih Caddesi, Yenibosna 34197, Istanbul, Turkey. E-mail: drmustafaakman@yahoo.co.uk

Received: 28-09-2021 Revised: 05-11-2021 Accepted: 18-11-2021 Available Online: 15-12-2022

Access this article online

Quick Response Code:



Website:
www.afripaedurg.org

DOI:
10.4103/ajps.ajps_147_21

This is an open access journal, and articles are distributed under the terms of the Creative Commons Attribution-NonCommercial-ShareAlike 4.0 License, which allows others to remix, tweak, and build upon the work non-commercially, as long as appropriate credit is given and the new creations are licensed under the identical terms.

For reprints contact: WKHLRPMedknow_reprints@wolterskluwer.com

How to cite this article: Akman M. Unexpected thoracic injury caused by a falling bullet in a metropolis. *Afr J Paediatr Surg* 2023;20:77-9.

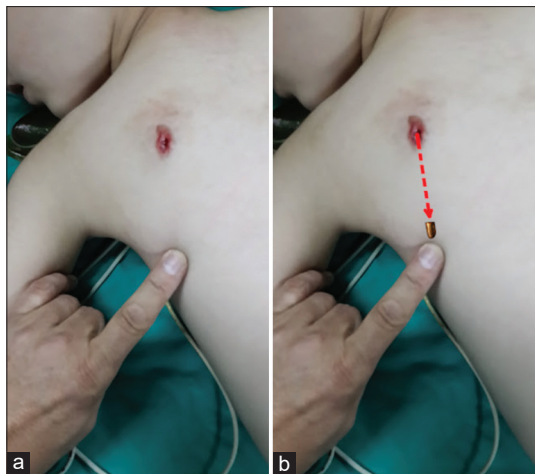


Figure 1: (a and b) Location and trajectory of the bullet

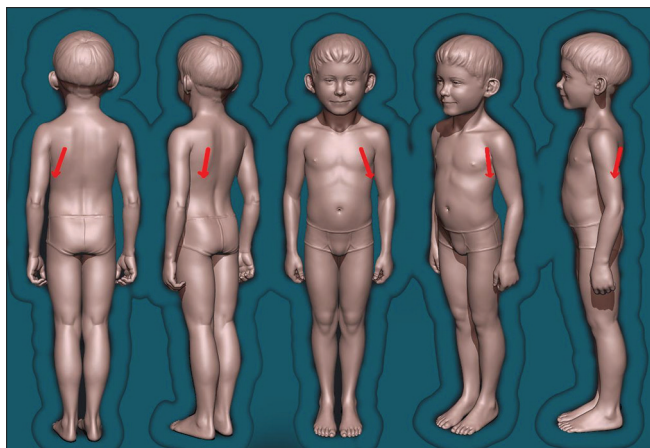


Figure 3: Illustration of the Trajectory of the bullet. (Picture credited by Ben aka Selvy)

an incision made over the location of the swelling. The wound was considered infected. Wound cleansing was conducted with povidone-iodine and hydrogen peroxide. A mini drain was placed in the lesion. Initially given one dose of intravenous antibiotic was continued with orally and discontinued within 5 days. Local wound infection did not develop. The drain was removed on the 5th day, and follow-up was terminated.

As a result of the ballistic examination of the foreign body, it was verified that it is a 9 mm × 19 mm calibre bullet and the wound was caused by a free-falling tired bullet [Figure 4].

DISCUSSION

Analysis of these types of wounds was performed considering the literature. Attempts to determine where bullets go after being fired into the sky have been made throughout history. In 1761, Wilson J. showed Benjamin Robins' Mathematical Tracts experiments with shooting large-bore low-velocity bullets into the air.^[1] Falling bullet effects were detailed by Di Maio VJM in 1999.^[2] Kinetics of falling bullets were also

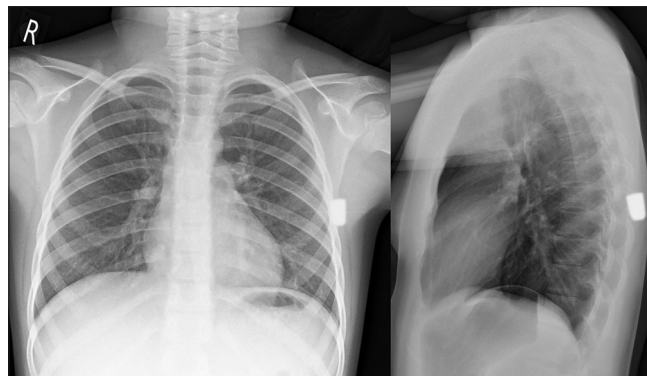

Figure 2: Chest radiography of the patient




Figure 4: The bullet. 9 mm × 19 mm calibre

explained by Hatcher JS in 1962.^[3] First falling bullet injury cases were reported by Hanieh A in 1971.^[4]

It was observed that almost all of the patients were children who were wounded by free-falling bullets, particularly on the battlefields and in provinces with uncontrolled individual armament.^[5,6] It was revealed in the case reports of Kadhim *et al.* (Iraq),^[7] Shuker and Sadda (Middle East),^[8] and Al-Tarshihi and Al-Basheer (Libya)^[9] *et al.* that there were incidents of child woundings due to free-falling bullets and the age distribution of these children ranged between 12 months and 15 years. It has been demonstrated that all children in these battlefields, where individual armament is the widespread and uncontrolled use of weapons is common, have serious symptoms.

It was reported that 2 of the 11 children, who were revealed by K. Kadhim *et al.*^[7] in their study, died, and some of them had permanent central and/or peripheral neurological problems. It was revealed that of the 15 children reported by M. I. Al-Tarshihi *et al.*,^[9] 2 died, while the others were diagnosed with major life-threatening findings. It was detected that one of the 6 children who had been reported by Sabri T. Shuker *et al.*^[8] had major symptoms, including permanent peripheral nerve damage. No patients with or without minor signs were reported in these three series. It has been verified in the literature that the risk of being wounded due to free-falling bullets is more increased in crowded environments^[5,6] and war zones.

Examining the incident records of police in Turkey, it was determined that it included the reports of the free-falling projectile woundings, 65 firearm injuries occurred due to the free fall of the bullet between 2000 and 2012, and 27 of which resulted in death. There are also cases with minor complaints that have been reflected in the media but not registered in medical records, which took place outside the big metropolitan area.^[10]

Upon examining the case series, it was determined that there was no case without any symptom.

CONCLUSION

Our case is the first child to be encountered and reported in a large metropolis. Contrary to the usual bullet woundings, the case was admitted with minor symptoms, and his medical record and physical examination did not indicate a gunshot wounding. Despite the absence of respiratory and haemodynamic complaints, the diagnosis was performed by chest radiography, which was shot upon suspicion. The fact that the gunfire was not heard, the bullet was located away from the entrance lesion, and the incident occurred outside the battlefield were among the factors that made the diagnosis challenging. The radiography was diagnostic during the first assessment, which was conducted without using chest radiography and prevented it from being interpreted as an idiopathic simple injury. Delay in diagnosis and treatment, which could lead to morbidity and mortality, was prevented by radiographic examination. Similarly, a potential delay in the judicial assessment of the incident was prevented.

A simple graphic examination in open woundings could be the most vital factor that changes the course of diagnosis and treatment, even if there are incompatibilities of anamnesis. Although tired bullet woundings occur in metropolitan areas, the differential diagnosis should be performed and radiographic assessment should not be ignored.

Declaration of patient consent

The authors certify that they have obtained all appropriate patient consent forms. In the form, the patient has given his consent for his images and other clinical information to be reported in the journal. The patient understands that name and initial will not be published and due efforts will be made to conceal identity, but anonymity cannot be guaranteed.

Financial support and sponsorship

Nil.

Conflicts of interest

There are no conflicts of interest.

REFERENCES

1. Wilson J. *Mathematical Tracts of the Late Benjamin Robins*. London: Robins, Benjamin, 1707-1751.
2. Di Maio VJ. *Gunshot Wounds Practical Aspects of Firearms, Ballistics, and Forensic Techniques*. 2nd ed. Florida: CRC Press LLC; 1999.
3. Hatcher JS. *Hatcher's Notebook*. Harrisburg, PA: The Stackpole Company; 1962.
4. Hanieh A. Brain injury from a spent bullet descending vertically. Report of five cases. *J Neurosurg* 1971;34:222-4.
5. Centers for Disease Control and Prevention (CDC). New Year's Eve injuries caused by celebratory gunfire-Puerto Rico, 2003. *MMWR Morb Mortal Wkly Rep* 2004;53:1174-5.
6. Khan MR, Yousaf N, Khan M, Shahdin Y. Spent-bullet injuries in the head and neck region (report of seven cases). *J Laryngol Otol* 1985;99:1319-23.
7. Kadhim AH, Neamah MJ, Nema IS. Cranial falling bullet injuries, a series of 30 cases in Iraq. *Br J Neurosurg* 2020;34:135-41.
8. Shuker ST, Sada R. Craniomaxillofacial falling bullet injuries and management. *J Oral Maxillofac Surg* 2010;68:1593-601.
9. Al-Tarshihi MI, Al-Basheer M. The falling bullets: Post-Libyan revolution celebratory stray bullet injuries. *Eur J Trauma Emerg Surg* 2014;40:83-5.
10. Ögünç Gİ, Özer MT, Çoşkun K, Eryılmaz M, Uzar AI. The wounding potential of free-falling bullets. *Ulus Travma Acil Cerrahi Derg* 2013;19:392-7.