


Contents lists available at [ScienceDirect](https://www.sciencedirect.com)

American Journal of Otolaryngology–Head and Neck Medicine and Surgery

journal homepage: www.elsevier.com/locate/amjoto

U shaped costal cartilage resection to reduce donor site morbidity

Erol Senturk^{a,*}, Nurtac Dagistanli^a, Orhan Ozturan^a, Erkan Soylu^b

^a Bezmialem Vakif University, Faculty of Medicine, Department of Otorhinolaryngology, Fatih, Istanbul, Turkey

^b Medipol University, Faculty of Medicine, Department of Otorhinolaryngology, Bagcilar, Istanbul, Turkey

ARTICLE INFO

Keywords:
Costal cartilage
Rhinoplasty

ABSTRACT

Objective: The aim of our study is to reduce the complications of pain and chest wall deformity by modifying conventional costal cartilage graft harvesting.

Method: In this method while the superior part of the costal cartilage is removed completely, medial, lateral, and inferior parts are excised incompletely and used as a graft. Hence, continuity of the costal cartilage is maintained inferiorly.

Results: Nineteen primary and 28 revision rhinoplasty patients were included in the study. There were no donor site complications in the early postoperative period or during one-year follow-up.

Conclusion: The modified costal cartilage graft harvesting technique we described is a safe conservative surgical method.

1. Introduction

Rhinoplasty is one of the surgical methods frequently applied in facial plastic surgery practice today. As a result of the increasing number of this surgery performed, the need for revision surgery is also increasing. The demand for additional cartilage grafts arises both due to the increase in revision surgeries and in some primary surgeries, such as in the Asian population, where nasal septal cartilage grafts are insufficient [1].

Autologous costal cartilage is a readily accessible and reliable reserve when a large amount of graft is needed [2]. While the 6th and 7th rib segments are generally used in classical techniques, lower segments can also be used. When used in young patients, this graft is more prone to warping, while in older patients, the cartilage may be calcified [3].

When deciding to use autologous costal cartilage, potential donor site complications such as pain, pneumothorax, chest wall deformity, and scarring should be discussed with the patient [2]. Various surgical techniques have been described to reduce these complications [4]. The aim of this article is to modify the conventional surgical technique of costal cartilage removal for the purpose of less pain and maintenance of the chest wall.

2. Technique

The study was conducted retrospectively from medical records. Ethics committee approval and consent form were not obtained because it did not contain an identifiable personal photograph. Patients who were decided to use costal cartilage for primary or revision rhinoplasty were included in the study. All patients were operated on by a single expert surgeon (Soylu E.).

2.1. Surgical technique

The procedure is started with oral intubation under general anesthesia. The right 6th, 7th, and 8th costae are identified, and the mid-clavicular line was sterilized. Local anesthetic infiltration (1 % Lidocaine with 1:100,000 Epinephrine) is performed. A 3 cm skin incision is made at the midclavicular line. Subcutaneous fat tissue is traversed with electrocautery. The muscular fascia is reached and incised. Without cutting the muscle tissue, blunt dissection is performed parallel to the muscle fibers to expose the costal perichondrium. The perichondrium is incised and elevated superiorly. A broad-based ‘U’ shaped incision is made medially, laterally, and inferiorly around the desired amount of cartilage. A wide cartilage strip is left inferiorly to maintain costal cartilage continuity. The cartilage graft is elevated and removed. The posterior perichondrium was preserved. After ensuring hemostasis, the wound area is filled with saline to check for pleural tear. At this time, the

* Corresponding author.

E-mail address: erolsent@gmail.com (E. Senturk).

<https://doi.org/10.1016/j.amjoto.2024.104468>

Received 28 July 2024;

Available online 3 August 2024

0196-0709/© 2024 Elsevier Inc. All rights are reserved, including those for text and data mining, AI training, and similar technologies.

anesthesia team is asked to perform the Valsalva maneuver. After confirming no air leak, the remaining perichondrium is sutured and closed. The muscle fascia is sutured, and the subcutaneous tissue is closed. No drain is used (Video 1) (Fig. 1).

3. Results

Ten non-Caucasian (platyrrhine, mesorrhine) nose rhinoplasty, nine Asian nose rhinoplasty and 28 revision rhinoplasty patients who underwent surgery using costal cartilage between 2020 and 2023 were included in the study. The age range of the patients was 18–65 (mean 28.4). The average surgical time was 25 min. No intraoperative donor site complications occurred in any of the patients. Postoperative pain was minimal and all patients were mobilized on the first day. They were discharged the next day with oral antibiotics and analgesics. There was no patient with a significant scar or chest wall deformity at the donor site postoperatively. After one year of follow-up, we did not have any patients who required revision surgery due to cartilage warping.

4. Discussion

Autogenous septal cartilages are the gold standard in rhinoplasty [5]. The frequencies of rejection, infection and extrusion are very low in autogenous grafts [6]. Auricular cartilage can be used when needed, but this cartilage has limitations regarding elasticity and curvature. Access to irradiated cadaver cartilages is not easy and costly [7].

Costal cartilage is a good option for primary or secondary rhinoplasty that requires a larger amount of graft. Costal cartilage is strong, flexible and durable. Costal cartilage complications are warping, resorption, infection and contour irregularities.

Potential donor site complications that are rare in costal cartilage harvesting are pneumothorax, infection, bleeding, and hematoma. Complications that are not uncommon are seroma, persistent pain and wound site problems [8]. Various modifications have been made in

surgical techniques to avoid these complications.

In conventional surgical technique, unused grafts are discarded and deformities may occur in the chest wall [9]. Continuous negative respiratory pressure may increase these deformities, especially in young children. For this reason, Ozturan et al. emphasized the importance of replacing the remaining cartilage to maintain the continuity of the costal cartilage [10]. Some authors stated that leaving the perichondrium behind is necessary for the formation of new cartilage [11]. In the technique described by Boyacı et al., it is recommended to avoid complications by removing only the central part of the cartilage [4]. For a similar purpose, Yotsuyanagi and his colleagues described removing only the central part of the rib with a chisel [12]. In our technique, since the inferior rim of the rib is preserved, no chest wall deformity is observed.

Persistent pain is another common complication after costal cartilage harvesting. In the costal cartilage study conducted by Uppal and colleagues for ear reconstruction, pain at the donor site was the most common complaint. In fact, in their 3 patients, pain continued in the first postoperative year [13]. Severe pain in the donor site not only disrupts patient comfort but can also delay patient mobilization. This poses a risk for complications such as embolism. Yotsuyanagi et al. reported that pain was less common in their described technique, attributing this to less movement of the chest wall and intact muscle tissues [13]. In our study, no patients experienced severe postoperative pain. All patients were mobilized within three hours postoperatively, and no persistent pain was observed after one year. We attribute this to the preservation of the inferior border of the rib and only blunt dissection of the pectoralis muscle. Nervus intercostalis courses together with the artery and vein in the intercostal sulcus, inferior to the rib [14]. Preserving the inferior border of the rib may prevent irritative stimulation of the intercostal nerve. In addition, the perichondrium protected at the upper border also ensured the protection of the vascular nerve bundle above it.

The limitation of our study is that all our patients were adults. Costal cartilage is also frequently used for auricular reconstruction. Therefore,

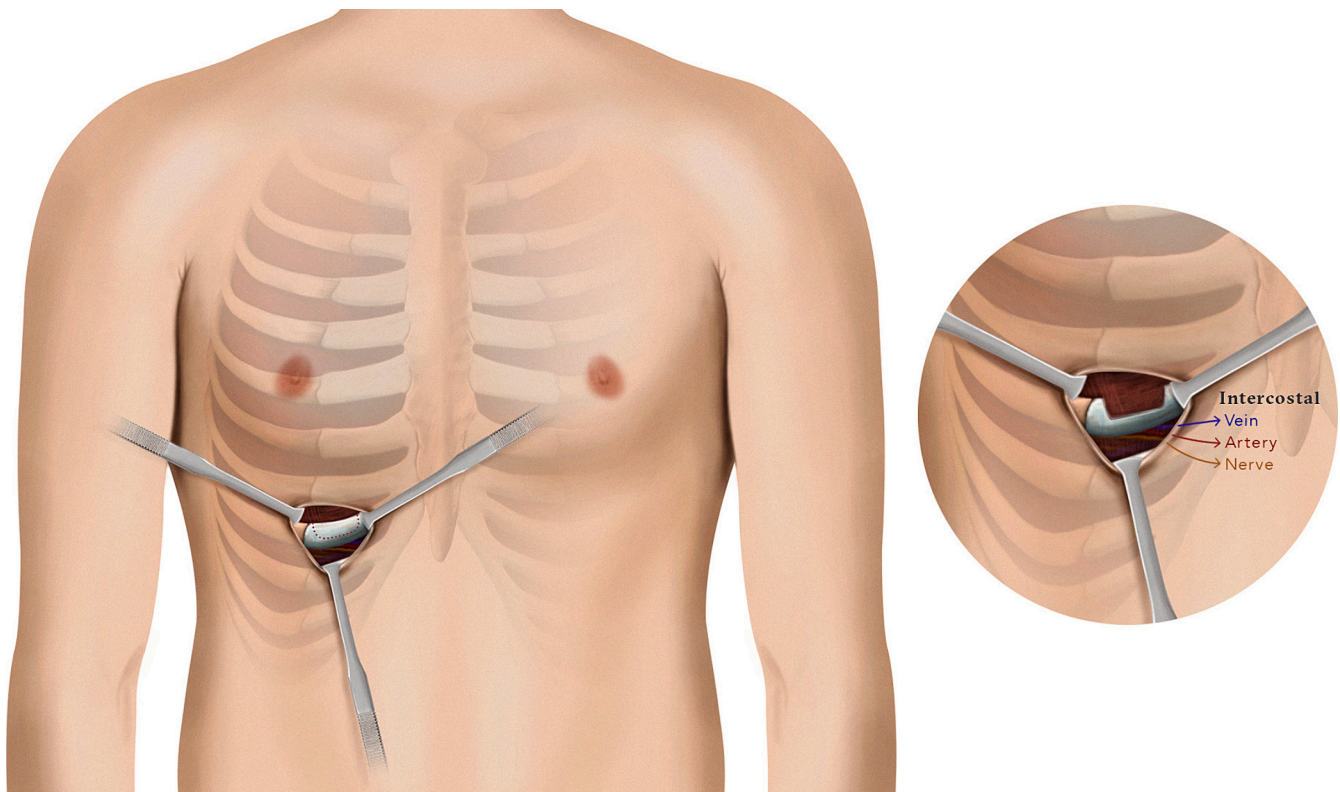


Fig. 1. Schematic view of costal cartilage graft harvesting.

the use of our surgical modification in the pediatric group may be the subject of another study. Additionally, a comparative study with the classical technique can be planned.

5. Conclusion

The technique we described for costal cartilage harvesting can be safely applied as it results in less pain and mitigates chest wall deformity compared to conventional techniques.

This research did not receive any specific grant from funding agencies in the public, commercial, or not-for-profit sectors.

Supplementary data to this article can be found online at <https://doi.org/10.1016/j.amjoto.2024.104468>.

CRedit authorship contribution statement

Erol Senturk: Conceptualization, Data curation, Investigation, Methodology, Project administration, Writing – original draft. **Nurtac Dagistanli:** Conceptualization, Data curation, Writing – original draft. **Orhan Ozturan:** Supervision, Writing – review & editing. **Erkan Soylu:** Conceptualization, Data curation, Methodology, Supervision.

References

- [1] Park JH, Jin HR. Use of autologous costal cartilage in Asian rhinoplasty. *Plast Reconstr Surg* 2012 Dec;130(6):1338–48. <https://doi.org/10.1097/PRS.0b013e31826d9f03> [PMID: 23190817].
- [2] Fedok FG. Costal cartilage grafts in rhinoplasty. *Clin Plast Surg* 2016 Jan;43(1): 201–12. <https://doi.org/10.1016/j.cps.2015.08.002> [Epub 2015 Oct 24. PMID: 26616708].
- [3] Kridel RW, Ashoori F, Liu ES, Hart CG. Long-term use and follow-up of irradiated homologous costal cartilage grafts in the nose. *Arch Facial Plast Surg* 2009 Nov-Dec;11(6):378–94. <https://doi.org/10.1001/archfacial.2009.91> [PMID: 19917899].
- [4] Boyaci Z, Çelik Ö, Ateşpare A, Koca Ö. Conservative costal cartilage harvest for revision septorhinoplasty. *J Craniofac Surg* 2013 May;24(3):975–7. <https://doi.org/10.1097/SCS.0b013e318280254a> [PMID: 23714925].
- [5] Lovice DB, Mingrone MD, Toriumi DM. Grafts and implants in rhinoplasty and nasal reconstruction. *Otolaryngol Clin North Am* 1999 Feb;32(1):113–41. [https://doi.org/10.1016/S0030-6665\(05\)70118-3](https://doi.org/10.1016/S0030-6665(05)70118-3) [PMID: 10196441].
- [6] Vuyk HD, Adamson PA. Biomaterials in rhinoplasty. *Clin Otolaryngol Allied Sci* 1998 Jun;23(3):209–17. <https://doi.org/10.1046/j.1365-2273.1998.00133.x> [PMID: 9669068].
- [7] Burke AJ, Wang TD, Cook TA. Irradiated homograft rib cartilage in facial reconstruction. *Arch Facial Plast Surg* 2004 Sep-Oct;6(5):334–41. <https://doi.org/10.1001/archfacial.6.5.334> [PMID: 1538 1581].
- [8] Moon BJ, Lee HJ, Jang YJ. Outcomes following rhinoplasty using autologous costal cartilage. *Arch Facial Plast Surg* 2012 May-Jun;14(3):175–80. <https://doi.org/10.1001/archfacial.2012.138> [PMID: 22801761].
- [9] Ohara K, Nakamura K, Ohta E. Chest wall deformities and thoracic scoliosis after costal cartilage graft harvesting. *Plast Reconstr Surg* 1997 Apr;99(4):1030–6. <https://doi.org/10.1097/00006534-199704000-00017> [PMID: 9091899].
- [10] Ozturan O, Yenigun A, Yurtsever I, et al. The benefit of replacing the excess costal cartilage in rhinoplasty. *Eur J Plast Surg* 2022;45:1027–9. <https://doi.org/10.1007/s00238-022-01943-4>.
- [11] Skouteris CA, Sotereanos GC. Donor site morbidity following harvesting of autogenous rib grafts. *J Oral Maxillofac Surg* 1989 Aug;47(8):808–12. [https://doi.org/10.1016/s0278-2391\(89\)80038-2](https://doi.org/10.1016/s0278-2391(89)80038-2) [PMID: 2746389].
- [12] Yotsuyanagi T, Mikami M, Yamauchi M, Higuma Y, Urushidate S, Ezoe K. A new technique for harvesting costal cartilage with minimum sacrifice at the donor site. *J Plast Reconstr Aesthet Surg* 2006;59(4):352–9. <https://doi.org/10.1016/j.bjps.2005.04.049> [PMID: 16756249].
- [13] Uppal RS, Sabbagh W, Chana J, Gault DT. Donor-site morbidity after autologous costal cartilage harvest in ear reconstruction and approaches to reducing donor-site contour deformity. *Plast Reconstr Surg* 2008 Jun;121(6):1949–55. <https://doi.org/10.1097/PRS.0b013e318170709e> [PMID: 18520880].
- [14] Blevins CE. Anatomy of the thorax. In: In Shields TW, editor. *General thoracic surgery*. 6th ed. Philadelphia: Lippincott Williams and Wilkins; 2005. p. 3–16.