

Aesthetic Repair of Zirconia-Supported Porcelain Prosthesis with Ceramic Veneer, Case Report with 3-Year Follow-up

TUGCE MERVE ORDUERI¹, ASENA KAPTANOGL², MEHMET MUZAFFER ATES³

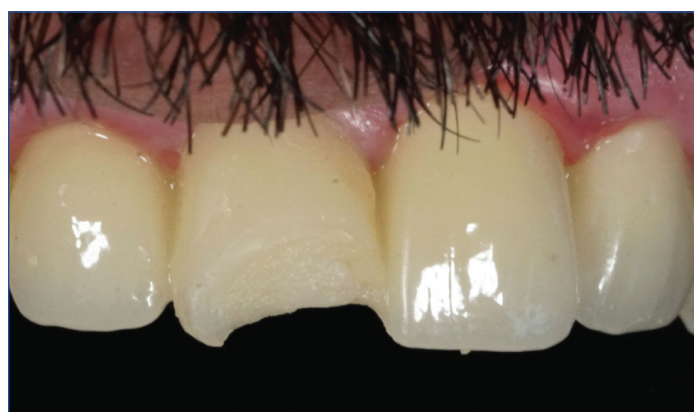ABSTRACT

Chipping is the most common complication in zirconia-supported porcelain prosthesis. If the prosthesis has ideal adaptation and there is no problem other than chipping, intraoral repair is the most practical solution for such failures. Composite resins are often preferred for intraoral porcelain repair. However, the wear and unstable colour of composite resins negatively affect aesthetics. This complication could be restored intraorally and aesthetically with ceramic veneer. This case report presents the intraoral repair of a zirconia supported Fixed Partial Denture (FPD) consisting of four units. The cohesive fracture of the ceramic material in the incisal part of maxillary right central incisor was restored with ceramic veneers. Preparation was done with a tapered, rounded end diamond bur under water-cooling. The impression was taken with elastomeric impression material. Ceramic veneer was manufactured with a leucite-reinforced glass-ceramic and cemented with light cure resin cement. Based on the three-year follow up of the performed intraoral repair, ceramic veneers have shown to be an alternative treatment for fractured FPD.

Keywords: Chipping, Fracture, Intraoral repair, Porcelain veneer

CASE REPORT

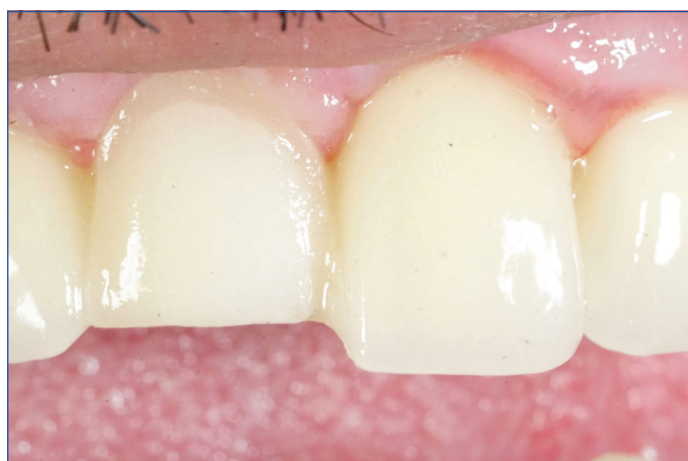A 38-year-old male patient visited a private dental office with complaints about the fracture that occurred two days ago, in a four-unit porcelain veneered zirconia FPD, which was delivered one-year-ago. The FPD was located between upper right and left second incisors. After the oral examination, it was observed that the fracture was in the ceramic fragment of the right central incisor [Table/Fig-1]. All treatment options regarding the porcelain chipping (porcelain fracture without zirconia framework exposure) were explained to the patient. The patient refused to renew his FPD due to clinical time and cost. Patient approved of ceramic veneer, as it would be more aesthetic than to repair with composite resin.



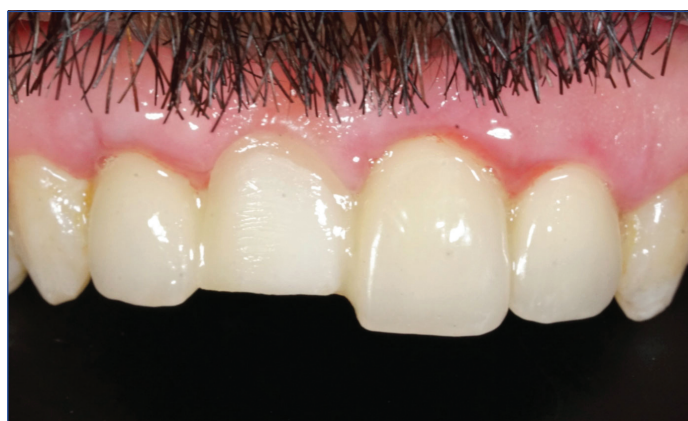[Table/Fig-1]: Patient presents chipping at the incisal area of veneered zirconia fused to multiunit zirconia bridge at tooth.

The labial surface of the right central incisor was prepared with a tapered, rounded-end diamond bur (Meisinger, Hager and Meisinger GmbH, Dusseldorf, Germany) under water coolant until a flat surface was obtained on the ceramic. All sharp edges and corners were smoothed. Chamfer marginal finish line was prepared in order to avoid stress build-up [Table/Fig-2a,b].

After the completion of the preparation, the impression was taken via additional type elastomeric impression material (Elite H-D, Zhermack, Germany). The porcelain veneers were fabricated using a leucite-reinforced glass-ceramic (IPS Empress E.max, IvoclarVivadent, Schaan, Liechtenstein) [Table/Fig-3].



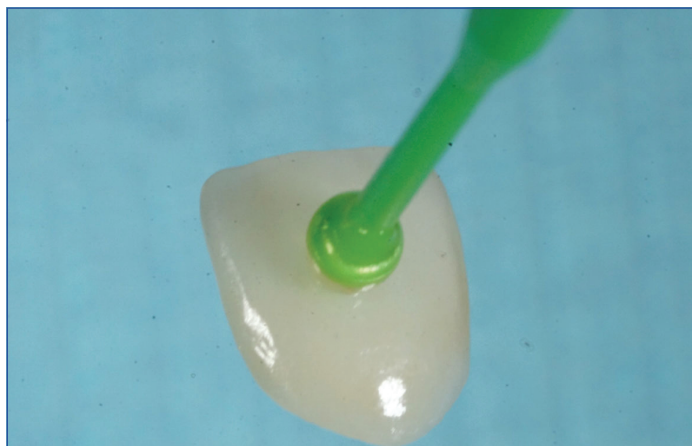[Table/Fig-2a]: Close-up view of preparation.



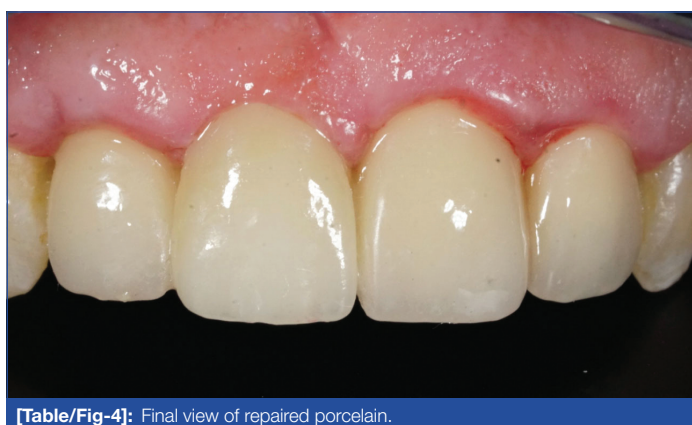
[Table/Fig-2b]: Prepared porcelain in tooth 11.

A light curing gingival barrier (OpalDam, Ultradent) was applied to protect the periodontal tissues. The porcelain surface and inner surface of the laminate veneer were etched with 9.5% Hydrofluoric (HF) acid (Ultradent) for one minute, washed, and dried. Silane (Monobond N, IvoclarVivadent, Liechtenstein) was applied to both surfaces with microbrush and waited for one minute. A thin layer of bonding (Heliobond, IvoclarVivadent, Liechtenstein) was applied and light cured for 20 seconds. It was cemented with Variolink N

LC (IvoclarVivadent, Liechtenstein). Residual cement was removed. The polymerisation was completed with the application of additional 40 seconds of light curing [Table/Fig-4]. As the patient had tooth wear in lower anterior incisal surfaces and posterior occlusal surfaces (bruxism), a stabilisation splint was made and the patient was recommended to use it during sleep.

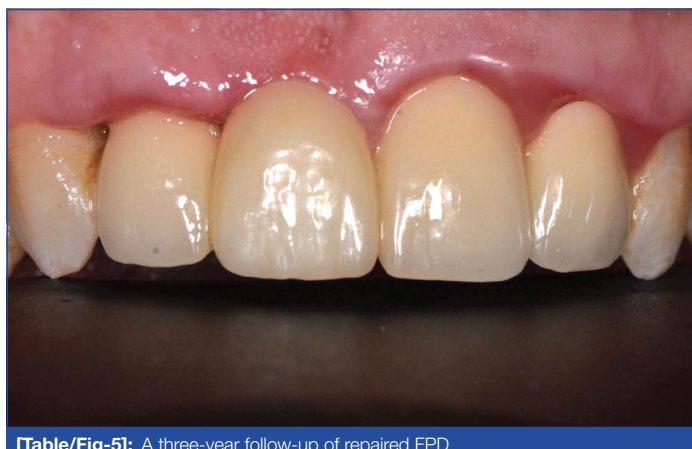

[Table/Fig-3]: Ceramic veneer etched with HF acide, washed and dried.



[Table/Fig-4]: Final view of repaired porcelain.

The FPD and the ceramic veneer intraoral repair survived for 3 years to this date [Table/Fig-5]. Marginal integrity, marginal discoloration, anatomical form, restoration colour stability and periodontal health were evaluated after three years. All of the criteria were acceptable except periodontal health. The patient was motivated about tooth brushing and dental floss use.



[Table/Fig-5]: A three-year follow-up of repaired FPD.

DISCUSSION

Zirconia-supported fixed prostheses are preferred as they have been used successfully for the past two to three decades due to their colour, excellent biocompatibility, and mechanical properties [1]. Also, they are more aesthetic than metal-supported prostheses [2]. Nevertheless, the disadvantage of zirconia-supported prosthesis is the inadequate bonding between Zirconia core and the veneering

ceramic layer due to failure of adhesion between two chemically different materials [3]. Separation of porcelain fragment from the framework as plates (delamination) or by chipping are most common failures in zirconia-supported restorations [4,5].

Due to the increase in application frequency of zirconia-based restorations and the higher fracture rates in long-term follow-up studies compared to metal-based restorations [6,7], the need of repair has become more important.

In literature, veneer fractures are classified in 3 grades. Grade-1 refers to chipping of a small amount of veneer fragment that can be repaired with re-shaping and polishing. Grade-2 contains moderate chipping that can be repaired intraorally with composite. Grade-3 refers to severe chipping in need replacement of the FPD [8].

Considering the potential risks of removing the broken FPD, financial limitations, and the time spent for renewal of restoration, this treatment option is not a practical solution. If Grade-3 fracture is seen, replacement of FPD is inevitable [9-11].

If the restoration can continue its function in the mouth after fracture and there is no other reason for renewal of prosthetic restoration, the intraoral repair provides convenience for both the patient and the physician [12].

Composite resins are often applied to porcelains that have failure and there are many systems developed for intraoral repair with composite resins [13-15]. In the meantime, the prognosis of the intraoral repair with composite is controversial due to the wearing of the composite over the time and its lack of colour stability compared to ceramic used in direct intraoral repair methods [16]. Amongst the intraoral repair systems, ceramic veneers have a superior success rate compared to using composite resins especially in cases where the ceramic contains large fractures [17].

The aesthetic properties of full ceramics are more successful than composite resins. They have colour stability and high resistance to wear, and their bond strength to the substructures during repair is found to be sufficient in the studies. These properties has led to the idea that the use of ceramics for porcelain repair can be increased in clinically [18].

The recent studies performed with zirconia supported restorations have concluded that the shear bond strength of the repair made with ceramics is higher than composite, meaning that the intraoral repair made with ceramics is better alternative [17,19].

In intraoral repair methods, diamond burs are used to smoothen the chipped surface of the ceramic. Rising of heat can cause possible formation and propagation of cracks. In literature, abundant cooling was performed in order to avoid ceramic heating at this stage [20].

The most common methods for the surface treatment of ceramics after chipping are acid etching, sandblasting with aluminum oxide or sandblasting with silica-coated particles [21]. Etching with acid increases the surface area and energy of the ceramic, and the bonding ratio of resin to ceramic increases with the surface energy [18,22].

Although it is a subject of discussion to use HF acid in etching due to the harmful effects of HF acid on tissues, there has been no reports of complications related to HF acid in the dental literature [23]. While applying HF acid intraorally for porcelain repair, the isolation of gingival area with rubberdam will protect patients from possible hazardous effects [21].

Traditionally, porcelain-chipped restorations are repaired with composite resin technique. More well-designed intraoral studies are necessary to justify this ceramic veneer repair technique.

CONCLUSION(S)

Direct repair techniques are good alternative treatments in fracture or chipping of the veneering ceramic, without the need for replacement

of the prosthesis. In case of fracture in porcelain veneered zirconia framework restorations, ceramic veneers can be used in intraoral repair technique, as a better alternative than composite resins. The fact that no complications were observed during the three years follow-up of the patient showed that porcelain ceramic veneers can be considered as a long-term repair option.

REFERENCES

- [1] Daou EE. The Zirconia ceramic: strengths and weaknesses. *Open Dent J*. 2014;8(1):33-42.
- [2] Meirelles PD, da Rocha LS, Pecho OE, Della Bona A, Benetti P. Intraoral repair of a chipped porcelain-zirconia restoration. *J Esthet Restor Dent*. 2020;32(5):444-50.
- [3] Urapepon S, Taenguthai P. The effect of zirconia framework design on the failure of all-ceramic crown under static loading. *J Adv Prosthodont*. 2015;7(2):146-50.
- [4] Raigrodski AJ, Hillstead MB, Meng GK, Chung KH. Survival and complications of zirconia-based fixed dental prostheses: A systematic review. *J Prosthet Dent*. 2012;107(3):170-77.
- [5] Pihlaja J, N ap ankangas R, Raustia A. Early complications and short-term failures of zirconia single crowns and partial fixed dental prostheses. *J Prosthet Dent*. 2014;112(4):778-83.
- [6] Sailer I, Feh er A, Filser F, L uthy H, Gauckler LJ, Sch arer P, et al. Prospective clinical study of zirconia posterior fixed partial dentures: 3-year follow-up. *Quintessence Int*. 2006;37(9):685-93.
- [7] Raigrodski AJ, Chiche GJ, Potiket N, Hochstedler LJ, Mohamed SE, Billiot S, et al. The efficacy of posterior three-unit zirconium-oxide-based ceramic fixed partial dental prostheses: A prospective clinical pilot study. *J Prosthet Dent*. 2006;96(4):237-44.
- [8]  zcan M, Volpato CAM. Surface conditioning protocol for the adhesion of resin-based materials to glassy matrix ceramics: How to condition and why? *J Adhes Dent*. 2015;17(3):292-93.
- [9] Demirekin ZB,  avdarlı K, T urkaslan SS. Ceramic veneers: a conservative alternative for intraoral repair. *SDU J Heal Sci Inst*. 2016;7(11):64-68.
- [10] Ayingu C, yuan ZC, wu JN, Cheng H,  zcan M, Yu H. Intraoral repair of chipped or fractured veneered zirconia crowns and fixed dental prosthesis: Clinical guidelines based on literature review. *J Adhes Sci Technol*. 2018;32(15):1711-23.
- [11] Lee SJ, Cheong CW, Wright RF, Chang BM. Bond strength of the porcelain repair system to all-ceramic copings and porcelain. *J Prosthodont*. 2014;23(2):112-16.
- [12]  zcan M, Valandro LF, Amaral R, Leite F, Bottino MA. Bond strength durability of a resin composite on a reinforced ceramic using various repair systems. *Dent Mater*. 2009;25(12):1477-83.
- [13] Han IH, Kang DW, Chung CH, Choe HC, Son MK. Effect of various intraoral repair systems on the shear bond strength of composite resin to zirconia. *J Adv Prosthodont*. 2013;5(3):248-55.
- [14]  zcan M, Van Der Sleen JM, Kurunm aki H, Vallittu PK. Comparison of repair methods for ceramic-fused-to-metal crowns. *J Prosthodont*. 2006;15(5):283-88.
- [15] Kocaa ao lu H, Manav T, Albayrak H. In Vitro Comparison of the Bond Strength between Ceramic Repair Systems and Ceramic Materials and Evaluation of the Wettability. *J Prosthodont*. 2017;26(3):238-43.
- [16] Cardoso A. C, Spinelli Filho P. Clinical and laboratory techniques for repair of fractured porcelain in fixed prostheses: A case report. *Quintessence Int*. 1994;25(12):835-38.
- [17] Kumchai H, Juntavee P, Sun AF, Nathanson D. Comparing the repair of veneered zirconia crowns with ceramic or composite resin: An in vitro study. *Dent J*. 2020;8(2):01-12.
- [18] Alada  A,   mleko lu EM. Indirect ceramic repair with a metal-ceramic laminate veneer: case report. *E  Di ek Fak Derg*. 2009;30:47-51.
- [19] Habib SR, Bajunaid S, Almansour A, AbuHaimed A, Almuqrin MN, Alhadlaq A, et al. Shear bond strength of veneered zirconia repaired using various methods and adhesive systems: A comparative study. *Polymers (Basel)*. 2021;13(6):910.
- [20]  zcan M, Volpato M. Intra-oral repair technique for ceramic fracture using direct resin composite. *Ital J Dent Med*. 2016;8(8):67-70.
- [21] Kimmich M, Stappert CFJ. Intraoral treatment of veneering porcelain chipping of fixed dental restorations. *J Am Dent Assoc*. 2014;144(1):31-44.
- [22] Carrabba M, Vichi A, Louca C, Ferrari M. Comparison of traditional and simplified methods for repairing CAD/CAM feldspathic ceramics. *J Adv Prosthodont*. 2017;9(4):257-64.
- [23]  zcan M, Allahbeickaraghi A, D ndar M. Possible hazardous effects of hydrofluoric acid and recommendations for treatment approach: A review. *Clin Oral Investig*. 2012;16(1):15-23.

PARTICULARS OF CONTRIBUTORS:

1. Dentist, Department of Prosthodontics, Medipol University, Istanbul, Turkey.
2. Dentist, Department of Prosthodontics, Medipol University, Istanbul, Turkey.
3. Professor and Head, Department of Prosthodontics, Medipol University, Istanbul, Turkey.

NAME, ADDRESS, E-MAIL ID OF THE CORRESPONDING AUTHOR:

Dr. Tugce Merve Ordueri,
Kazimiye Mah, Barbaros 2, Sok. Tello lu Plaza. K:4 D:5  orlu, Tekirda , Turkey.
E-mail: tugceordueri@gmail.com

AUTHOR DECLARATION:

- Financial or Other Competing Interests: None
- Was informed consent obtained from the subjects involved in the study? Yes
- For any images presented appropriate consent has been obtained from the subjects. Yes

PLAGIARISM CHECKING METHODS:

- Plagiarism X-checker: Mar 30, 2021
- Manual Googling: Apr 12, 2021
- iThenticate Software: Apr 28, 2021 (11%)

ETYMOLOGY: Author Origin

Date of Submission: **Mar 14, 2021**
Date of Peer Review: **Mar 30, 2021**
Date of Acceptance: **Apr 27, 2021**
Date of Publishing: **Jun 01, 2021**

Copyright of Journal of Clinical & Diagnostic Research is the property of JCDR Research & Publications Private Limited and its content may not be copied or emailed to multiple sites or posted to a listserv without the copyright holder's express written permission. However, users may print, download, or email articles for individual use.