



Spontaneous Regression of Lumbar Disc Herniation After Weight Loss: Case Report

Zayıflama Sonrası Lomber Disk Herniasyonunun Spontan Regresyonu: Olgu Sunumu

Mehmet TOKMAK¹, Inci BALTEPE ALTIOK², Mustafa GUVEN³, Adem Bozkurt ARAS³, Murat COSAR³

¹Istanbul Medipol University, School of Medicine, Department of Neurosurgery, Istanbul, Turkey

²Istanbul Medipol Hospital, Department of Radiology, Istanbul, Turkey

³Canakkale Onsekiz Mart University, School of Medicine, Department of Neurosurgery, Canakkale, Turkey

Corresponding Author: Mustafa GUVEN / E-mail: drmustafaguvenc@comu.edu.tr

ABSTRACT

Diagnosis, treatment, and surgery for lumbar disc herniations have existed for over a century. However, during the last three decades, there have been many new developments in imaging techniques, surgical procedures, physical medicine, and rehabilitation. In light of this, the most effective and appropriate treatment is controversial. Spontaneous regression of sequestered, extruded, or protruded disc herniation has often been reported in the literature, although it is still a rare phenomenon. After a thorough review of the literature, we did not find any case report about this phenomenon after weight loss. In this report, though, we present a recent case about spontaneous regression of extruded disc herniation following weight loss.

KEYWORDS: Conservative management, Lumbar disc, Disc herniation, Discectomy

ÖZ

Lomber disk hernisi için tanı, tedavi ve cerrahi yaklaşık yüz yıldır bilinmektedir. Bununla birlikte son 30 yıl içinde görüntüleme tekniklerinde, cerrahi tekniklerde ve fizik tedavi rehabilitasyonda birçok yeni gelişmeler olmuştur. Bunun ışığında, en etkili ve uygun tedavi halen tartışmalıdır. Sekestre, ekstrüde veya protrüde disk hernisinin spontan regresyonu literatürde sıkça bildirilmiş olmasına rağmen hâlâ nadir bir fenomendir. Bu fenomen hakkında literatürü taradığımızda, zayıflama sonrası disk hernisinin spontan regrese olduğuna dair bir olgu sunumuna rastlanmadı. Bu olguda zayıflamayı takiben ekstrüde disk hernisinin spontan regrese olduğu gösterildi.

ANAHTAR SÖZCÜKLER: Konservatif yaklaşım, Lomber disk, Disk herniasyonu, Diskektomi

INTRODUCTION

Lumbar disc hernia is a common disease, causing radicular and low back pain. Mixer and Barr reported in 1934 that extruded disc material can cause sciatic pain, and they established surgical treatment for it. Since then, different surgical procedures for discectomy have been performed (21). While some cases of lumbar disc herniation necessitate surgery, most of them heal with conservative treatment. It is well-known in this field that neurological symptoms of lumbar disc herniation can heal without surgical intervention (6, 13), which was first shown by Guinto et al. (1984) with computerized tomography (CT) (8). Both CT and magnetic resonance imaging (MRI) have been used to document regression of disc herniation at different spinal compartments (5, 14, 19, 28-30). An increasing number of studies have described this phenomenon, but spontaneous regression of a large extruded lumbar disc is rare (23). In this article, we present a case of regressed large disc herniation in an obese, diabetic patient who refused surgery. After weight loss, her symptoms started to diminish, and they disappeared in six months. On MRI study one year and a half later, we saw that

the extruded disc at the L5-S1 level had actually vanished; we became extremely interested in possible explanations for this spontaneous regression. It is a well-known phenomenon described in the literature for a large extruded lumbar disc after weight loss (despite not having encountered a case of spontaneous regression ourselves).

CASE REPORT

A 42 year-old woman first experienced low back pain in December 2008. Minimal bulging at the L4-5 and L5-S1 level was shown on MRI at the time (Figure 1A-C). After one year, she started to gain weight, while over the next two years, she gained approximately 30 kg. At the beginning of 2011, she suddenly developed right leg pain with numbness, along with low back pain: unfortunately, she had no benefit from medical treatment or physiotherapy at that time. When her pain increased, in addition to difficulty with walking, she was referred to our neurosurgery clinic in February 2011. Neurological examination showed hypoesthesia on the right S1 dermatome, decrease in the Achilles' reflex, but only 10 degrees of straight leg raising. On the initial MRI study, right

posterolateral extruded disc herniation (migrating caudally) was demonstrated (Figure 2A-C). Surgical treatment was suggested, but the patient refused again. We then prescribed some analgesic anti-inflammatory drugs, muscle relaxing agents, vitamin B12, and narcotics instead.

We also suggested rest and referred her to a dietitian. The patient had been encouraged to see an endocrinologist, at which time type 2 diabetes mellitus was diagnosed after laboratory tests. Thereafter, metformin HCL (Matofin, Sanovel Drugs) 500 mg was prescribed, and she lost 25 kg in 10

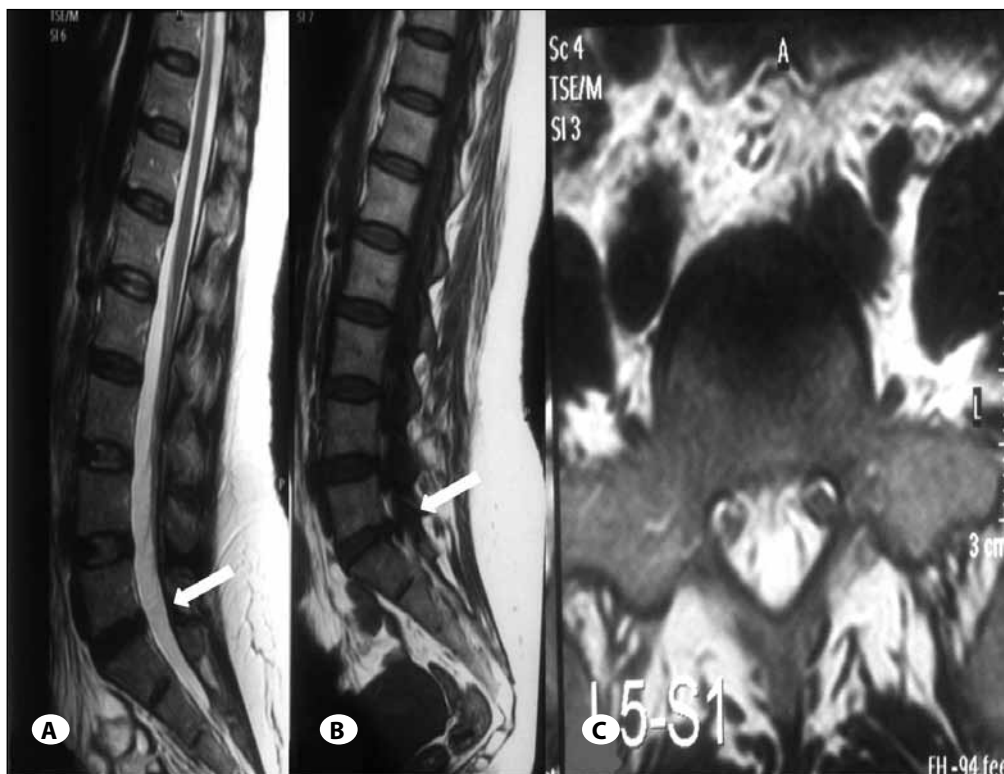

Figure 1: A) T2 weighted sagittal, B) T1 weighted sagittal, C) T2 weighted axial MR images show L5-S1 disc bulging (December 2008).

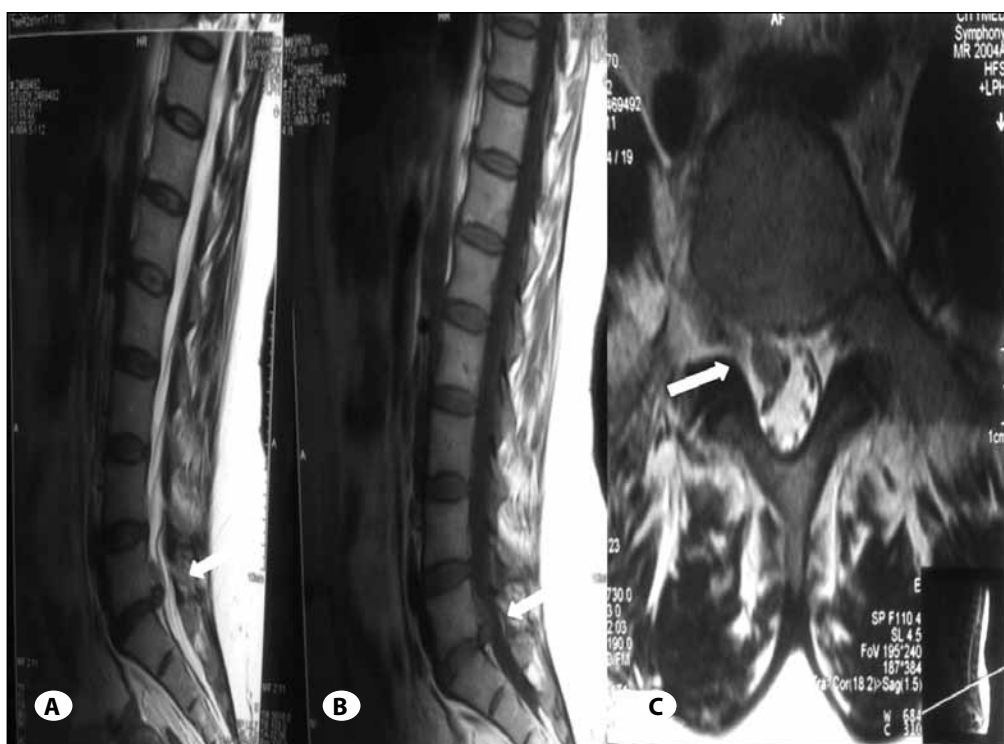


Figure 2: A) T2 weighted sagittal, B) T1 weighted sagittal, C) T2 weighted axial MR images show right sided extruded lumbar disc herniation at L5-S1 level (February 2011).

months under a dietitian's supervision. Her pain decreased during the first month, and disappeared at approximately 6 months. However, her low back pain recurred, and in July 2012 and she came back to neurosurgery clinic. The neurologic examination showed pain at the lumbar region on palpation, negative straight leg raise test, an absence of hypoesthesia, and normal deep tendon reflexes. On control serial MR images, we demonstrated that the extruded disc at the L5-S1 level had totally disappeared. There were only minimal bulgings at the L4-5 and L5-S1 levels (Figure 3A-C).

DISCUSSION

The introduction of MRI has provided more detailed information about disc herniations and their natural history. Clinical improvement frequently correlates with radiographic disc regression. However, a longitudinal study of nonsurgically managed patients with documented disc herniations did not show a direct relationship between clinical and radiographic improvement (27). It appears, therefore, that symptomatic improvement may occur without significant morphological changes, or that such clinical improvement precedes the radiographic changes. This discrepancy may be explained by the progressive decrease of pressure exerted by herniated fragments on neighboring neural structures and the gradual improvement of the inflammatory response that accompanies the herniation.

Obesity is a potential risk factor for intervertebral disc disease (7). Buckwalter et al. (2) stated that obesity with hypertension and diabetes could affect pathophysiology of ligament and

tendon diseases, which could also cause low back pain. Simpson et al. (26) reported good to excellent results in 39% of patients with diabetes, and in 95% of patients without diabetes: this was seen in cases in which (an initial) discectomy was performed before the final operation. Negative outcomes were reported, as well as higher recurrence rates in diabetic patients (22). Mirtz and Greene (20) stated that obese individuals are more prone to back pain. In a study by Magora and Schwartz, obesity was found to significantly increase the prevalence of disc degeneration (16).

Body Mass Index (BMI) is a measure of body fat, and is calculated by dividing the patient's weight in kilograms by height in meters squared (kg/m^2) (25). Obesity is generally defined as a BMI of 30 kg/m^2 and higher (12, 25). On the other hand, being overweight is defined as a BMI of 25 and 30 kg/m^2 (1, 12). Extra weight is more common in men, while obesity is more prevalent in women (25). Our patient's BMI was 33.6 kg/m^2 (86 kg /1.6 m \times 1.6 m), so we defined her as obese. According to one study, when we compare women with a BMI of 30 kg/m^2 or higher, versus a BMI lower than 25 kg/m^2 , those with a higher BMI are 1.5 times more likely to have symptoms of intervertebral disc herniation (15). In another study, it was reported that obese patients with back pain, whose BMIs were greater than 30 kg/m^2 , had no complaints after surgery for the weight (17). Meredith et al. found that obesity is a strong predictor of herniation recurrence after microdiscectomy operation (18).

The mechanism of spontaneous regression or disappearance of disc herniation is not clearly understood at this time.

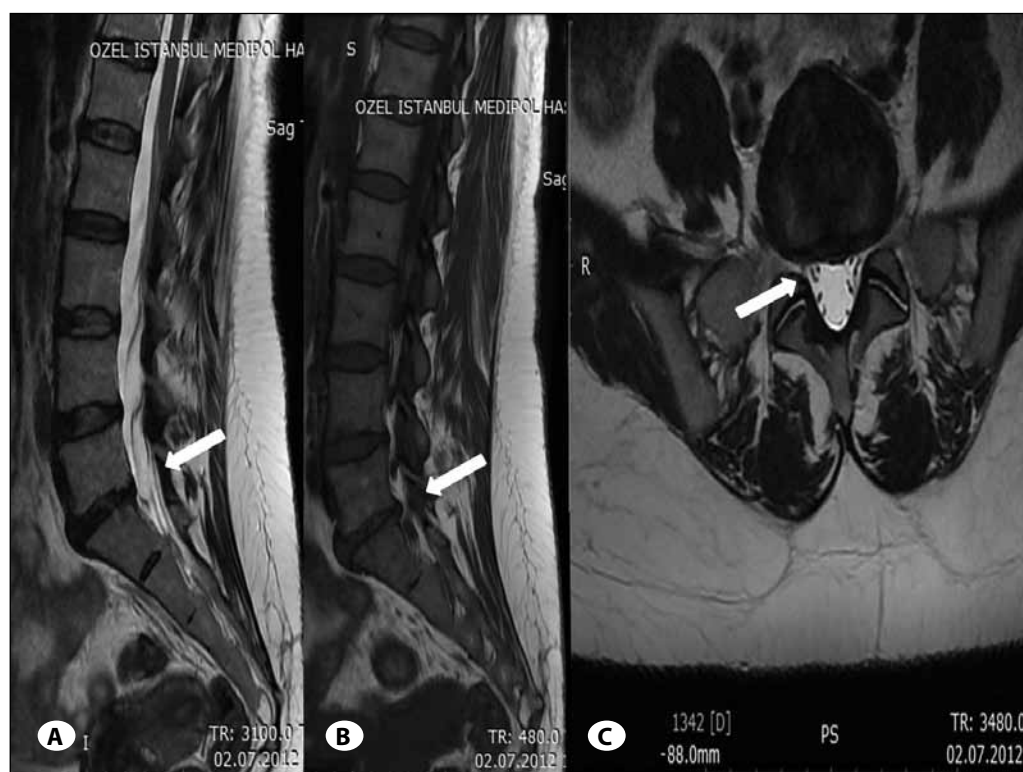


Figure 3: A) T2 weighted sagittal, B) T1 weighted sagittal, C) T2 weighted axial MR images show regression of extruded disc herniation at L5-S1 level (July 2012).

However, researchers have proposed three mechanisms that might play a role in the regression of disc herniation (6, 27, 29). The first one is retraction theory, which speculates that the herniated disc may retract into the intervertebral disc space, but this theoretically occurs when the herniated disc protrudes through the annulus fibrosus without separation (8, 29). The second is dehydration theory, which involves resolution subsequent to gradual dehydration and shrinkage of disc herniation (11, 24, 27). The third is the most popular and studied theory, which involves inflammatory reaction with neovascularization. In this view, herniated disc is recognized as a foreign body by the autoimmune system, which induces an inflammatory reaction leading to infiltration of related cells: these include macrophages, granulocytes, lymphocytes, and neovascularization of cartilage tissue (9, 10, 13). Hirabayashi et al. reported that epidural vessels infiltrate disc material with granulation tissue, causing transformation into scar tissue (11). Burke et al. stated that human intervertebral disc tissue can produce chemokines, MCP-1, and IL-8, which act as chemoattractants for macrophages and capillaries. This may explain the ingrowth of granulation tissue in spontaneous disc herniation resorption (3).

Doita et al. reported that the significantly high levels of endothelial growth factor in the extruded discs, compared to small protruded discs, presumably enhance the proliferation of endothelial cells (4). Henmi et al. showed that large protruded disc herniations, compared to small ones, become much smaller: this was reported because the water content in large herniations, especially in patients less than 40 years of age, is greater than in smaller ones (10).

Studies have shown an increased loss of disc height in the obese individual as the individual transitions from supine to sitting or standing positions relative to normal weight controls, suggesting increased axial loading of the disc during most daily activities (31).

In our case, due to the fact that the disc herniation was a large one, developing after sudden weight gain and undiagnosed diabetes mellitus, a possible mechanism for regression would be dehydration and increased endothelial cell proliferation.

Lumbar disc herniations can be treated conservatively or surgically. If, however, neurological examination involves positive straight leg test, sensory or motor deficit, decrease or disappearance of deep tendon reflexes, urinary or fecal incontinence, excruciating pain that does not respond to medical treatment and rest - then one or more of these conditions, with MRI finding of protruded, extruded, or sequestered disc herniation pressing on the spinal root or cord may necessitate surgery.

Alternatively, we would suggest conservative treatment and possible spontaneous disc regression if there is a large protruded, extruded, or sequestered disc herniation without cauda equina syndrome or progressive motor deficit.

Furthermore, prior to surgery in our case, it may be beneficial to allow for spontaneous regression of disc herniation,

triggered by sudden weight gain; it may also be helpful to direct the patient to a dietitian to decrease the BMI to a normal level, hopefully resulting in decreased recurrence of disc herniation following future surgery.

CONCLUSION

Spontaneous regression (or total disappearance) of intervertebral protruded, extruded, or sequestered disc herniation has frequently been reported. However, we did not find any case report in the literature about spontaneous regression of extruded lumbar disc herniation following weight loss. Thus, we suggest conservative treatment in these cases, at least those without cauda equina syndrome or progressive motor deficit. We also suggest consideration of possible spontaneous disc regression.

REFERENCES

1. Barton JE, Haight RO, Marsland DW, Temple TE Jr: Low back pain in the primary care setting. *J Fam Pract* 3:363-366,1976
2. Buckwalter JA, Woo SL, Goldberg VM, Hadley EC, Booth F, Oegema TR, Eyre DR: Soft-tissue aging and musculoskeletal function. *J Bone Joint Surg Am* 75:1533-1548,1993
3. Burke JG, Watson RW, McCormack D, Dowling FE, Walsh MG, Fitzpatrick JM: Spontaneous production of monocyte chemoattractant protein-1 and interleukin-8 by the human lumbar intervertebral disc. *Spine (Phila Pa 1976)* 27:1402-1407, 2002
4. Doita M, Kanatani T, Ozaki T, Matsui N, Kurosaka M, Yoshiya S: Influence of macrophage infiltration of herniated disc tissue on the production of matrix metalloproteinases leading to disc resorption. *Spine (Phila Pa 1976)* 26:1522-1527, 2001
5. Ellenberg M, Reina N, Ross M, Chodoroff G, Honet JC, Gross N: Regression of herniated nucleus pulposus: Two patients with lumbar radiculopathy. *Arch Phys Med Rehabil* 70:842-844, 1989
6. Fager CA: Observations on spontaneous recovery from intervertebral disc herniation. *Surg Neurol* 42: 282-286, 1994
7. Frymoyer JW: Back pain and sciatica. *N Engl J Med* 318: 291-300, 1988
8. Guinto FC Jr, Hashim H, Stumer M: CT demonstration of disk regression after conservative therapy. *AJNR Am J Neuroradiol* 5: 632-633,1984
9. Haro H, Shinomiya K, Murakami S, Spengler DM: Up-regulated expression of matrix metalloproteinases and neutrophil collagenase in human herniated discs. *J Spinal Disord* 12: 245-249, 1999
10. Henmi T, Sairyo K, Nakano S, Kanematsu Y, Kajikawa T, Katoh S, Goel VK: Natural history of extruded lumbar intervertebral disc herniation. *J Med Invest* 49: 40-43, 2002
11. Hirabayashi S, Kumano K, Tsuiki T, Eguchi M, Ikeda S: A dorsally displaced free fragment of lumbar disc herniation and its interesting histologic findings. A case report. *Spine (Phila Pa 1976)* 15:1231-1233,1990
12. Hodge AM, Zimmet PZ: The epidemiology of obesity. *Baillieres Clin Endocrinol Metab* 8: 577-599, 1994

13. Komori H, Shinomiya K, Nakai O, Yamaura I, Takeda S, Furuya K: The natural history of herniated nucleus pulposus with radiculopathy. *Spine (Phila Pa 1976)* 21:225-229, 1996
14. Krieger AJ, Maniker AH: MRI-documented regression of a herniated cervical nucleus pulposus: A case report. *Surg Neurol* 37: 457-459, 1992
15. Lean ME, Han TS, Seidell JC: Impairment of health and quality of life using new US federal guidelines for the identification of obesity. *Arch Intern Med* 159: 837-843, 1999
16. Magora A, Schwartz A: Relation between the low back pain syndrome and x-ray findings. I: Degenerative osteoarthritis. *Scand J Rehabil Med* 8: 115-125, 1976
17. Melissas J, Volakakis E, Hadjipavlou A: Low-back pain in morbidly obese patients and the effect of weight loss following surgery. *Obes Surg* 13: 389-393, 2003
18. Meredith DS, Huang RC, Nguyen J, Lyman S: Obesity increases the risk of recurrent herniated nucleus pulposus after lumbar microdiscectomy. *Spine J* 10: 575-580, 2010
19. Miller S, Casden AM: Spontaneous regression of a herniated disk. A case report with a four year follow-up. *Bull Hosp Jt Dis* 57: 99-101, 1998
20. Mirtz TA, Greene L: Is obesity a risk factor for low back pain? An example of using the evidence to answer a clinical question. *Chiropr Osteopat* 13: 2, 2005
21. Mixer WJ, Barr JS: Rupture of the intervertebral disc with involvement of the spinal cord. *New Engl J Med* 211: 210-215, 1934
22. Mobbs RJ, Newcombe RL, Chandran KN: Lumbar discectomy and the diabetic patient: Incidence and outcome. *J Clin Neurosci* 8: 10-13, 2001
23. Ryu SJ, Kim IS: Spontaneous regression of a large lumbar disc extrusion. *J Korean Neurosurg Soc* 48: 285-287, 2010
24. Saal JA: Natural history and nonoperative treatment of lumbar disc herniation. *Spine (Phila Pa 1976)* 21: 2S-9S, 1996
25. Seidell JC, Flegal KM: Assessing obesity: Classification and epidemiology. *Br Med Bull* 53: 238-252, 1997
26. Simpson JM, Silveri CP, Balderston RA, Simeone FA, An HS: The results of operations on the lumbar spine in patients who have diabetes mellitus. *J Bone Joint Surg Am* 75: 1823-1829, 1993
27. Slavin KV, Raja A, Thornton J, Wagner FC: Spontaneous regression of a large lumbar disc herniation: Report of an illustrative case. *Surg Neurol* 56:333-336; discussion 337, 1997
28. Song JH, Park HK, Shin KM: Spontaneous regression of a herniated cervical disc in a patient with myelopathy. Case report. *J Neurosurg* 90: 138-140, 1999
29. Teplick JG, Haskin ME: Spontaneous regression of herniated nucleus pulposus. *AJR Am J Roentgenol* 145: 371-375, 1985
30. Westmark RM, Westmark KD, Sonntag VK: Disappearing cervical disc. Case report. *J Neurosurg* 86: 289-290, 1997
31. Yar T: Spinal shrinkage as a measure of spinal loading in male Saudi university students and its relationship with body mass index. *Saudi Med J* 29:1453-1457, 2008