

Intravascular Leiomyomatosis of the Uterus: A Report of Two Cases

Bahar ÇAĞLAR¹, Sema OVALI¹, Gözde KIR²

Istanbul, Turkey

Two cases of intravascular leiomyomatosis (IVL) of the uterus, a rare benign smooth-muscle tumor, are described. A preoperative diagnosis of IVL was not introduced in the patients, both of which presented with a pelvic mass with the presumptive diagnosis of leiomyoma. Surgical exploration confirmed the presence of uterine mass and none of the cases showed extra-uterine extension. Histological examination demonstrated a fascicular pattern of bland spindle-shaped smooth-muscle cells, which extended to veins inside the myometrium. The present diagnosis was confirmed by immunohistochemical stain for desmin and CD 34. Despite their histological benignity, these lesions have tendency to metastasize and are closely related to the conditions called 'benign metastasizing leiomyoma' and 'intracaval mass and cardiac extension'. The primary treatment of IVL is hysterectomy and excision of any extrauterine tumor, when technically feasible. Anti-estrogenic therapy has been suggested as potentially useful in controlling of unresectable tumor. Regarding recent data, the follow-up must be long and periodic postoperative ultrasonic or magnetic resonance imaging studies may be useful in detecting growth of residual intravascular tumor.

Key Words: Benign tumor, Hysterectomy, Intravascular leiomyomatosis

Gynecol Obstet Reprod Med; 2011;17:119-122

Introduction

Intravascular leiomyomatosis (IVL) is a rare benign smooth-muscle tumor that is defined as an extension of grossly visible smooth muscle into vascular spaces or growth of microscopic tongues of benign smooth muscle cells into vessels beyond the confines of a leiomyoma.^{1,2}

The lesion was first described by Birch and Hirschfield³ in 1896. According to Clement and Mullings^{4,5} IVL has been described in women 23 to 80 years of age, with most patients described middle-aged.⁶⁻⁷ There has been no demonstrable association with race, fertility or parity.⁷ The symptoms and signs of IVL are like those of ordinary leiomyoma.

The correct preoperative diagnosis of IVL seems to be difficult. It is usually established by intraoperative findings or postoperative pathological examination. According to Clement⁷ IVL is more common than the number of reported

cases suggest, because in an unknown proportion the diagnosis is overlooked by the pathologist. The presence of typical leiomyomas, which coexist in most cases of IVL, may divert attention from the intravascular tumor, mainly in cases in which no extrauterine extension is noted.

Despite its cytohistological benignity, IVL has metastatic potential because of vascular invasion.⁵ Most of the tumors arise in the uterus and grow into the lumen of uterine veins, but some may extend through the pelvic or ovarian veins into the inferior vena cava and reach the right side of the heart.⁵ Rarely, the patient's initial symptoms are related to the cardiac involvement; congestive heart failure, dyspnea and syncope.^{5,8-9} The present case report describes two patients with postoperative pathological diagnosis of IVL.

Case 1

G.İ, 30 years old female, P1; was treated for symptoms of pelvic pain, hyperpolymenorrhea for 4 months. Physical examination indicated an oversize uterus with a nodular image which was confirmed by ultrasonography (LOGIQ 200®, GE Healthcare, UK) and magnetic resonance (MRI) (Philips Intera 1.5 T®, Oshkosh Speciality Vehicles, Camberley, UK). In the MRI, a round nodular lesion located in uterine corpus having anteroposterior diameter of 9 cm and transverse diameter of 8.5 cm. In T2W2 segments the hyperintense lesion had a hypointense wall formation surrounding an amorphous hypointense area. Also on the upper part of the lesion there were tubular and tortuous signal-void structures resembling to ves-

¹Department of Obstetrics and Gynecology Medical School Medipol University, İstanbul

²Department chief of Pathology Ümraniye Educational Hospital, İstanbul

Address of Correspondence: Bahar Çağlar
Obstetrics and Gynecology Department,
Medipol University Medical School,
Kadıköy, İstanbul
caglares@yahoo.com

Submitted for Publication: 20.04.2010

Accepted for Publication: 25.10.2010

sels. Postcontrast T2W2 showed thin rim enhancement patterns on the peripheral and central areas of the lesion. The endometrium could not be distinguished from the lesion. The other visible organs and large vessels were normal. Probe curettage was performed and the result was secretory endometrium.

A myomectomy operation was performed. During the operation, the suspected myoma observed to be deenerated and hard to be seperated from the myometrium. After the myomectomy, an intrauterine device was introduced since the lesion was very close to the lining of endometrium during the operation. The ovaries and other organs looked normal.

Regarding macroscopic examination, the tissue had irregular contours with compact whitish nodules and vessel like structure. Tongues of muscular tissue were observed in venules of myometrium. There were focal areas of infiltration at the periphery with low mitotic rates, without atypias. At the immunohistochemical examination it was desmin, cd34, ER, PR positive while CD10 was negatife. (Figure 1) The diagnosis was intravascular leiomyomatosis. Noting the female patient, having one child seeking for the second, the operation was designed as myomectomy outdating future pathology expectations. During the 6-month-follow up after surgery the patient did not present any recurrence. Chest X-rays and pelvic MRI showed no organ involvement. (Figure 3) A second pregnancy and then following the labour hysterectomy operation was offered.

Case 2

N.G, 47 years old female, G3P2Ect1; was treated for hyperpolymenorrhea and dysmenorrhea for one year. Physical examination indicated an oversize uterus with heterogeneous texture, presenting various hypoechoid nodular images. The widest size of the nodular images was calculated as 56x47 mm and 31x41 mm. The images were suspected as deenerated intramural myomas. A total hysterectomy and bilateral salpingoophorectomy was performed. During the operation the myoma like nodules were very soft and fragile.

On macroscopic examination there were multible myomas. On the istmic portion of the uterus, there was an intravascular worm-like extension and growth. Microscopically tongues of muscular tissue were observed in venules of myometrium outside the limits of the myomas. Immunohistochemically the lesion was ER, PR and CD 34 positive. (Figure 2) The diagnosis was multiple intramural leiomyomas and intravascular leiomyomatosis with 10% percent of intravascular pattern and 90% of extrauterine pattern. The patient has been followed for 6 months after the surgery without recurrences.

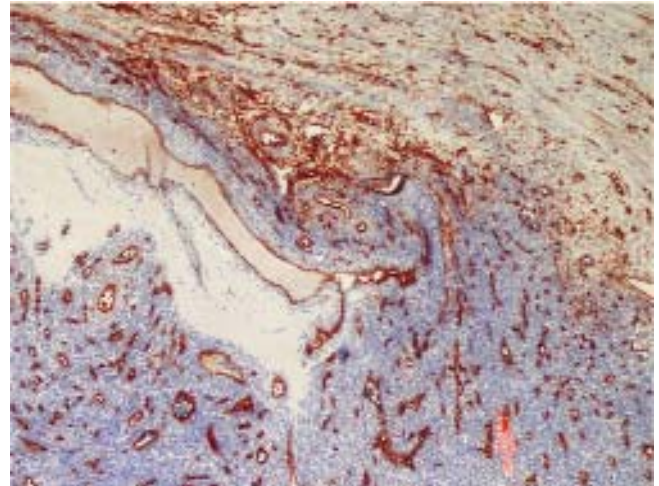


Figure 1: Vessel-rich histomorphology of leiomyoma component in the case of intravascular leiomyomatosis (X40 CD 34 positive)

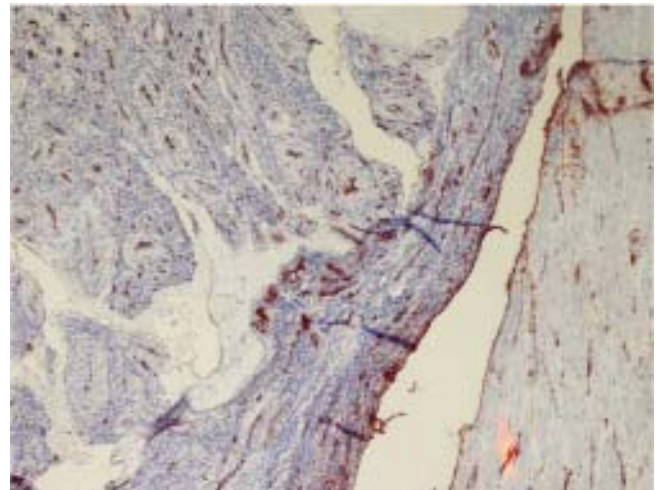


Figure 2: Proliferation in endothelium covered vascular structures (X40 CD 34 positive)

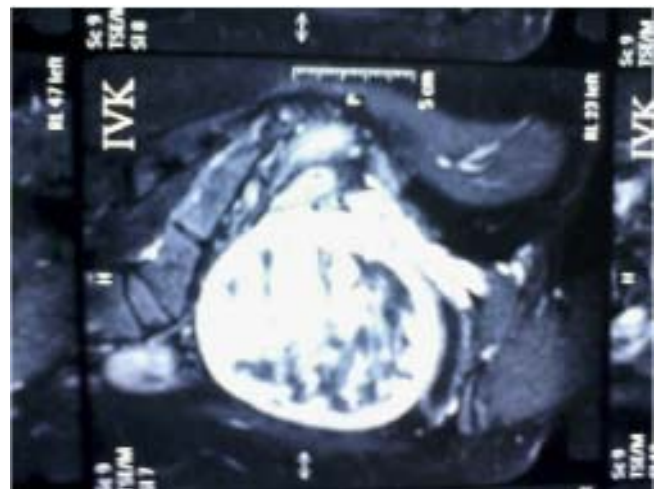


Figure 3: MR view showing no organ involvement.

Discussion

Intravascular leiomyoma is a rare smooth muscle tumor arising from either the wall of a uterine vessel or from a uterine leiomyoma.⁹⁻¹⁰ The aetiology of IVL has been debated; it appears to either represent intravascular extension of uterine leiomyoma or is derived from smooth muscle cells in the vein's medial layer.^{2,5,11-12} Its extrauterine extension, particularly within veins of the broad ligament, has been recently reported and in 10 to 40 % of these cases the tumor had reached the right side of the heart.^{2,12} Extrauterine extension may be diagnosed intraoperatively or on gross examination of the hysterectomy specimen. In other cases it only becomes evident on revision many years after hysterectomy, because of recurrent tumor in the pelvis. It is sometimes associated with solitary metastases, as in benign metastasizing leiomyoma. The diagnostic gross feature is the presence of one or more nodules or wormlike extensions of tumor within myometrial or parametrial vessels. Leiomyomas are often present, but occasionally all tumor is intravascular, without a gross nodule.⁵ In the present case report, both cases were diagnosed only by pathological examination, none of them had extrauterine extension to the ovarian veins.

Microscopically, IVL is characterized by endothelium-coated plugs of benign smooth muscle cells within myometrial vessels or lymphatics.¹³ The intravascular tumor resembles atypical leiomyoma or it may be a leiomyoma variant, such as cellular, atypical, epithelioid, etc.⁹ The immunohistochemical stains have a value on the differential diagnosis, desmin is more frequent in the smooth muscle cell, while CD 34 is used for intravascular involvement. Both of the present cases were desmin and CD 34 positive. They were also grossly recognizable indicating that IVL is probably under diagnosed, due to failure to appreciate the early stages of tumor development or inadequate sampling of all uterine leiomyomas.

The treatment of IVL is basically surgical. There is general agreement that hysterectomy and resection of all extrauterine masses should be performed.⁵ Even for pelvic, abdominal vessels and cardiac involvement, surgical tumor resection has been reported as successful.¹³⁻¹⁶ It was also proposed that bilateral oophorectomy could help avoid growth of tumoral tissue stimulated by estrogenic action.¹⁷ Anti-estrogenic drugs (such as tamoxifen), danazol and gestrinone; GnRh agonist and progesterone have been used for inoperable tumors.¹³ Radiation and chemotherapy have also been used for metastatic disease.² In the present cases, hysterectomy and bilateral oophorectomy was done for case 2 and hysterectomy was planned for case 1.

For the followup, patients should be submitted to ultrasonic and magnetic resonance examination every 6 month intervals.¹⁷ In case any abnormality is noticed in pelvic or ab-

dominal vessels; computer tomography of thorax and echocardiography, is indicated to investigate cardiac involvement.²

In conclusion, Intravascular leiomyomatosis is a rare benign smooth-muscle tumor which has metastatic potential because of vascular invasion. The diagnostic gross feature is the presence of one or more nodules or wormlike extensions of tumor within myometrial or parametrial vessels. It is important to recognize IVL and follow up of the patients regularly.

Uterusta İnvtravascular Leiomyomatosis; İki Olgu Raporu

Uterusta Intravascular leiomyomatosis (IVL) nadir görülen selim düz kas tümörleri olarak tanımlanmaktadır. Rapor edilen olgularda IVL'nin preoperatif tanısı daha önce tanımlanmamış, ve her ikisi de leiomyoma teşhisi ile örtüşen pelvik kitle ile başvurmuştur. Her iki vakada ekstrauterin yayılma görülmemekle birlikte cerrahi tarama sonucunda uterin kitlelerin varlığı doğrulanmıştır. Histolojik incelemede myometrium içerisindeki venalara uzanan, fasküler patern gösteren ince iç şekilli düz kas hücreleri tesbit edilmiştir. İmmünohistokimyasal yolla desmin ve CD34 boyama yöntemleri ile tanı konmuştur. Histolojik olarak selim karakterde olmalarına rağmen, bu lezyonlar metastaza yatkınlık göstermekte ve 'selim metastazik leiomyoma' ya da 'intrakaval kitle ve kardiak yayılımı' adını almaktadırlar. IVL'de primer tedavi yaklaşımı histerektomi ve ekstrauterin yayılım gösteren kitlelerin tümünün uzaklaştırılmasıdır. Anti-östrojenik tedavi ulaşılamayan kitlelerin kontrolü için potansiyel ajanları içermektedir. Kontrolleri uzun süreli olan IVL'de, periyodik postoperatif ultrasonik ve manyetik rezonans takipleri rezidüel intravasküler tümörlerin erken tanısında önem kazanmaktadır.

Anahtar Kelimeler: Histerektomi, Intravascular, Leiomyomatosis, Selim tümör

References

1. Clement PB. Intravenous leiomyomatosis of the uterus. *Pathol Annu* 1988;23:153-83.
2. Mulvany NJ, Slavin JL, Ostör AG, Fortune DW. Intravenous leiomyomatosis of the uterus: a clinicopathologic study of 22 cases. *Int J Gynecol Pathol* 1994;13:1-9.
3. Birch-Hirschfeld FV. *Lherbuch der pathologischen anatomie*. Leipzig, Germany: Vogel 1896.
4. Mullings AM, Char G, Martin MP, Frederick J, Walton N, Pickering K. Intravenous leiomyomatosis with massive ascites. *Int J Gynaecol Obstet* 1992;37:285-8.
5. Bianchini E, Pezzica E, Crescini C, Micoli G. Intravenous leiomyomatosis. Presentation of 5 cases and a review of the literature. *Pathologica* 1989; 81:151-62.
6. Clement PB, Young RH, Scully RE. Diffuse, perinodular, and other patterns of hydropic degeneration within and ad-

- jacent to uterine leiomyomas. Problems in differential diagnosis. *Am J Surg Pathol* 1992;16:26-32.
7. Lee VS, Thompson NW, Cho KJ, Goldblum JR. High-output cardiac failure: an unusual manifestation of intravenous leiomyomatosis. *Surgery* 1993;113:466-70.
 8. Marcus SG, Krauss T, Freedberg RS, Culliford AT, Weinreich DJ, Kronzon I. Pulmonary embolectomy for intravenous uterine leiomyomatosis. *Am Heart J* 1994; 127:1642-5.
 9. Clement PB. Pure mesenchymal tumors in: Tumors and tumor like lesions of the uterine corpus and cervix (Eds: Clement PB and Young RH) Churchill Livingstone Inc. New York 1993; pp.285-328.
 10. Hormann K. Ueber einen fall von myomatoseum uterus-tumor. *Zentrabl Gynaekol* 1907;51:1604-5.
 11. Marshall JF, Morris DS. Intravenous leiomyomatosis of the uterus and pelvis: case report. *Ann Surg* 1959;149:126-34.
 12. Nam MS, Jeon MJ, Kim YT, Kim JW, Park KH, Hong YS. Pelvic leiomyomatosis with intracaval and intracardiac extension: a case report and review of the literature. *Gynecol Oncol* 2003;89:175-80.
 13. Butler MW, Sanders A. Obstructive shock in a 47 year old female with a deep venous thrombosis due to intravascular leiomyomatosis: a case report. *Cases J* 2009;22:8159.
 14. Kurman RJ ed. Blaustein's Pathology of the Female Genital Tract, 4th ed, Springer-Verlag, New York, 1994.
 15. Norris HJ, Parmley T. Mesenchymal tumors of the uterus. V. Intravenous leiomyomatosis. A clinical and pathologic study of 14 cases. *Cancer* 1975; 36:2164-78.
 16. Rotter AJ, Lundell CJ. MR of intravenous leiomyomatosis of the uterus extending into the inferior vena cava. *J Comput Assist Tomogr* 1991 ;15:690-3.
 17. To WW, Ngan HY, Collins RJ. Intravenous leiomyomatosis with intracardiac involvement. *Int J Gynaecol Obstet* 1993;42:37-40.