

Case Report

Abdominal wall endometriosis: a case report and review of literature

Kshitij Manerikar*, Gurjit Singh, Rishikesh Kore, Mackson Nongmaithem

Department of General Surgery, Dr. D. Y. Patil Medical College Hospital and Research Centre, Pimpri, Pune, Maharashtra, India

Received: 11 February 2016

Accepted: 17 March 2016

***Correspondence:**

Dr. Kshitij Manerikar,

E-mail: drkshitijmanerikar@gmail.com

Copyright: © the author(s), publisher and licensee Medip Academy. This is an open-access article distributed under the terms of the Creative Commons Attribution Non-Commercial License, which permits unrestricted non-commercial use, distribution, and reproduction in any medium, provided the original work is properly cited.

ABSTRACT

Spontaneous abdominal wall endometriosis or scar endometriosis is rare clinical entity and often misdiagnosed. Patients can present with painful lump or nodule over abdominal wall which can be adjacent to previous scar or at independent location. Symptoms can be associated with cyclic menstruation or without any relation to it. Different available modalities for diagnosis are Fine needle aspiration cytology and biopsy, ultrasonography of abdomen and pelvis, computed tomography and magnetic resonance image. Most accepted treatment modality is surgical excision. Aim of this case report is to highlight the diagnostic dilemma present in this clinical entity. In our case 24 year old female presented with painful nodule in right iliac fossa. Excision of nodule was performed and specimen was sent for Histopathological examination, which revealed the diagnosis of abdominal wall endometriosis.

Keywords: Surgery, Abdominal wall, Caesarean section, Endometriosis, Endometrium, Muscle, Stromal cells

INTRODUCTION

Growth of endometrial tissue outside uterine cavity is called as 'Endometriosis', which was described first by Rokitansky.¹ Pelvis is the most common location for endometriosis although extra pelvic endometriosis involving bladder, kidney, bowel, omentum, lymph node, lungs, pleura, extremities, umbilicus, hernial sacs and abdominal wall has also been noted.² Incisional or Scar endometriosis is rare and has prevalence of 1.6%.³

Spontaneous abdominal wall endometriosis as well as scar endometriosis is usually misdiagnosed in both gynecology and general surgery. Such cases are poorly documented in literature. We report a case of young woman with abdominal wall endometriosis, 4 years post caesarean section.

CASE REPORT

A 24 year old female (G2P1) came with complaints of painful nodule of 2 months duration in right iliac fossa. Nodule was associated with persistent dull aching pain

without any to menstrual cycle. Patient did not give any history of increase in size of nodule during menstruation. Patient was healthy otherwise without any significant past medical history. She had undergone uncomplicated caesarean section and dilatation and curettage 4 years and 2 years ago respectively.

Physical examination revealed 12 cm long healthy pfannensteil scar. There was a well-defined, 3x2 cm, firm and fixed nodule in anterior abdominal wall of right iliac region. Nodule was present 5 cm from the right lateral end of the scar (Figure 1). A clinical diagnosis of Desmoid tumor, Endometriosis, Neuroma was made preliminarily.

Ultrasound of abdomen and pelvis was performed, which showed well defined oval shaped, hypoechoic, 4x3 cm lesion in the anterior abdominal wall of right iliac fossa. Lesion was placed in the subcutaneous plane without any internal vascularity or any calcification. There was no connection between scar and lesion. Uterus was normal in size with endometrial thickness of 5 mm. Mass was reported as Benign soft tissue lesion.

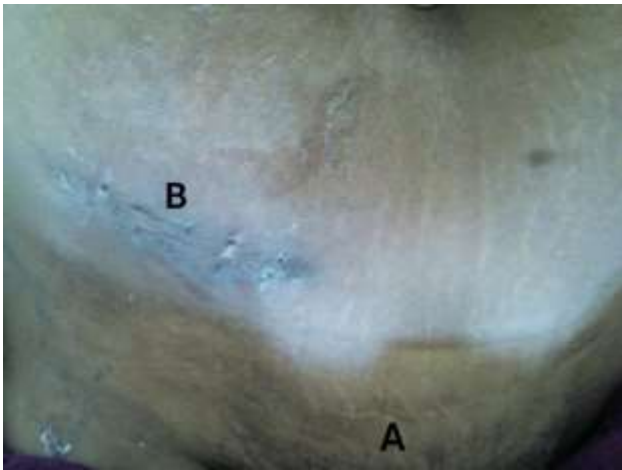

Figure:1 A: Pfannensteil scar of previous caesarean section; B: gridiron scar for excision of nodule.

Fine needle aspiration cytology of nodule revealed mature adipose tissue without any specific pathology and suggested diagnosis was Benign lesion possibly Lipoma.

Through an oblique incision of 5 cm in right iliac fossa nodule of size 4 x 3 cm was excised along with 1 cm of surrounding tissue. Nodule was involving skin and subcutaneous tissue and it was located superficial to the external oblique aponeurosis. Intra-operative and post-operative period was uneventful.

Histopathology showed tissue composed of skeletal muscle bundles, smooth muscle bundles, adipose tissues and aggregates of lymphocytes. Endometrial glands and stroma were dispersed in connective tissue in all sections (Figure 2). There was no evidence of any atypia or malignancy. Findings were suggestive of Endometriosis as a diagnosis.

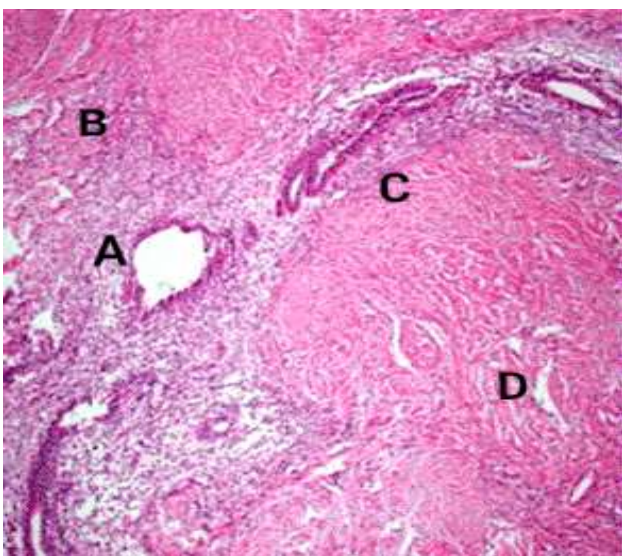


Figure: 2 A: Endometrial gland; B: Endometrial Stroma; C: Smooth muscle, D: Skeletal muscle.

DISCUSSION

Endometriosis is important clinical entity seen in approximately 8-15% of menstruating females, which often produces symptoms such as pelvic pain, dysmenorrhoea and also infertility in some cases.⁴ Scar endometriosis is rare.³ It often presents to surgeon rather than gynaecologist.

Scar endometriosis usually follows previous abdominal or pelvic operations such as caesarean sections, hysterectomies and rarely even following appendicectomies, amniocentesis, episiotomy and surgeries on fallopian tube.⁵ Incidence of endometriosis in a postoperative scar is very low and in most of cases it is noted adjacent to previous surgical scar. In our case it was 5 cm away from adjacent scar.

According to a case report Isolated abdominal wall endometriosis occurs as rarely as up to 4% whereas associated pelvis endometriosis was seen in 26% cases.³ In our case there was no associated pelvic endometriosis.

Scar endometriosis can often be misdiagnosed as stitch granuloma, inguinal hernia, incisional hernia, spigelian hernia, lipoma, organised abscess, desmoids tumor, neuroma, sarcoma, lymphoma and rarely as primary or metastatic cancer.⁶

Duration between onset of symptoms and patient's prior index surgery varies. In our case duration between previous caesarean section and dilatation and curettage and onset of nodule was 4 and 2 years respectively. Exact reason for this difference in duration is still unknown.

Pathophysiology of scar endometriosis remains unclear though there are many suggested theories such as coelomic metaplasia theory, lymphatic or vascular pathway, immune system dysfunction and autoantibody formation, retrograde spread of collections of endometrial cells during menstruation.⁷

Pain gets aggravated during menstruation and even size of lump or nodule can increase. Cyclicity of various symptoms during menstruation is pathognomonic of scar endometriosis though it is not seen characteristically in every case.⁸

Detail clinical history of lump or nodule, it's variation with cyclic menstruation and past surgical and gynaecological history is very important to diagnose scar endometriosis and rule out various other differential diagnosis. In our case nodule was present 5 cm superiolateral to right end of pfannensteil scar. Pain was not related to menstruation although size of nodule remained unaltered throughout the course.

Amongst various diagnostic methods available such as ultrasonographic examination of abdomen and pelvis, computed tomography, magnetic resonance imaging,

Doppler sonography is considered to be gold standard. A different type of imaging procedures helps only in differential diagnosis.

Ultrasonography being cheaper and easily available, is usually first and most commonly used imaging method. On ultrasonography of abdomen, mass may appear hypoechoic and heterogenous with internal echos. In our case it was hypoechoic in appearance. Computed tomography may show mass as circumscribed solid or mixed mass which enhances by contrast and may show haemorrhages. It also gives clearer picture of presence of endometrium anywhere in abdominal and pelvic cavity.

Fine needle aspiration cytology is considered diagnostic in one study.⁹ In our case FNAC did not contribute to establishing ultimate diagnosis.

Histopathological examination of excised lump or nodule is the most useful diagnostic method postoperatively. Endometrial glands, stromal cells and hemosiderin laden macrophages are the classical findings seen in case of scar endometriosis and presence of any two of these three components are used as confirmatory diagnosis.⁹ In our case out of these three components, presence of endometrial glands and stroma in connective tissue were diagnostic finding. Characteristic diagnostic triad may be absent in many cases whereas sometimes hemorrhage, foamy cells and hemosiderin laden macrophages may obscure gland, stroma. In such cases diagnosis is possible only clinically and not histopathologically.¹⁰

Modalities of treatment available for scar endometriosis and spontaneous abdominal wall endometriosis are medical and surgical therapy. Medical therapy combined with oral contraceptives, danazol and gonadotrophin releasing hormones analogues results only in partial recovery and recurrences occurs as soon as treatment stops. In our case we performed complete excision of nodule with 1 cm margin.

CONCLUSION

One should always suspect endometriosis in a young menstruating female presenting with lump or nodule in

anterior abdominal wall specially if patient has undergone caesarean section and surgery involving uterus and its adnexa. This case is reported to create awareness amongst general surgeons regarding its presentation, diagnosis and management.

Funding: No funding sources

Conflict of interest: None declared

Ethical approval: Not required

REFERENCES

1. Kantor WJ, Roberge RJ, Scorza L. Rectus abdominis endometrioma. Am J Emerg Med. 1999;17:675-7.
2. Carpenter SE, Markham SM, Rock JA. Extra pelvic endometriosis. Obstet Gynecol Clin North Am. 1989; 16(1):193-219.
3. Blanco RG, Parithivel VS, Shah AK, Gumbs MA, Schein M, Gerst PH. Abdominal wall endometriosis. Am J Surg. 2003;185:596-8.
4. Patterson GK, Winburg GB. Abdominal wall endometriosis: report of eight cases. Am Surg. 1999;65:36-9.
5. Goel P, Sood SS, Romilla S, Dalal A. Cesarean section endometriosis- report of two cases. Indian J Med Sci. 2005;59:495-8.
6. Khalifa A. Endometriosis at Caesarian Section Scar. OMJ. 2009;24:294-5.
7. Sax HC, Seydel AS, Sickel JZ, Warner ED. Extrapelvic endometriosis: diagnosis and treatment. Am J Surg. 1996;171:239-41.
8. Gajjar KB, Mahendru AA, Khaled MA. Caesarean scar endometriosis presenting as an acute abdomen: a case report and review literature. Arch Gynecol Obstet. 2008;277:167-9.
9. Pathan S, Kapila K, Haji B, Mallik MK, Al-Ansary TA, George SS, et al. Cytomorphological spectrum in scar endometriosis: a study of eight cases. Cytopathology. 2005;16(2):94-9.
10. Danielpour P, Layke J, Durie N. Scar endometriosis- a rare cause for painful scar: a case report and review of the literature. Can J Plast Surg. 2010;18(1):19-20.

Cite this article as: Manerikar K, Singh G, Kore R, Nongmaithem M. Abdominal wall endometriosis: a case report and review of literature. Int Surg J 2016;3:995-7.